

DEVELOPMENTAL DYSPLASIA OF THE HIP (DDH)

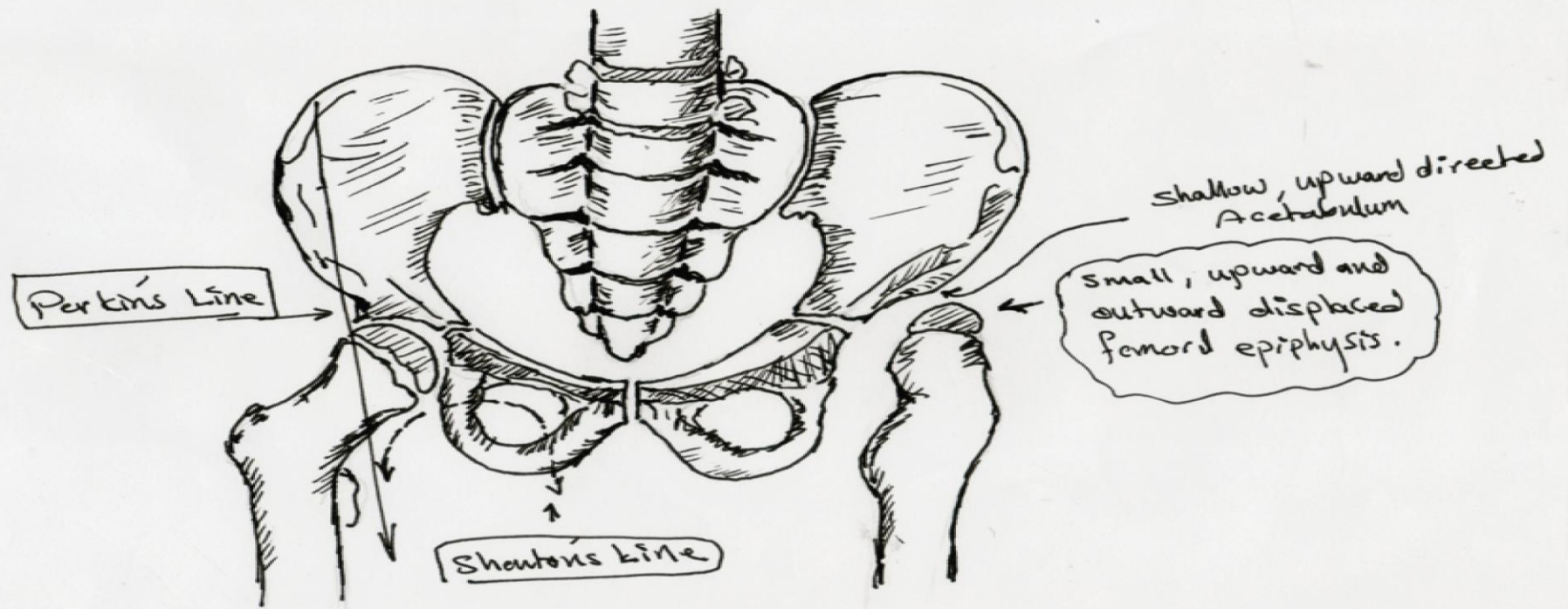
Edited By :-

Zyad Mohamed Alayash

5th stage medical college of mosul

Supervised by:-

Dr.Hadeel Mohamed Luqman



Tushar
11-3-2013.

* Developmental Dysplasia of
The Left hip Joint.

Developmental dysplasia of the hip :

(DDH) results from an abnormal relationship of the femoral head to the acetabulum. It usually occurs from ligamentous laxity and / or abnormal position in utero (therefore is more common with [oligohydramniotic](#) pregnancies).

Incidence :

- The reported incidence varies between 1.5 and 20 per 1000 births , with the majority (60 - 80%) of abnormal hips resolving spontaneously within 2 - 8 weeks (so called immature hip).

Clinical presentation :

- 1- *DDH* is usually suspected in the early neonatal period due to the widespread adoption of clinical examination (e.g Galeazzi sign).
- 2- The diagnosis is then (up to 3 mo.) usually confirmed with ultrasound, although the role of ultrasound in screening is controversial .
- 3- from 3 months outward the Dx by X-ray of pelvis .

Risk factors include :

- 1- female gender (M:F ratio \sim 1:7.5).
- 2- family history.
- 3- breech presentation.
- 4- oligohydraminos.


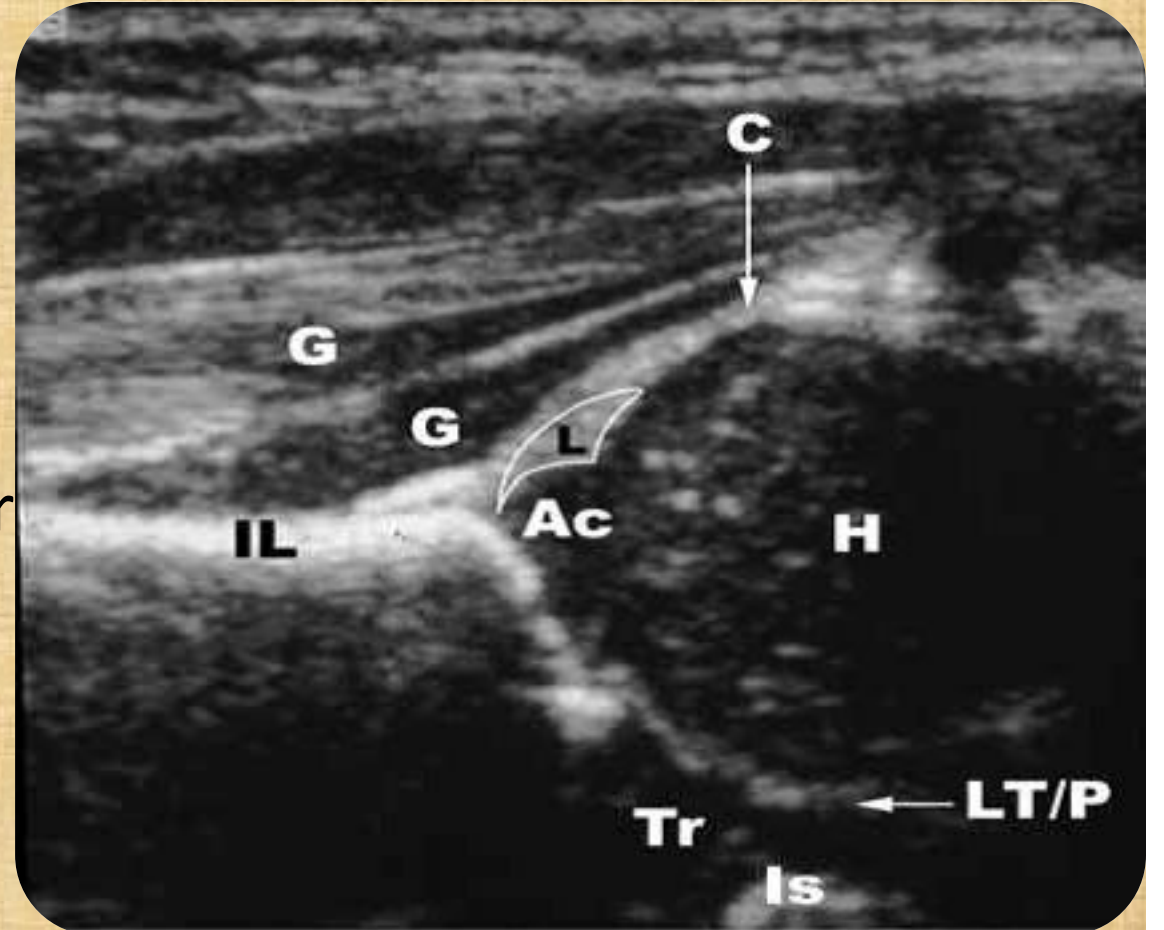
Radiological features :

- **1- Ultrasound :**

- Ultrasound is the test of choice in the infant (< 6 months) as the proximal femoral epiphysis has not yet significantly ossified. Additionally it has the advantage of being a real time dynamic examination allowing the stability of the hip to be assessed with stress views.
- A number of values are used to 'objectively' assess morphology

α -Alpha Angle :

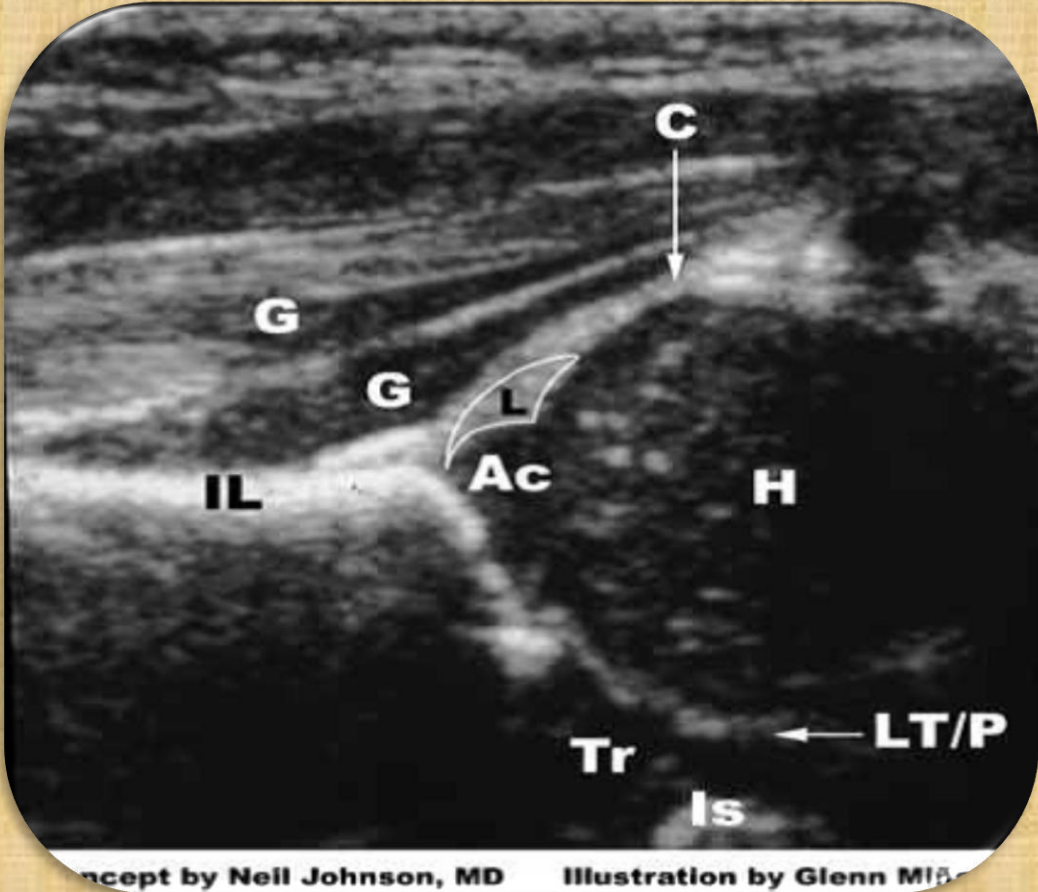
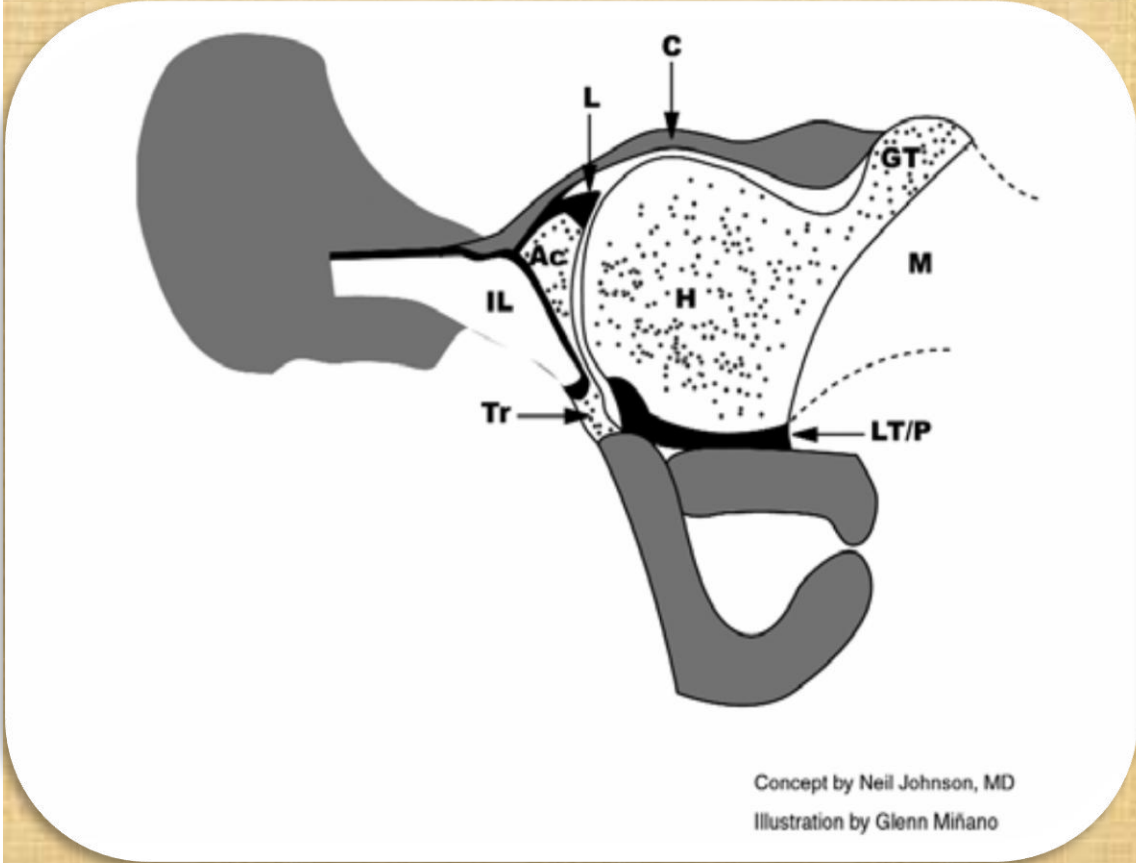
- Angle formed by the acetabular roof to the vertical cortex of the ilium. The normal value is greater than or equal to **60** degrees



b- Beta Angle :

- *Angle* formed between the vertical cortex of the ilium and the
- triangular labral fibrocartilage
- (echogenic triangle).
- The normal value is less than
- **75** degrees, but is only useful in
- assessing immature hips when
- combined with the alpha angle

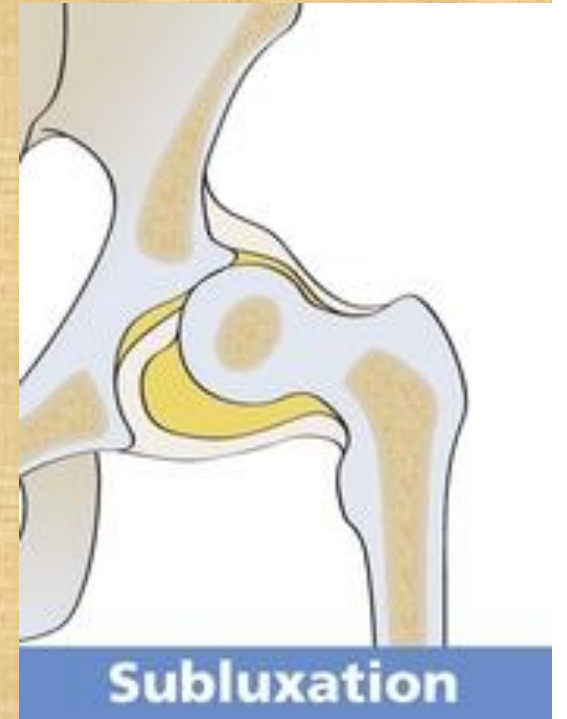coronal ultrasound and anatomic images



- in addition to *alpha* and *beta* angles the diagnosis can be established by measuring the space between the head of femur and the acetabulum..

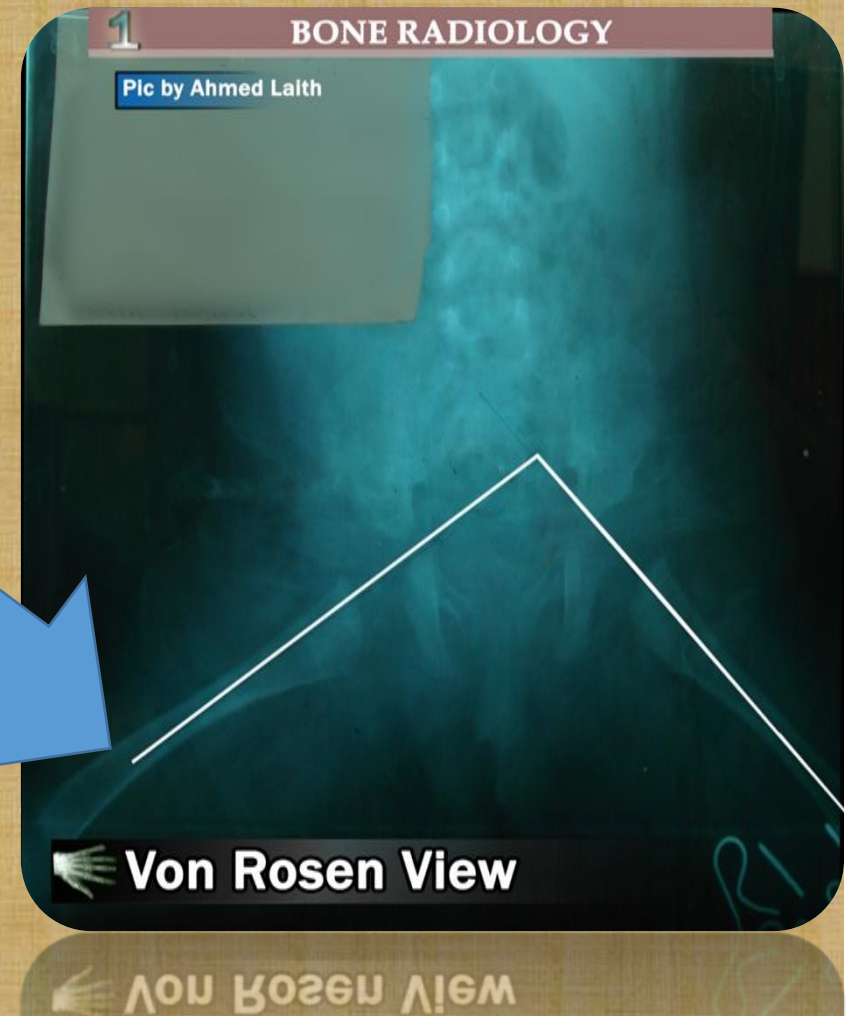
if it (3 _ 5 mm).. **Subluxation**

more than 5 mm..**dislocation**

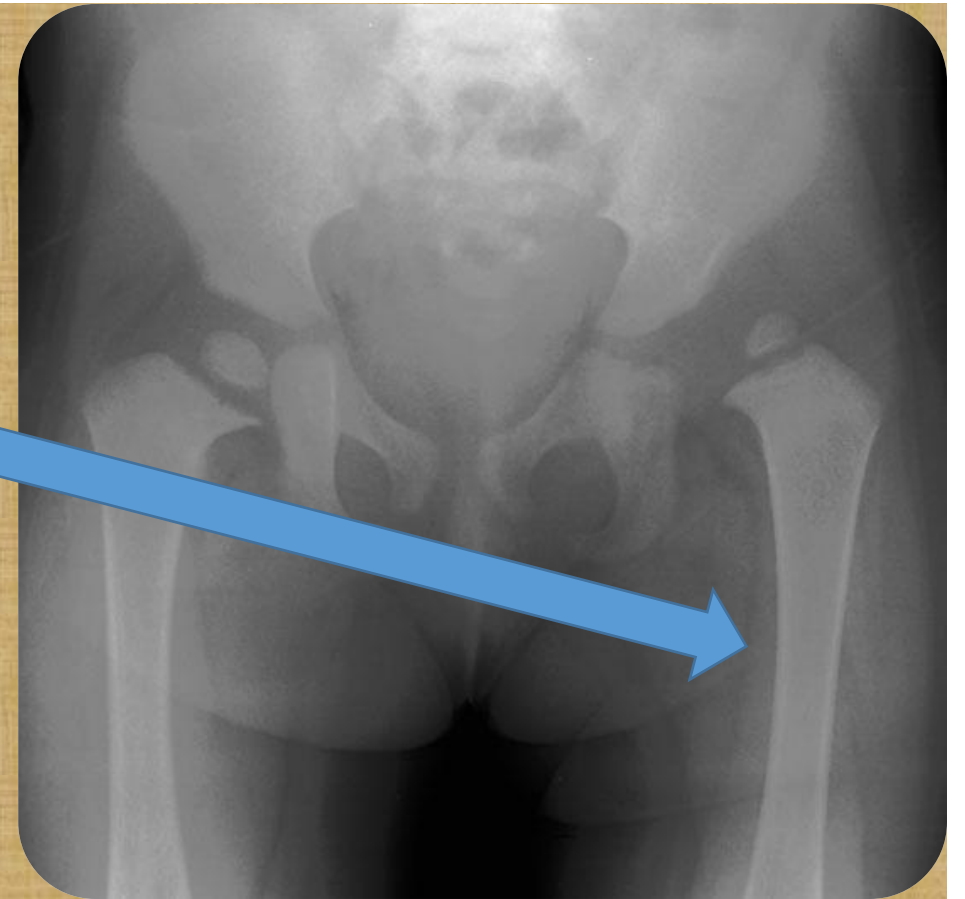


2- **X-Ray:**

- **1** – At age of 3-6 months is by X-ray
- of the pelvis using Von-Rosen view.
- In which the lines drawn across
- both femora will meet at level below
- the lumbo-sacral region in case of DDh



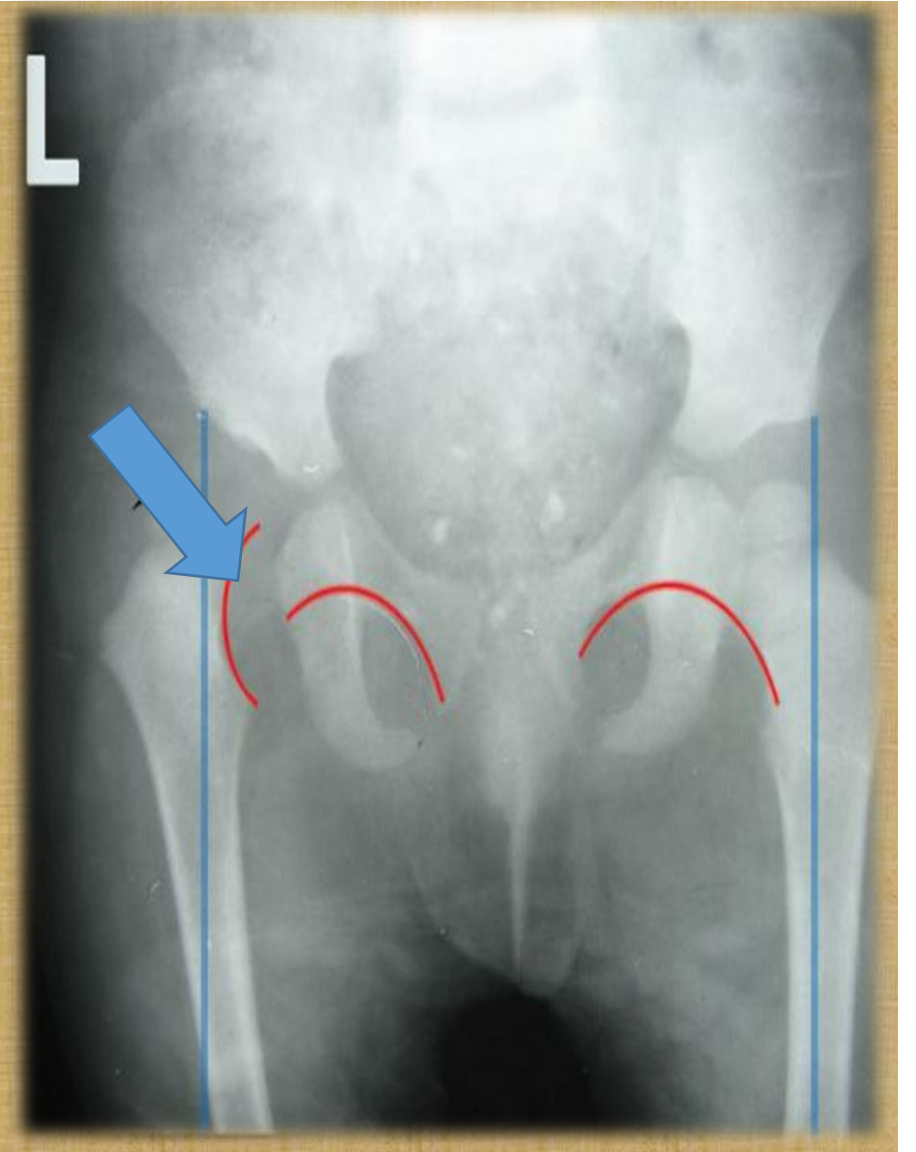
- **2** – after 6 months :
- Antero posterior view of pelvic
- film will show the following :
- a- the femoral epiphysis is displaced
- upward and outward, small and
- more dense than normal one



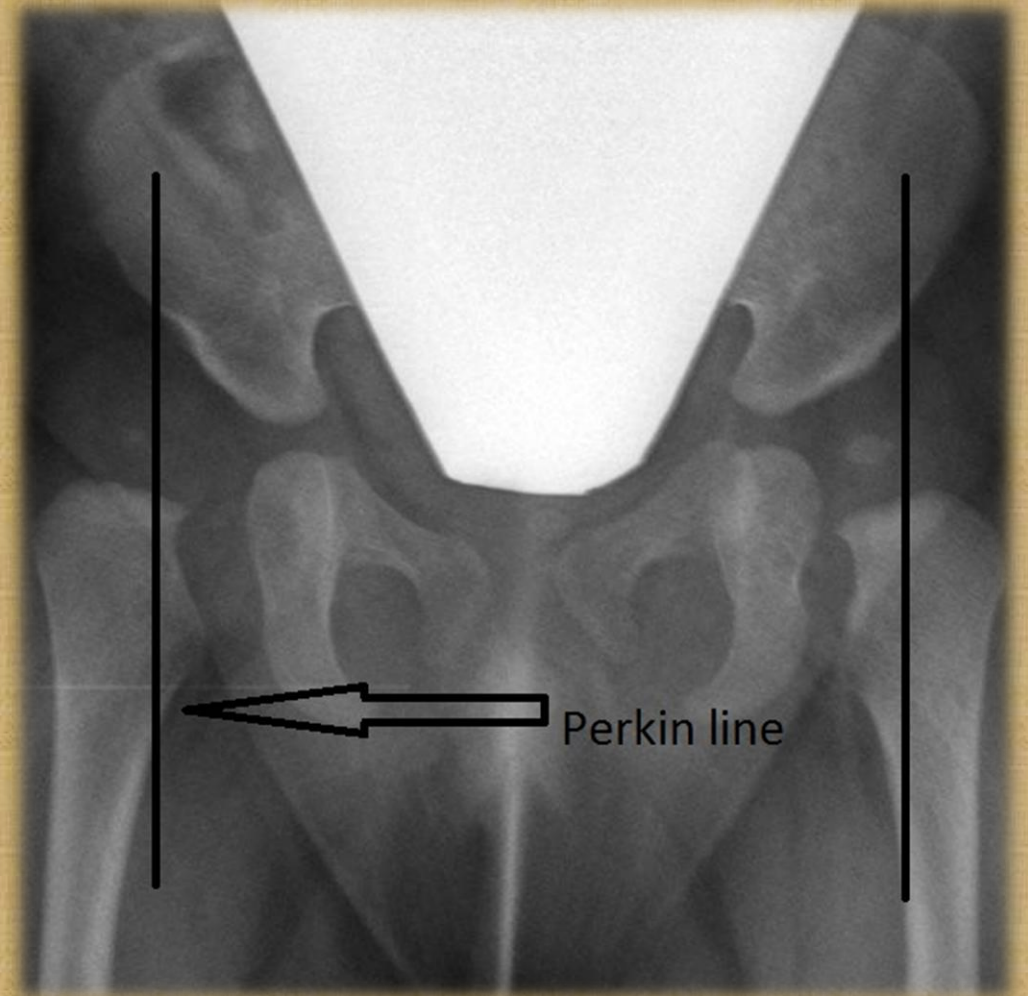
b – Disturbed Shenton's line.

(is drawn along the inferior border of the superior pubic ramus and should continue laterally along the inferomedial aspect of the proximal femur as smooth line)

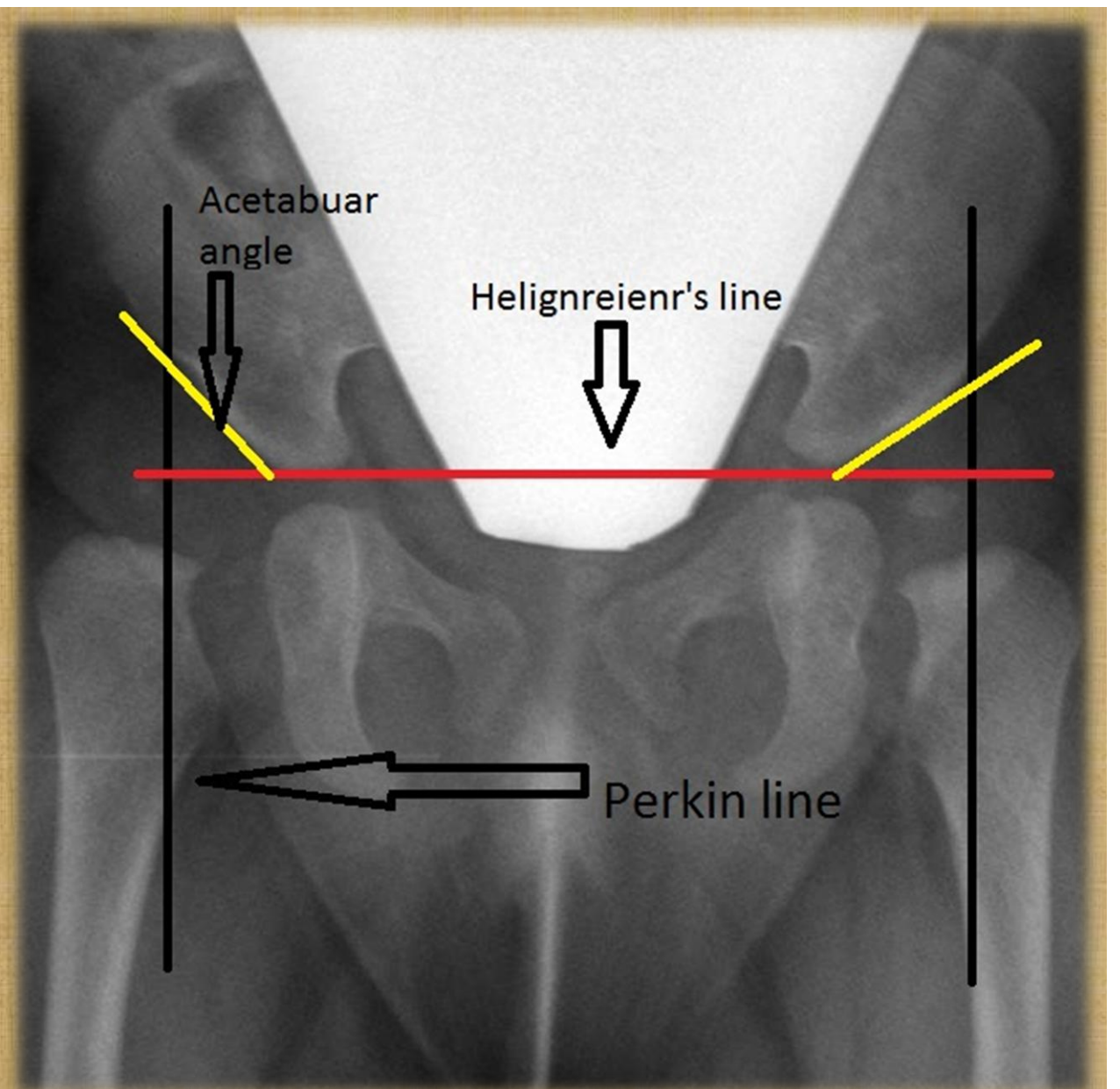
while in to DDH then this line will be discontinuous .



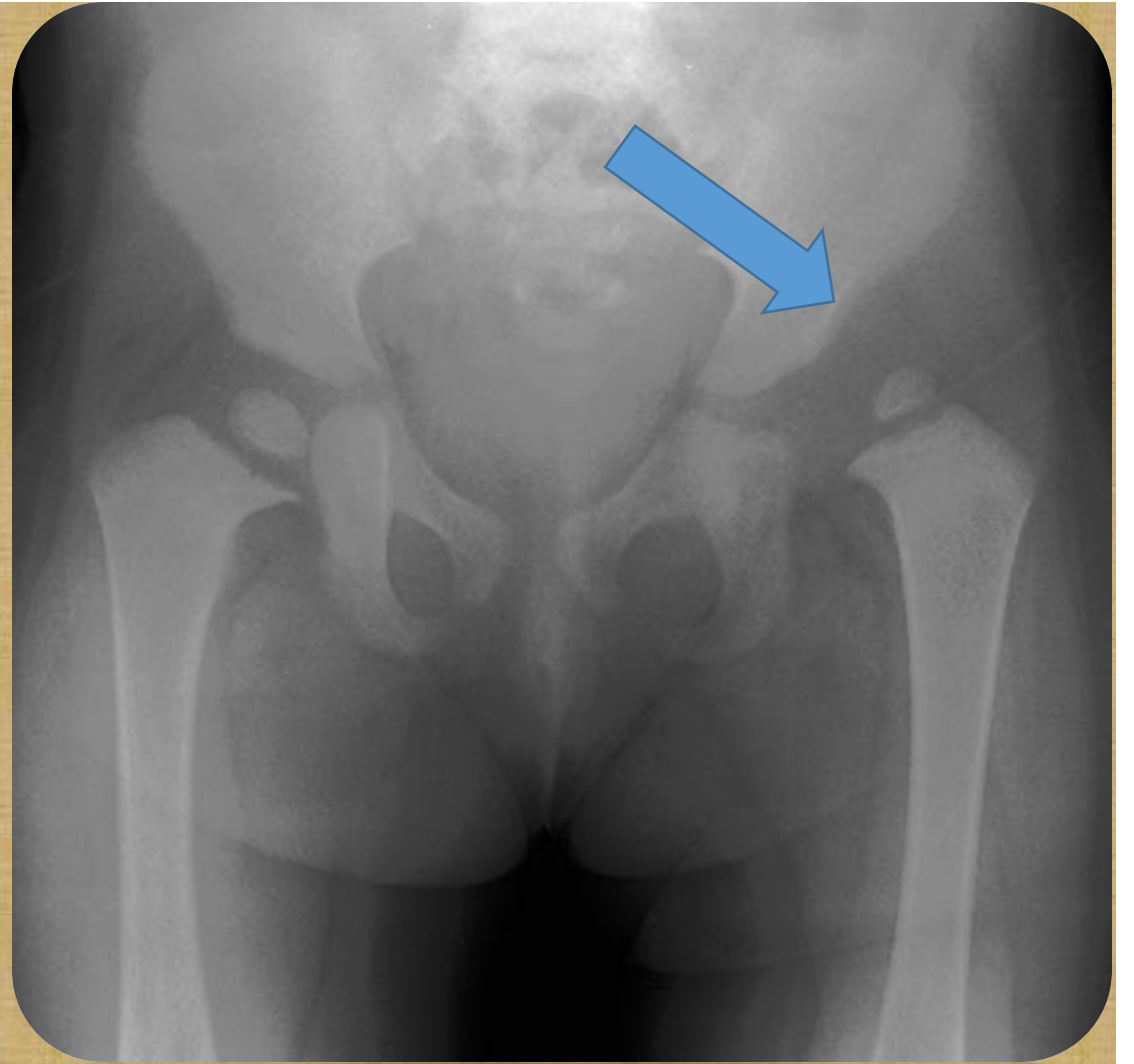
c- the femoral epiphysis is lat. To Perkins' line :
which is d drawn vertically
from the outer most aspect
of the acetabulum,



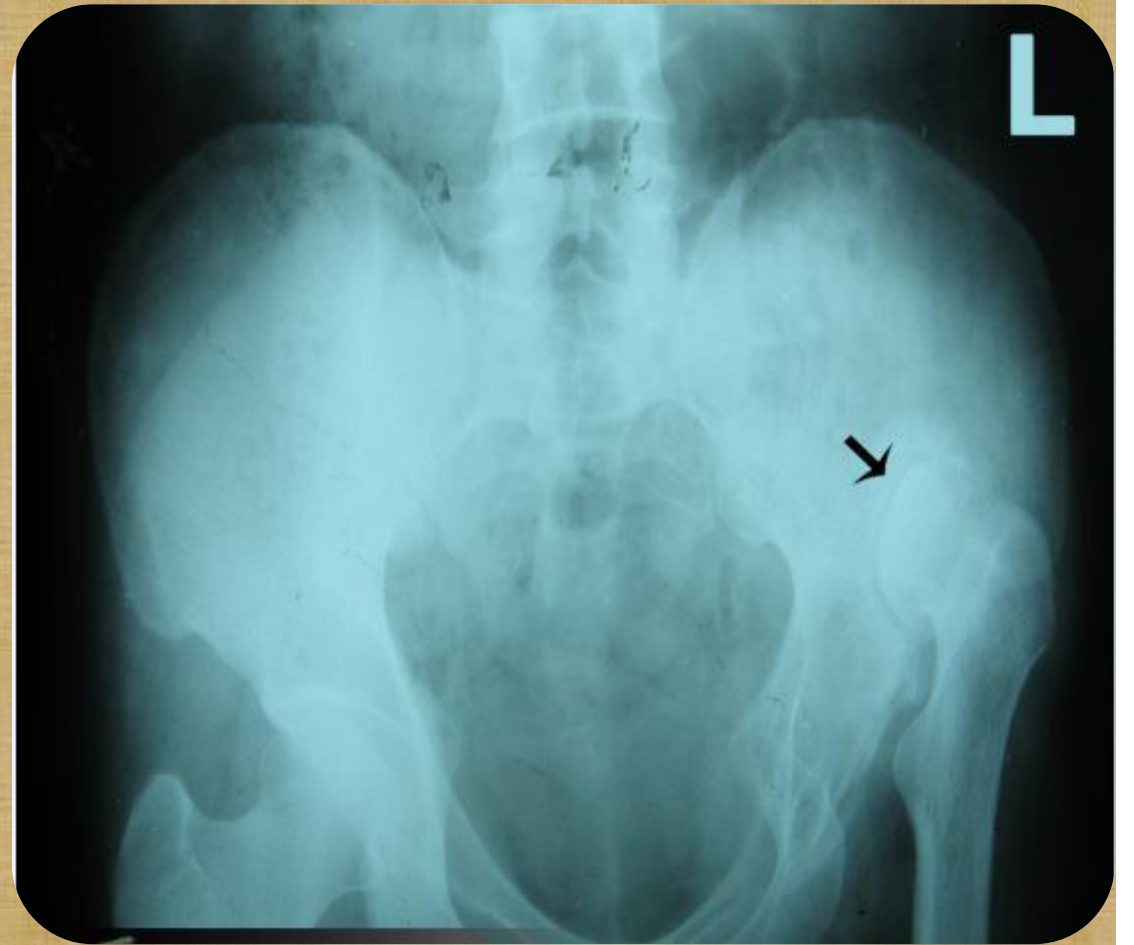
d – Acetabular angle
more than 30 degree



E – Shallow Acetabular cavity
and directed upward



F – In advanced cases there will be Pseudarthrosis of femoral head with the iliac bone :





And thank you for listening