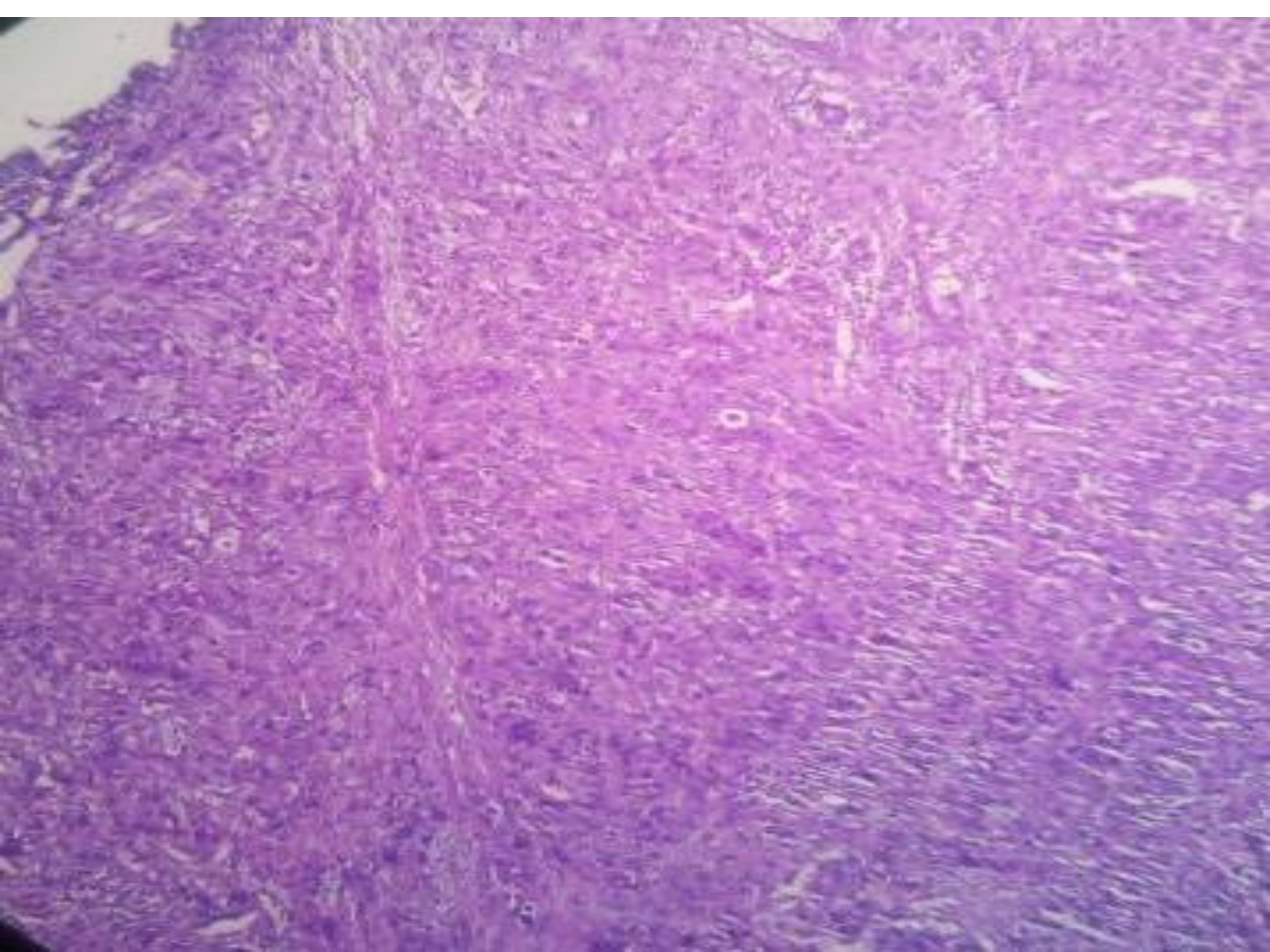
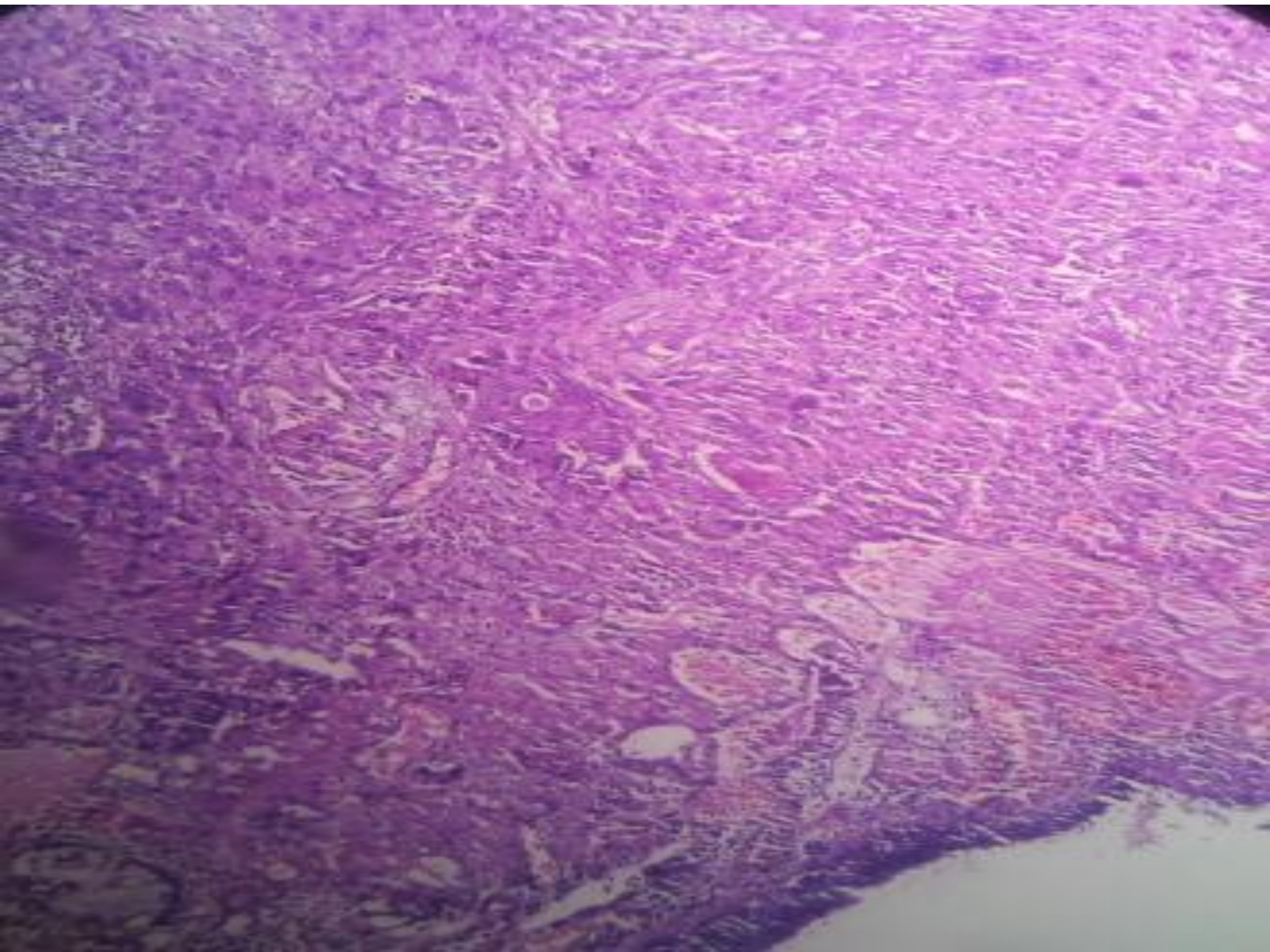
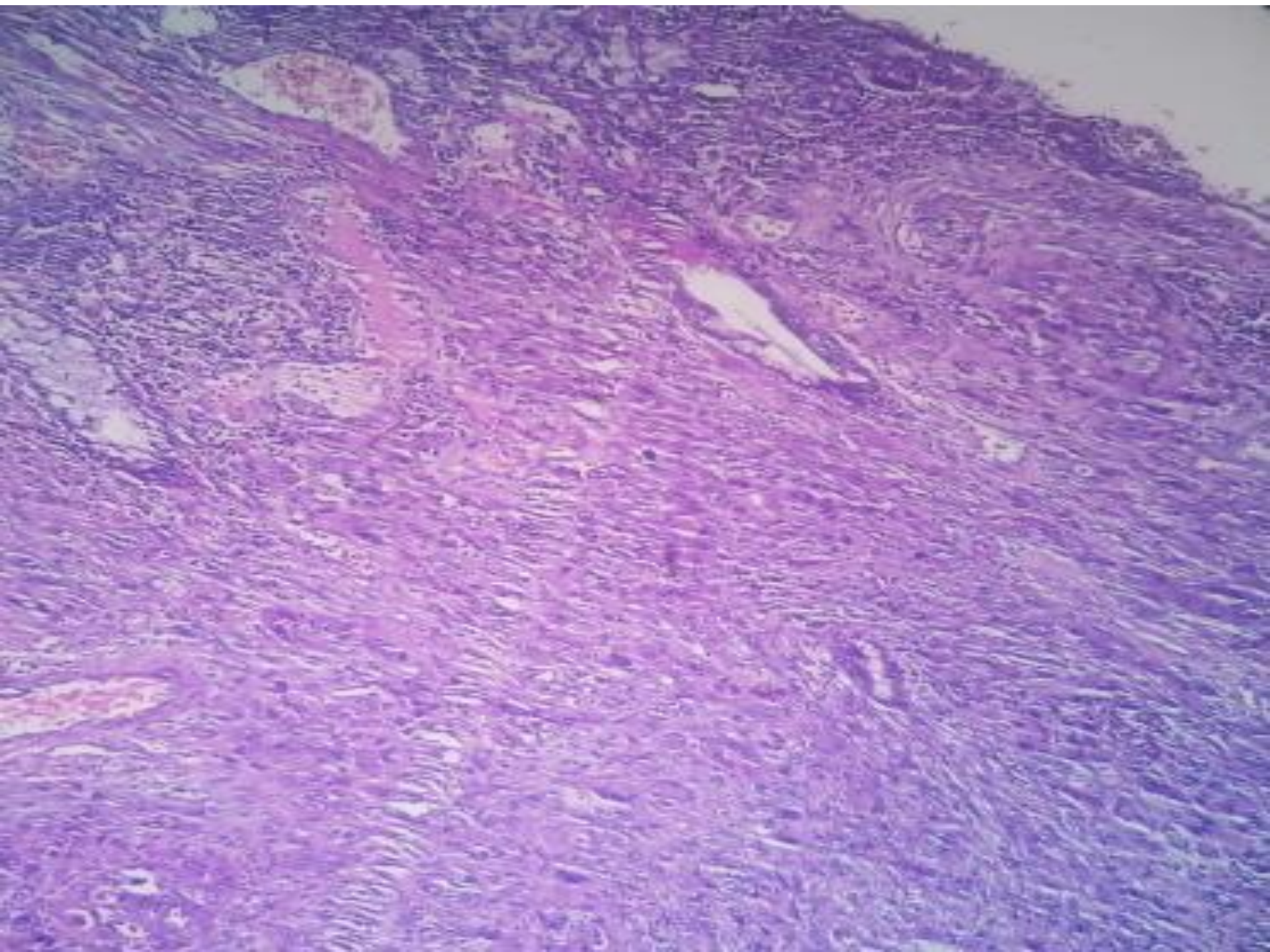


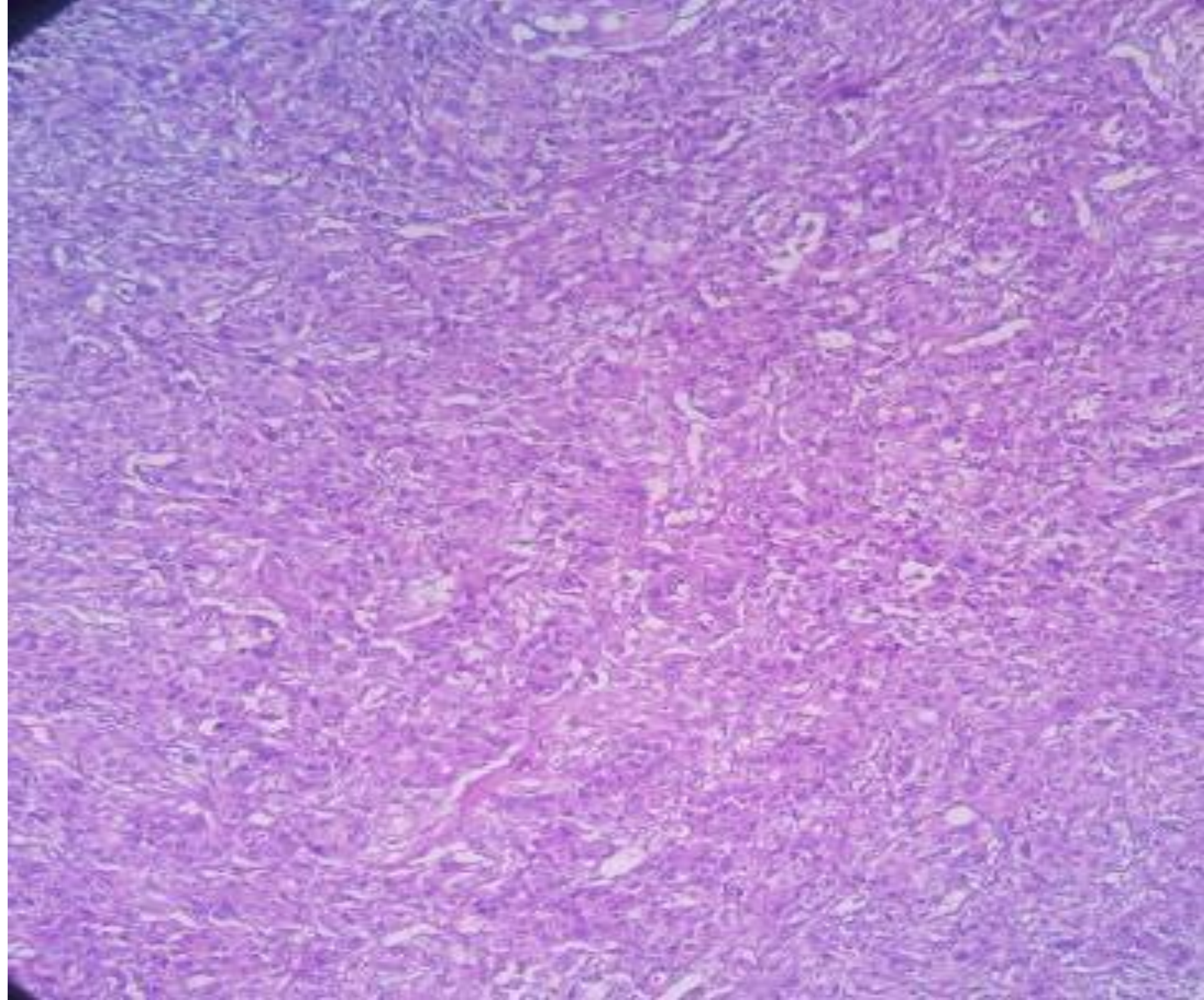
13 th Slide Meeting

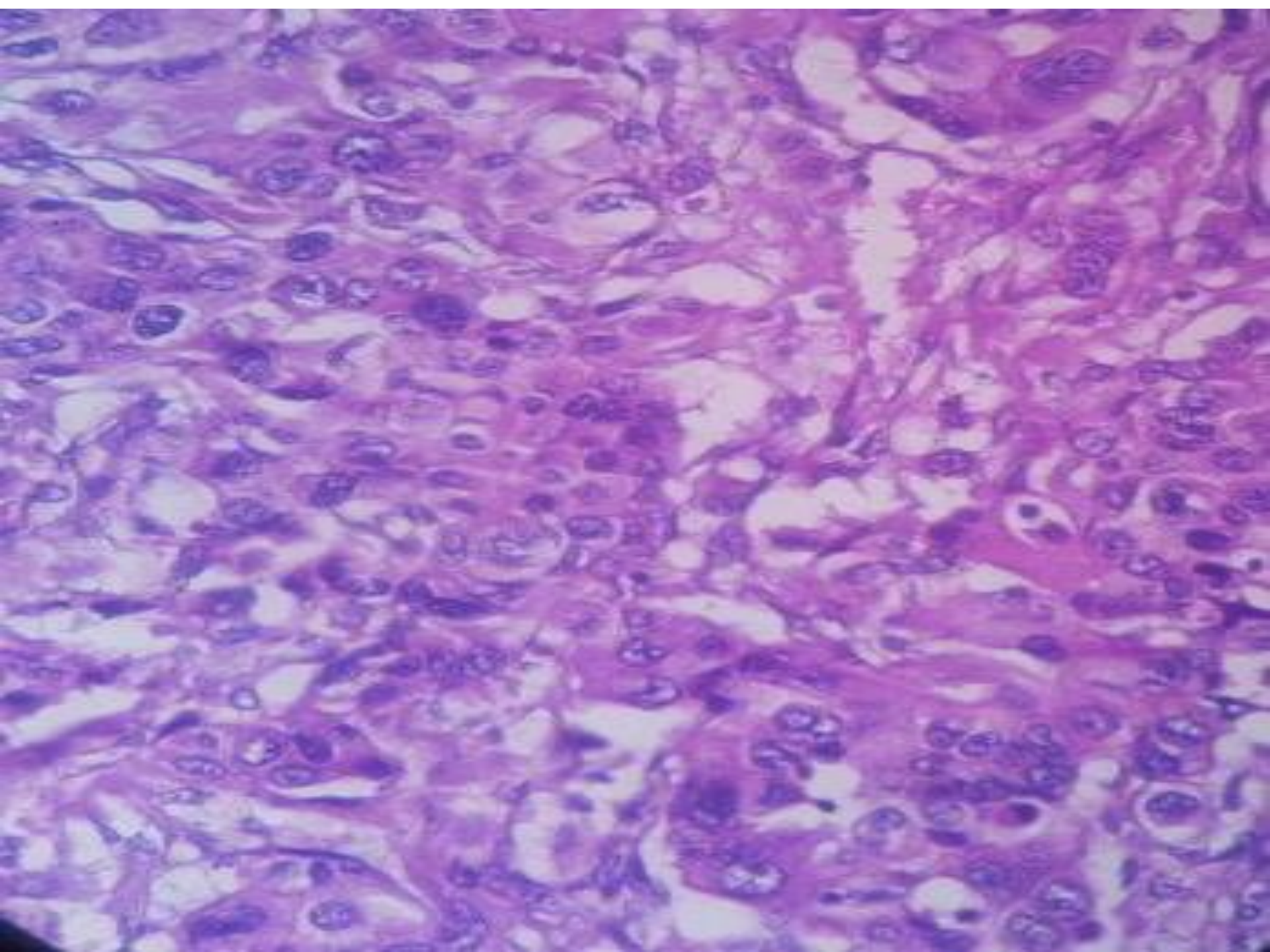
- 47 Y.M lung mass.

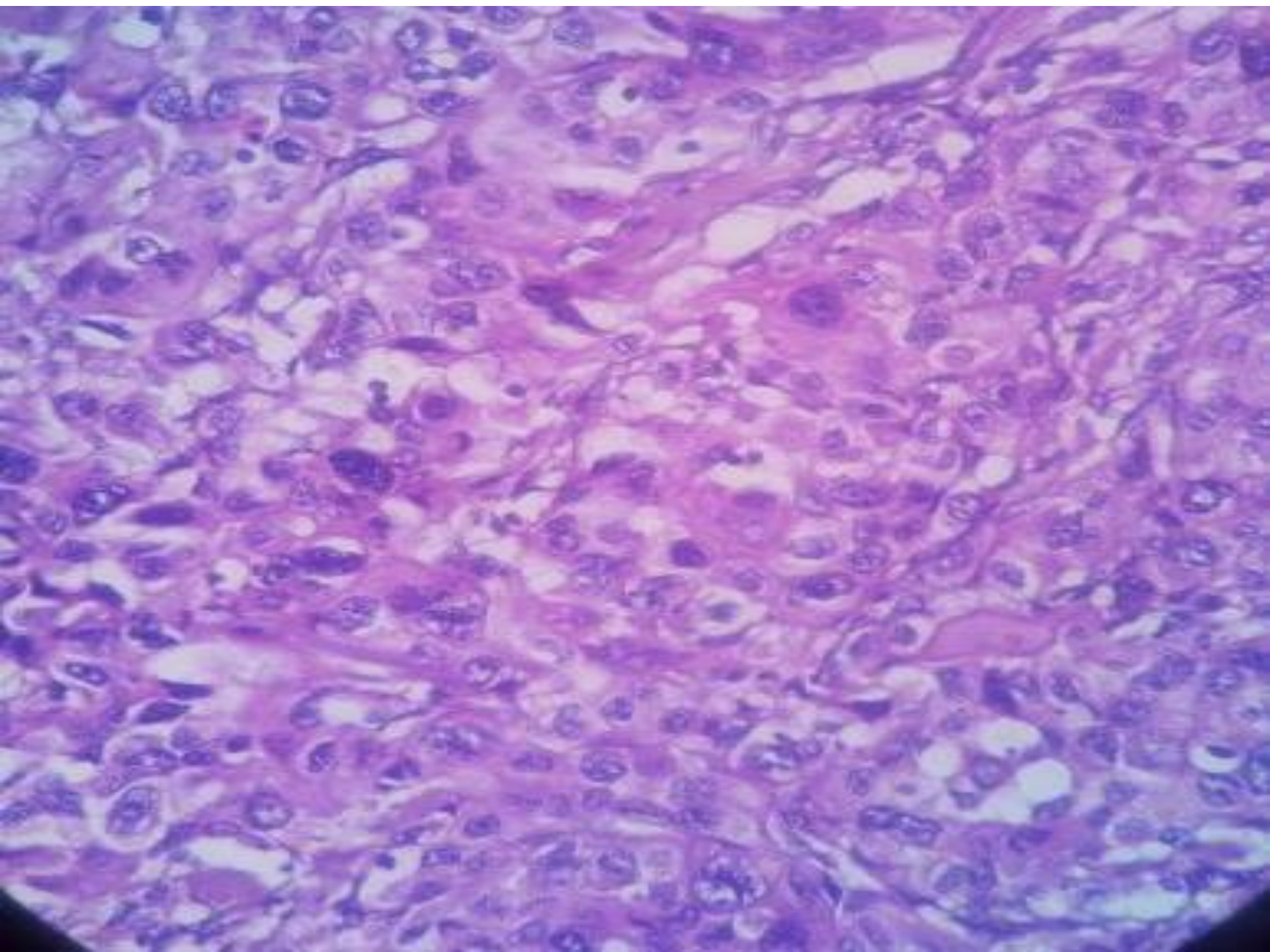




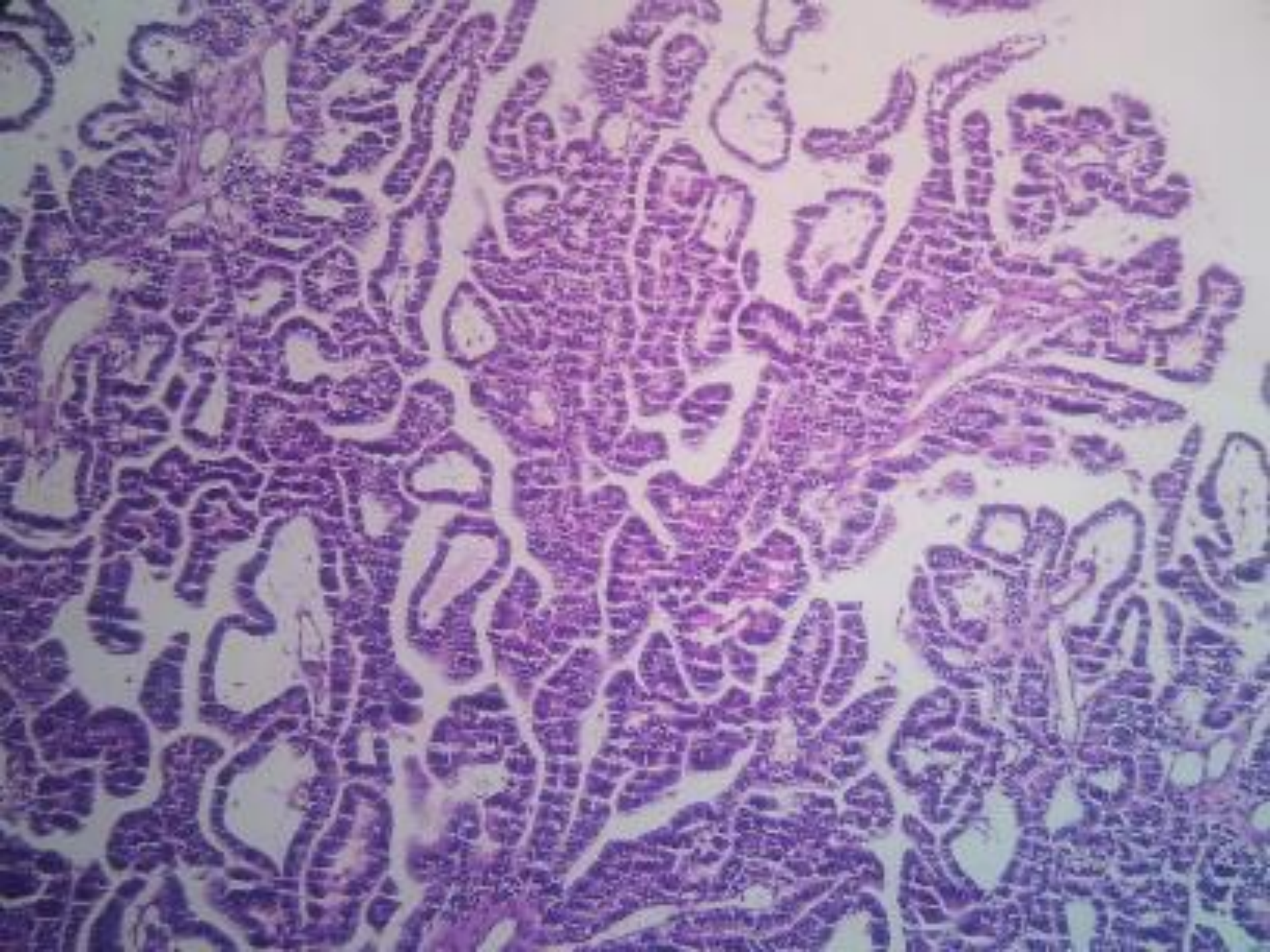


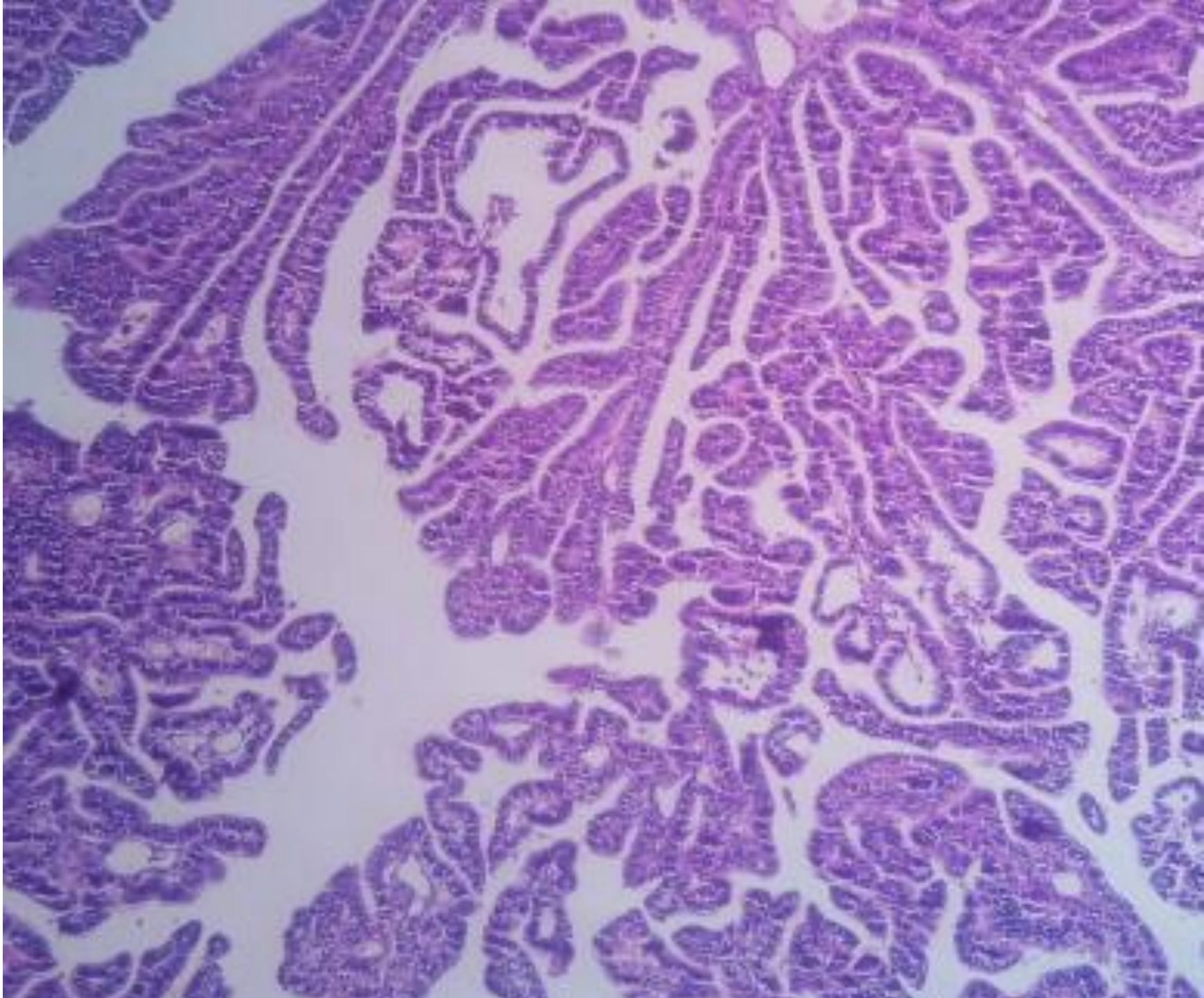


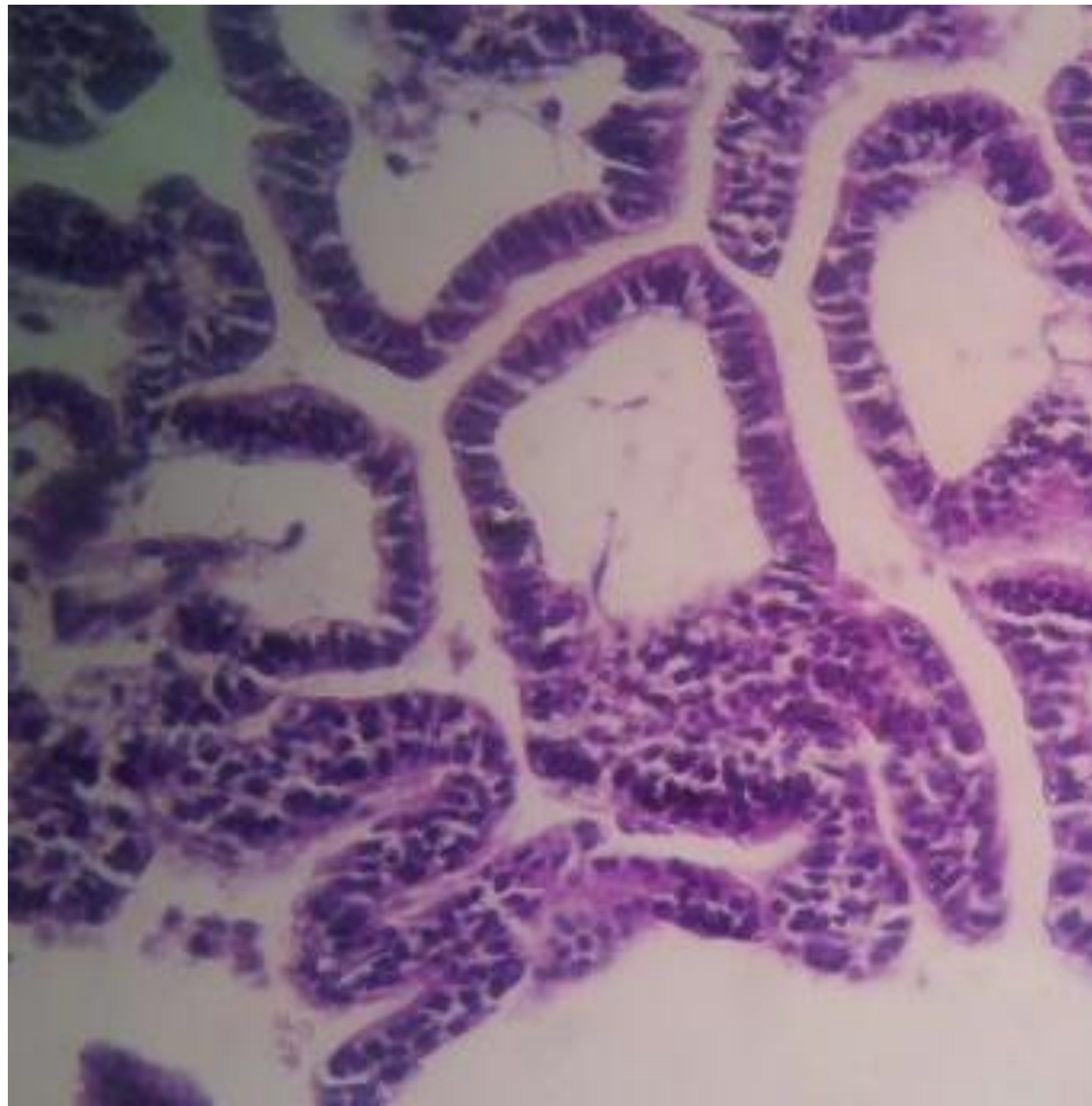



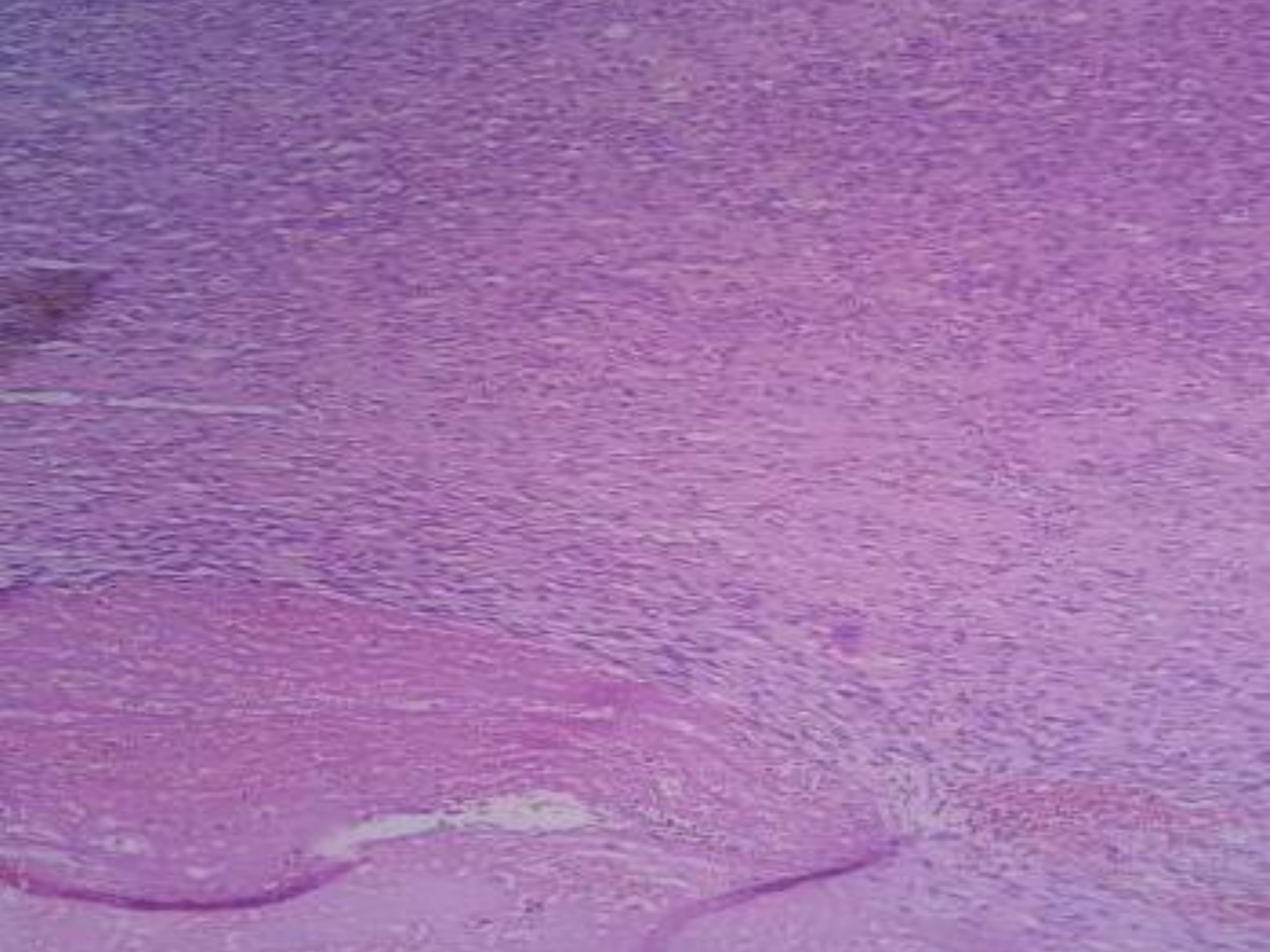
- 10 month F. with brain tumor.

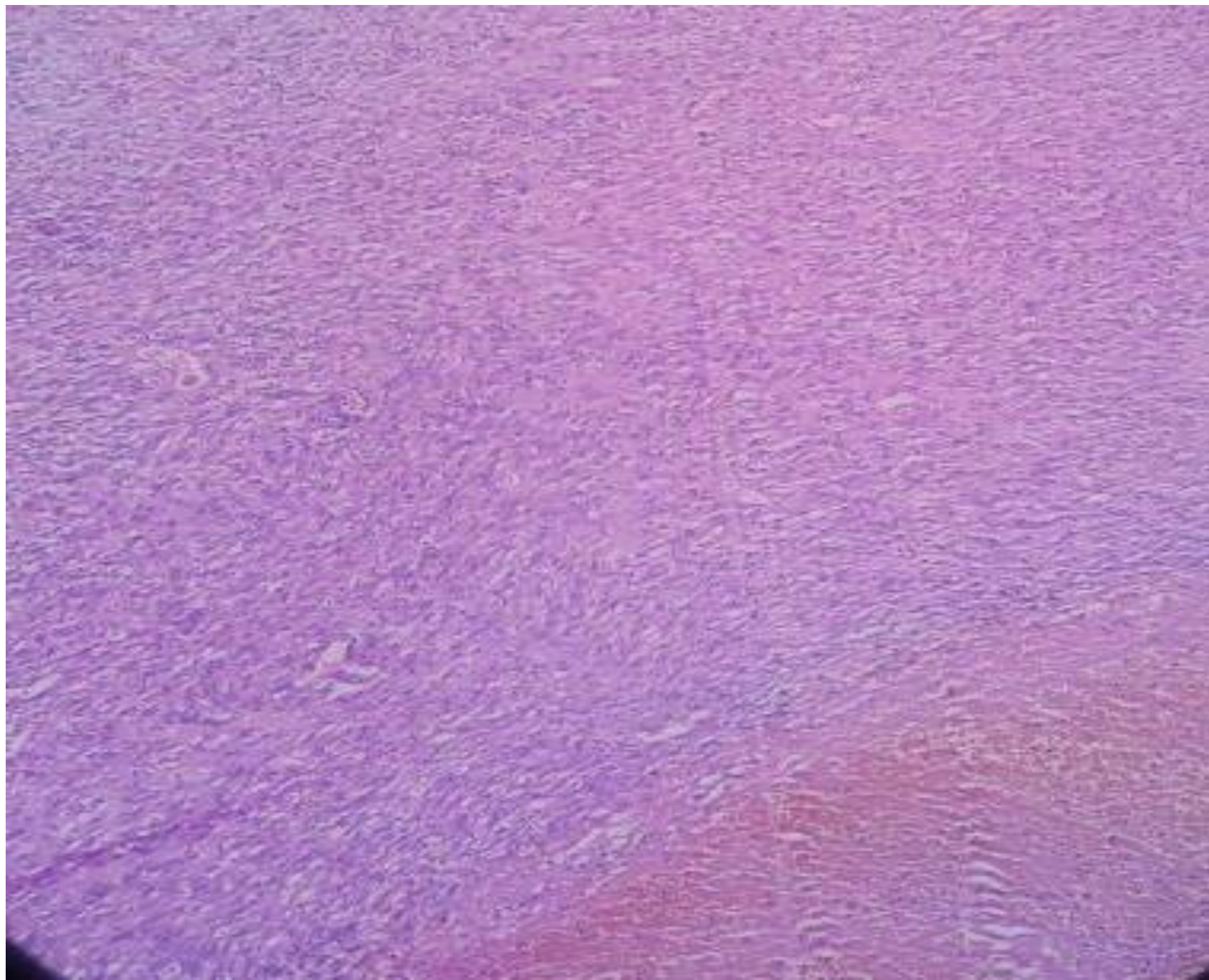


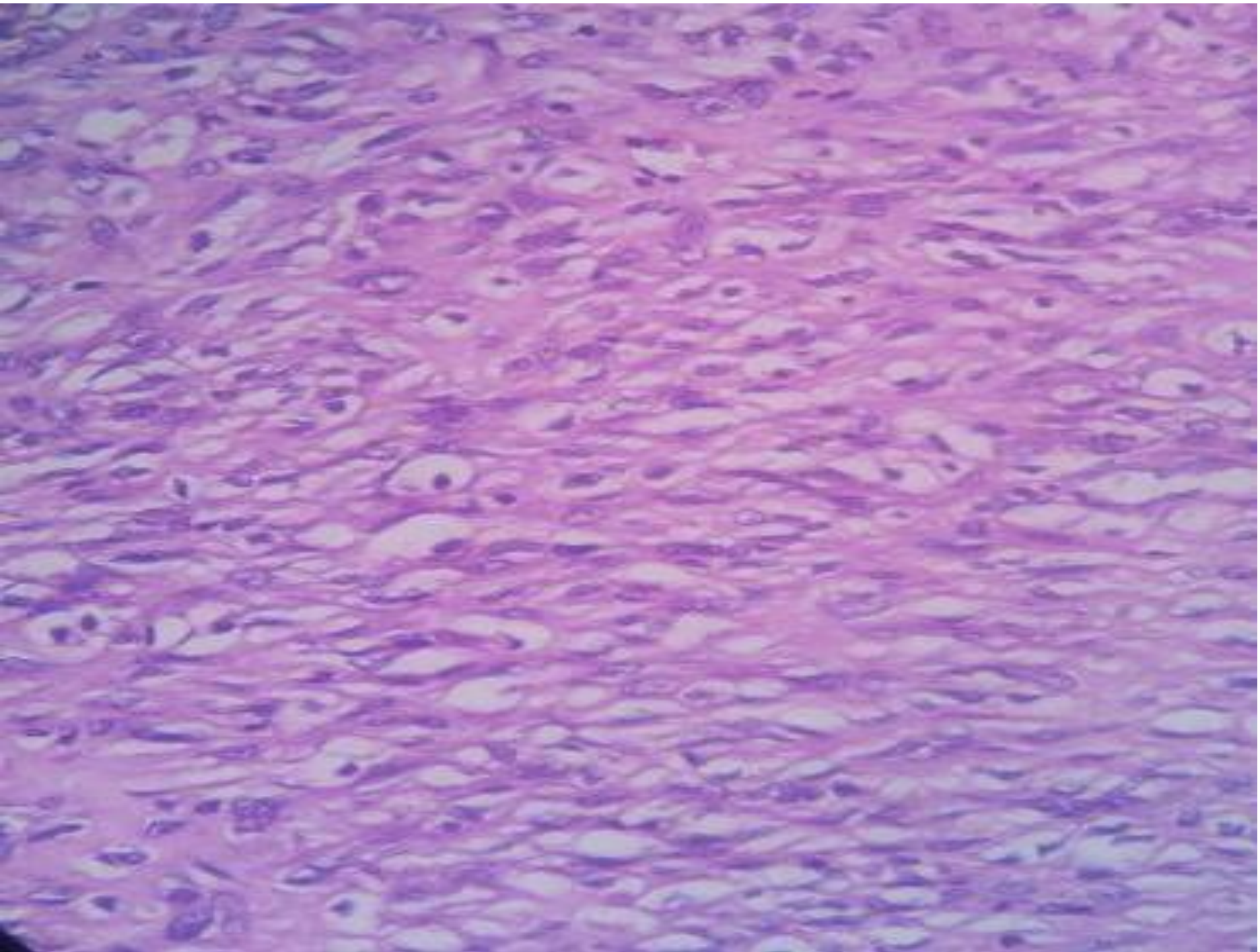


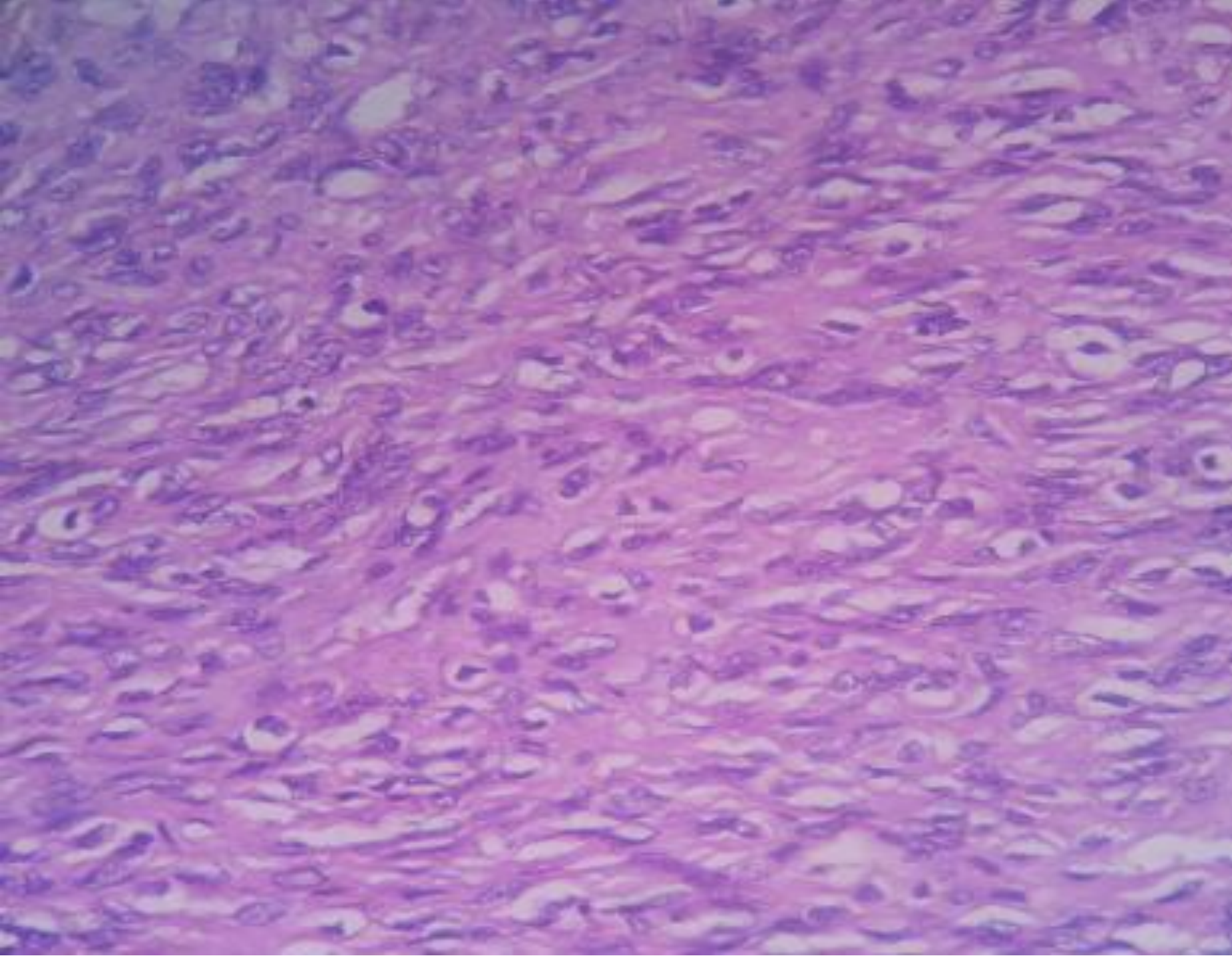


- 75 Y.M. shoulder mass .

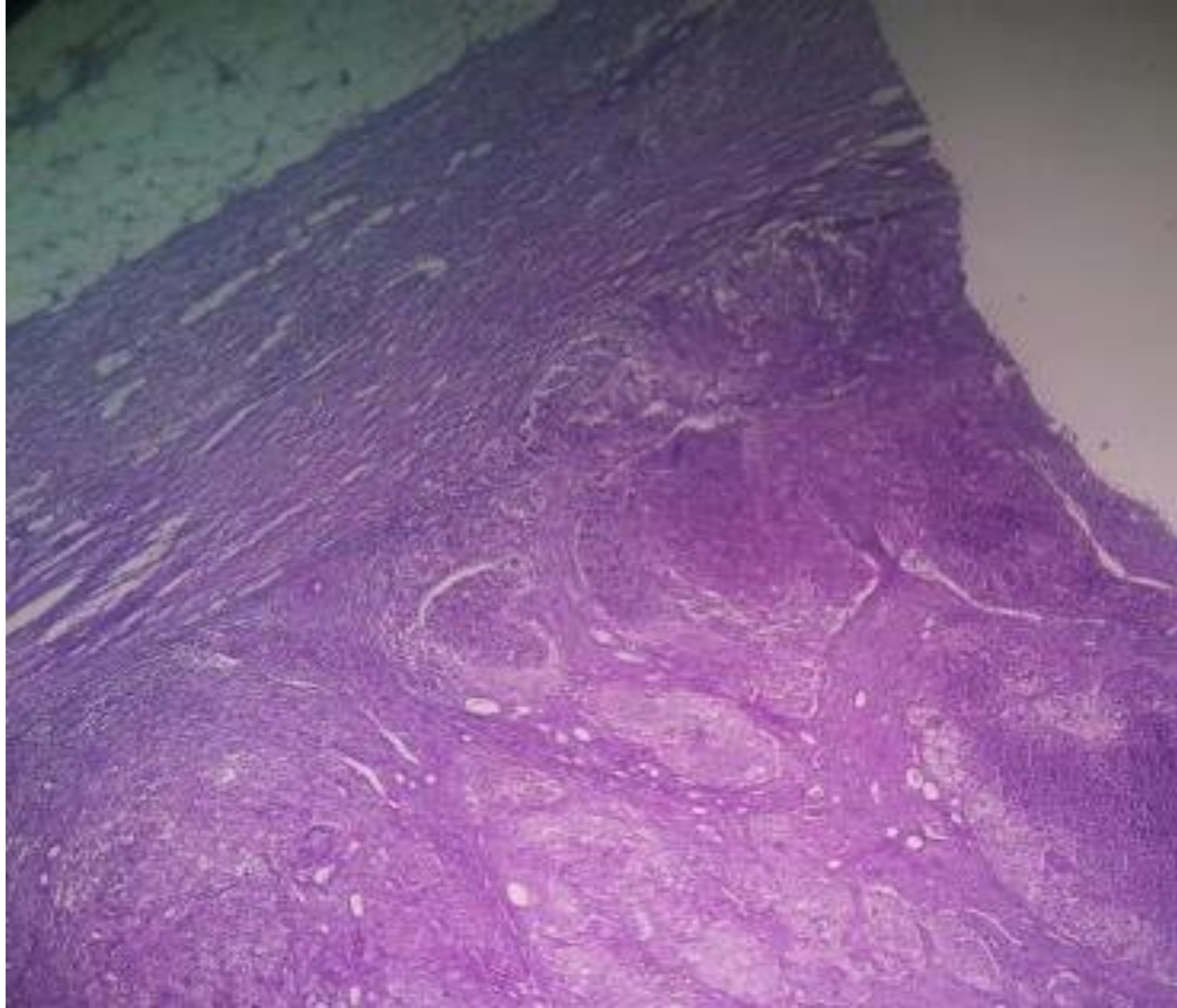


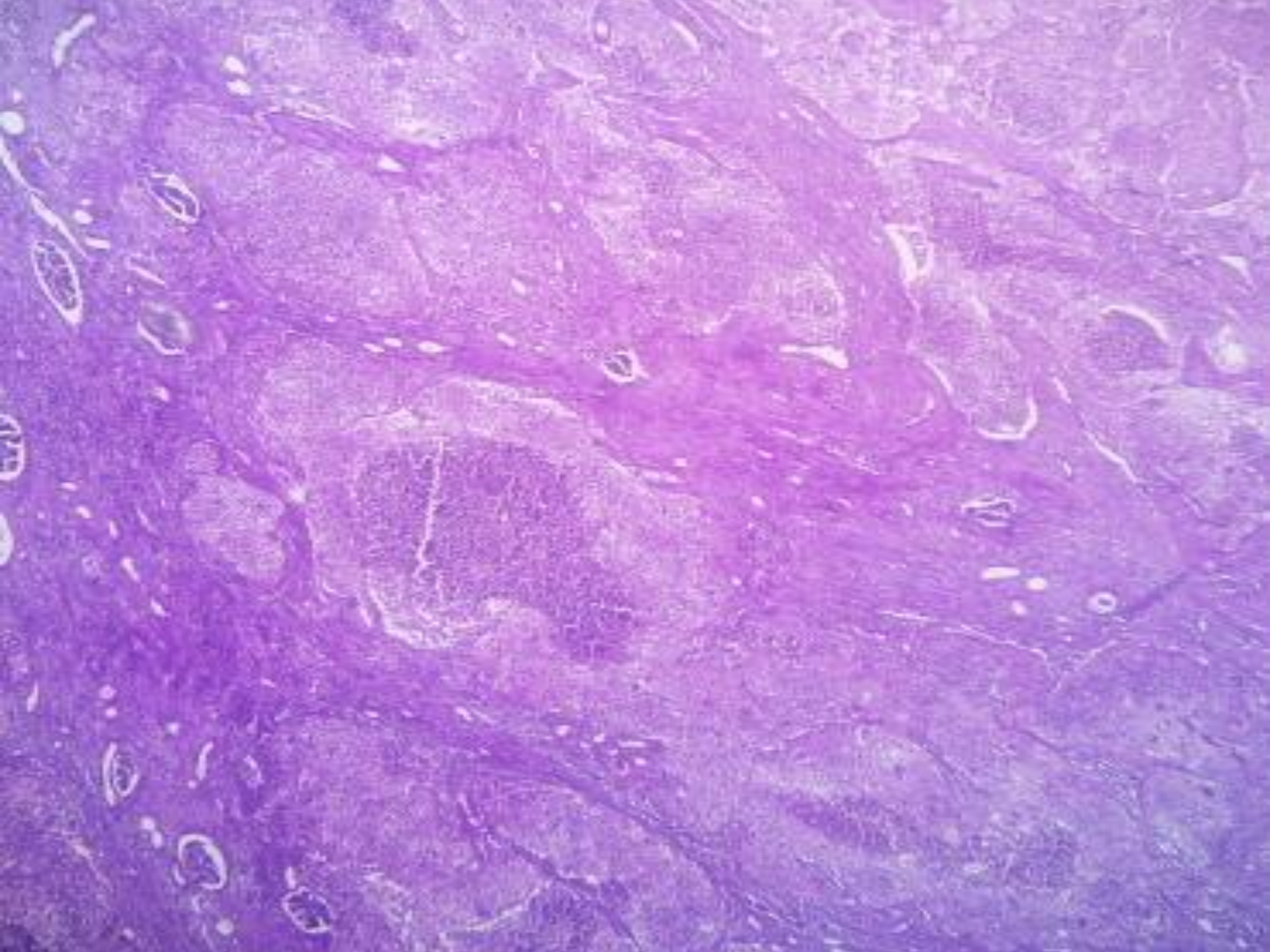


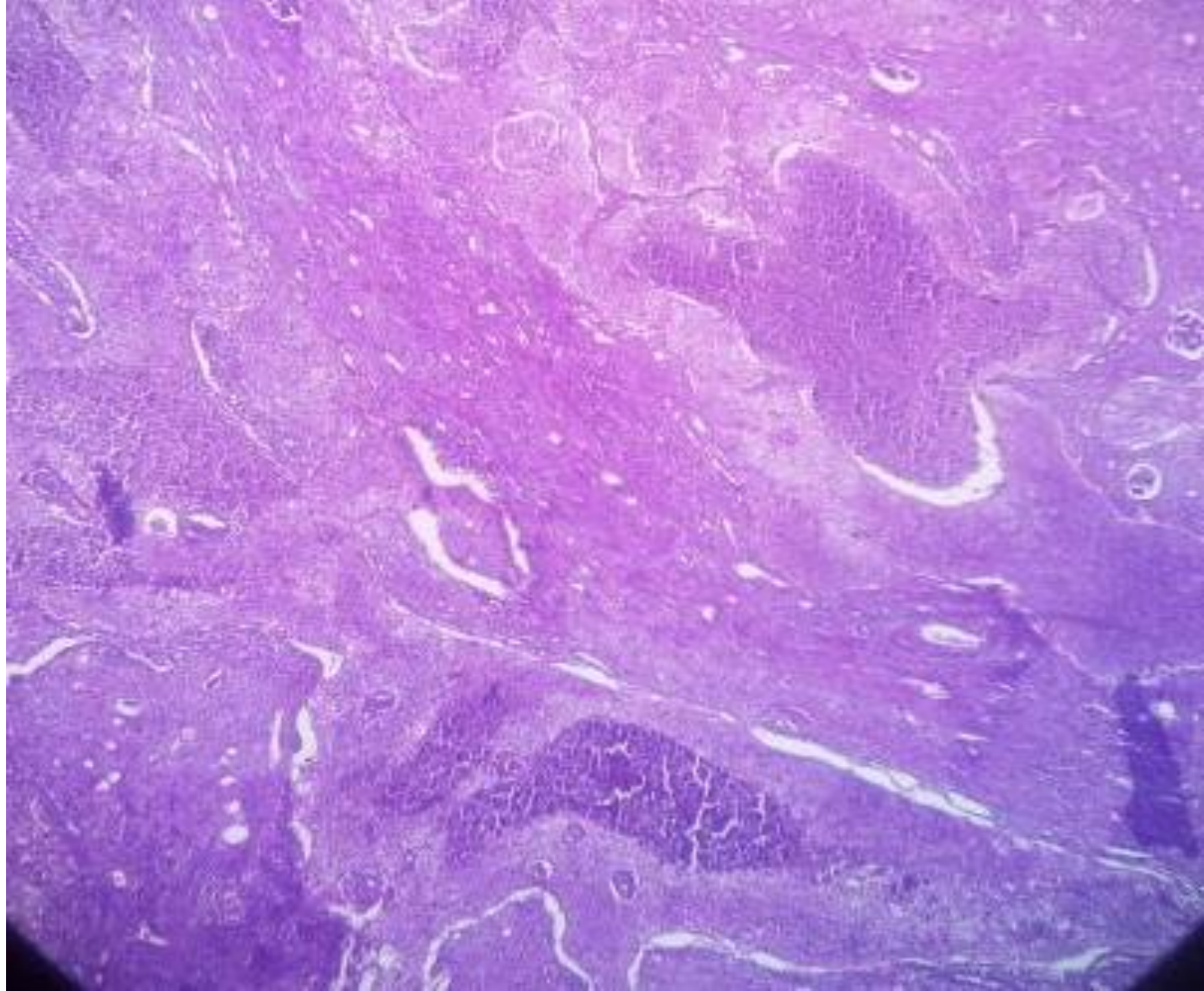


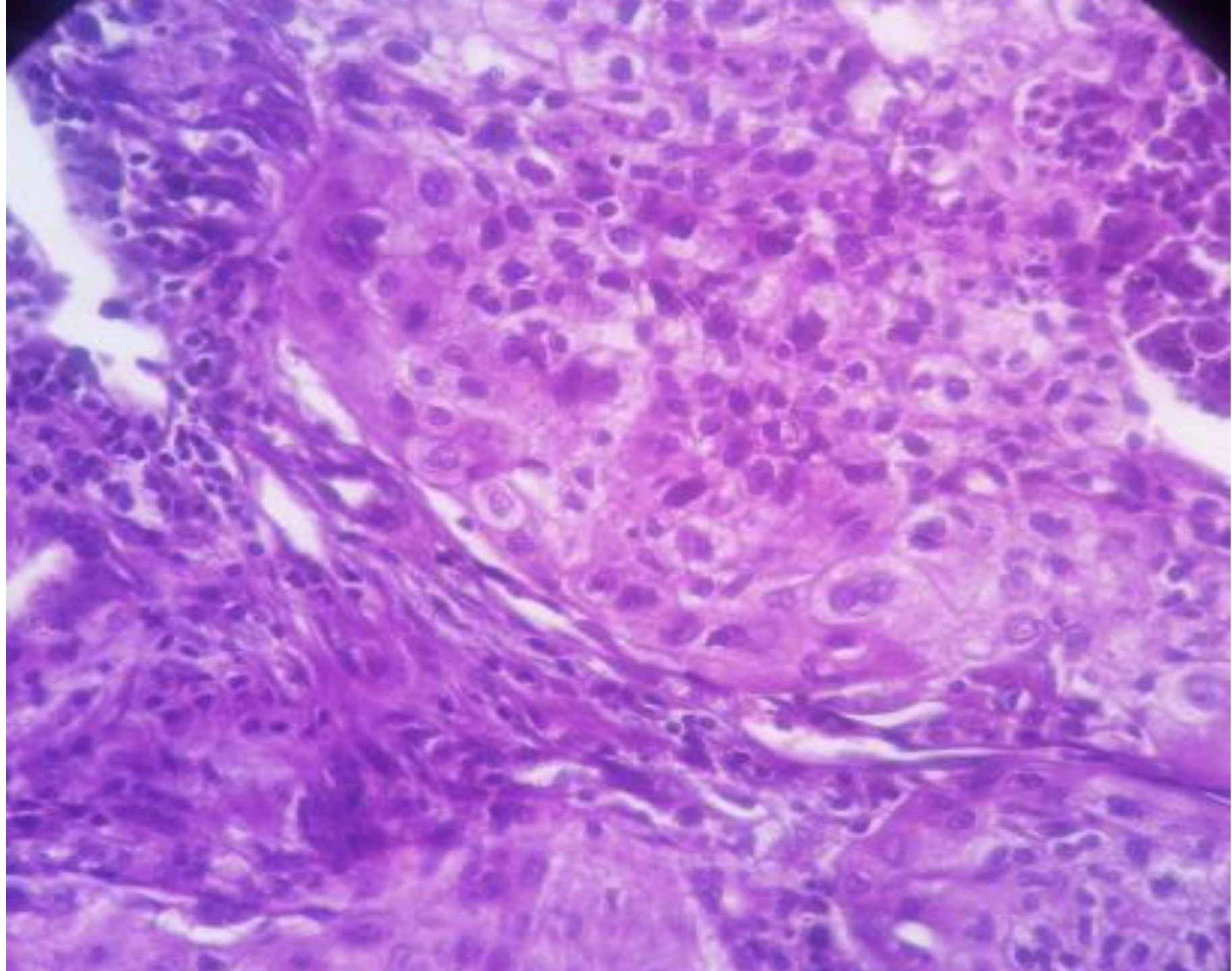


- 79Y.M mass at lower pole of kidney

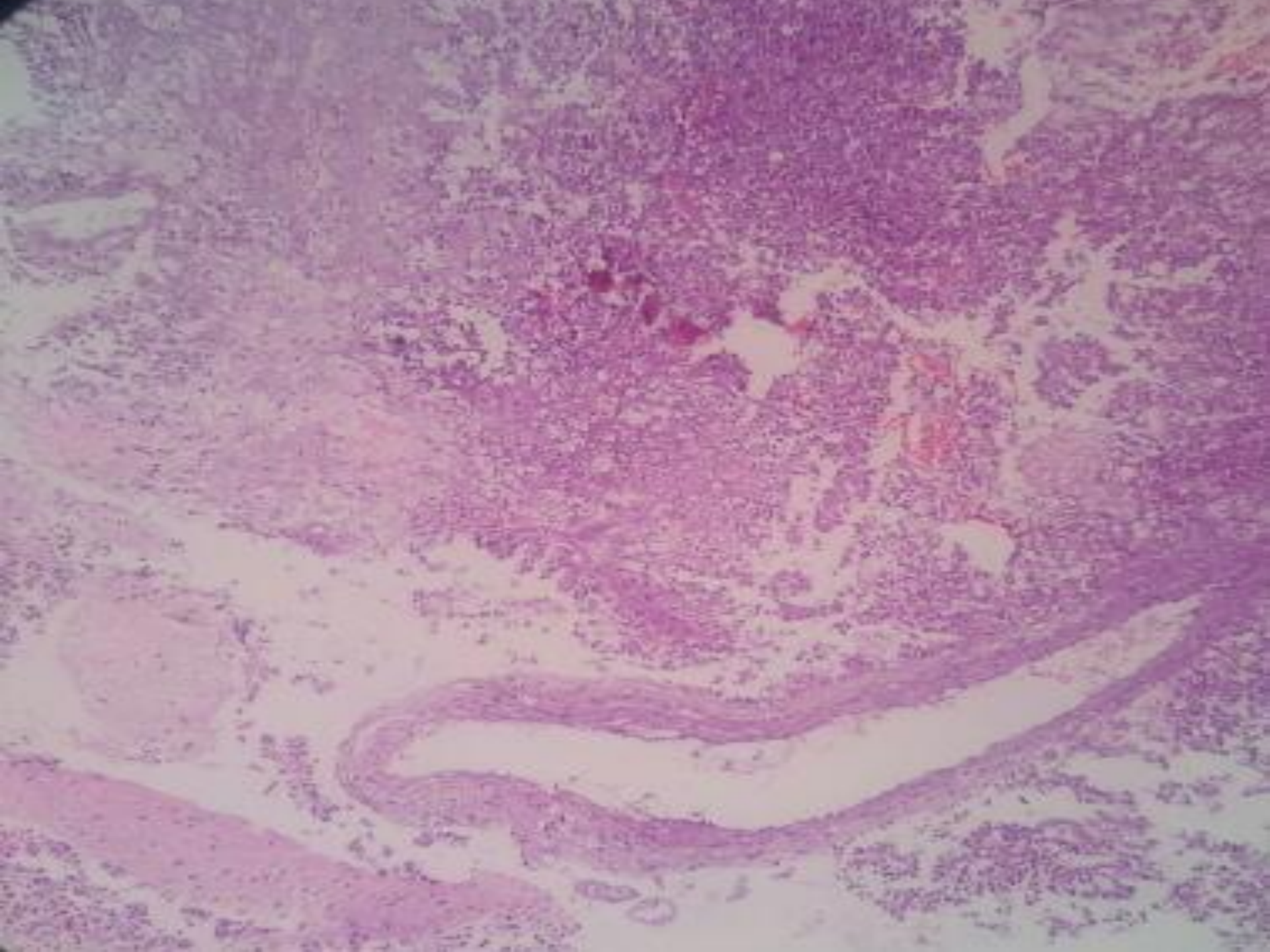


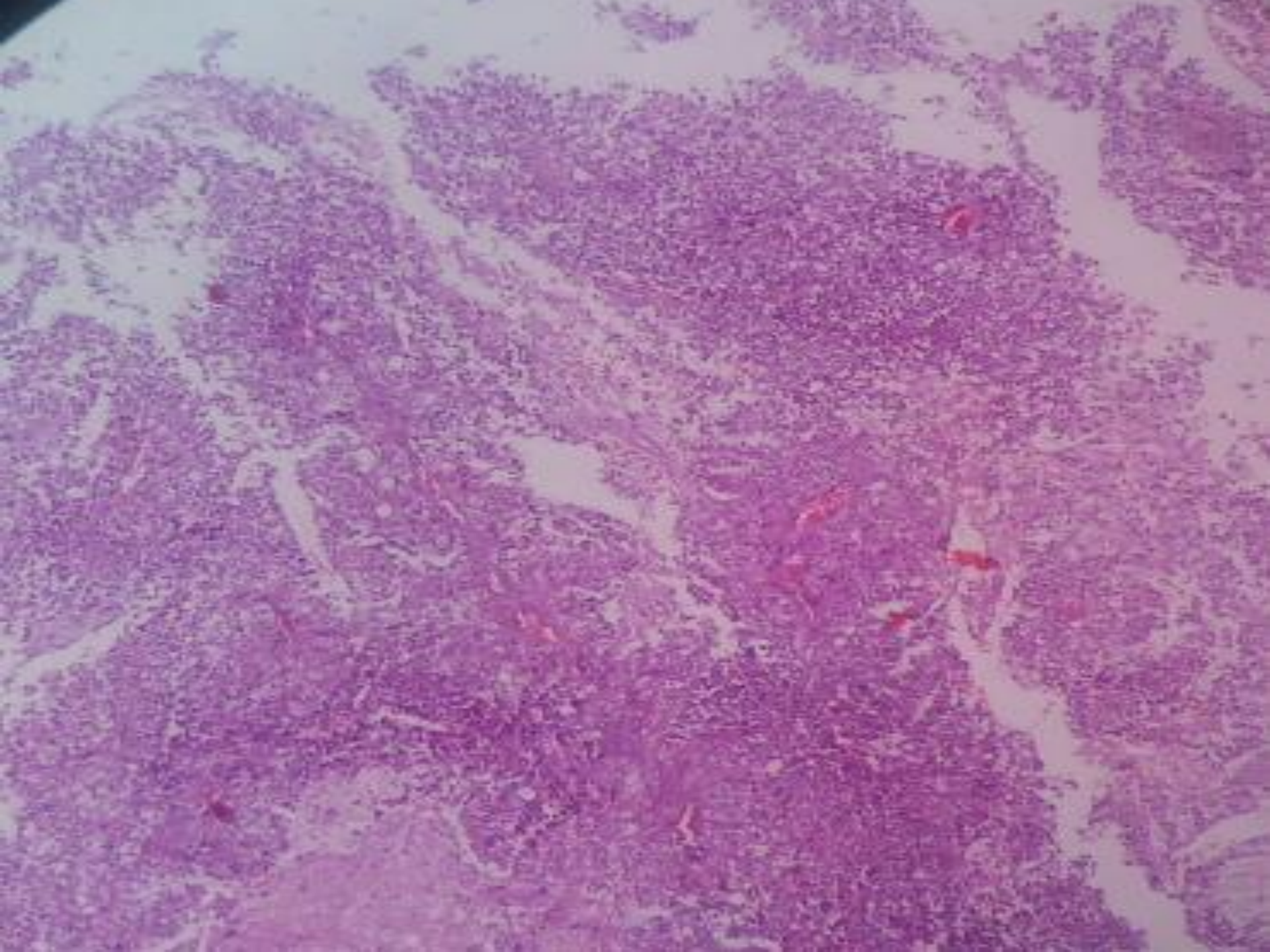


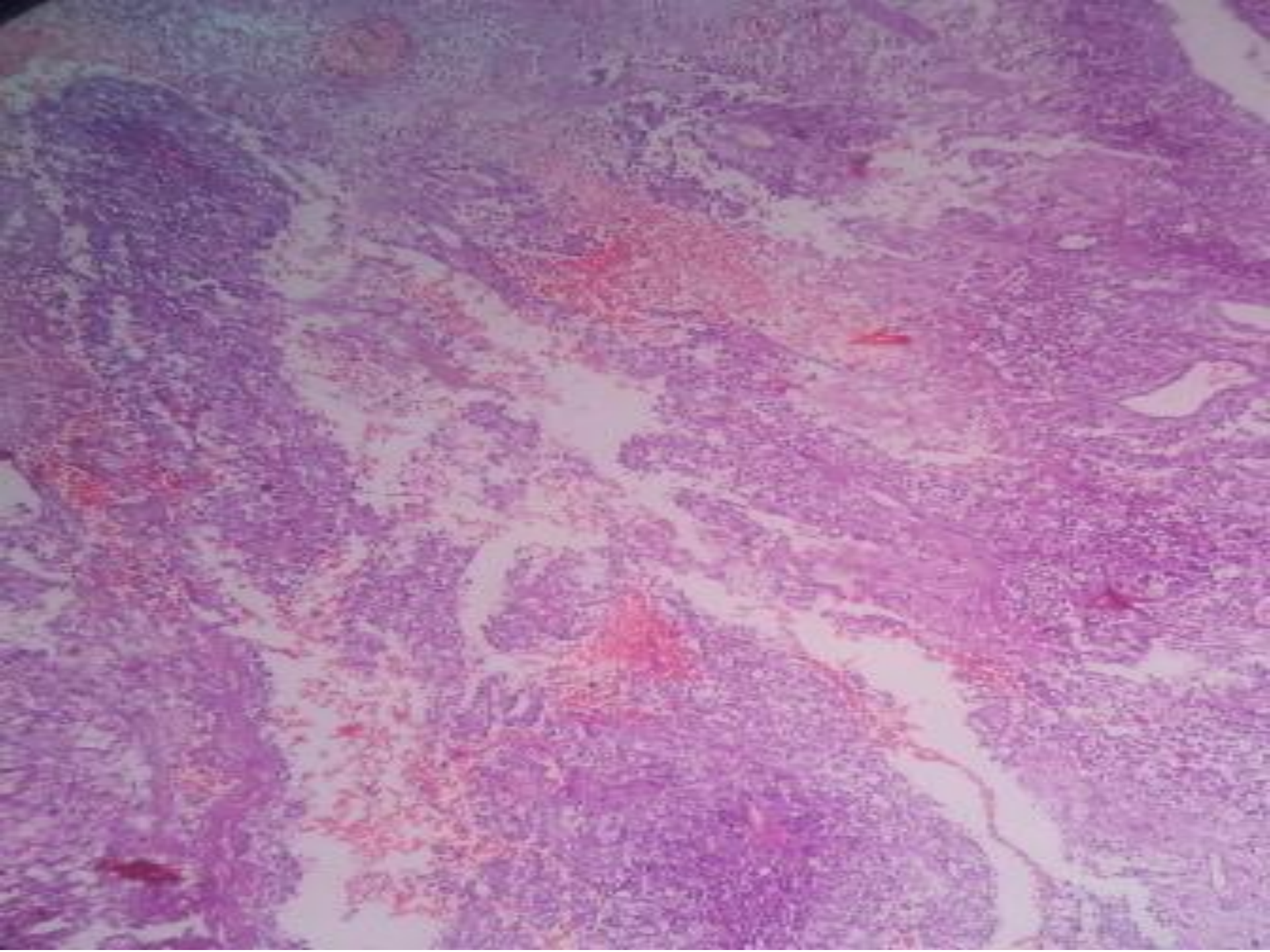


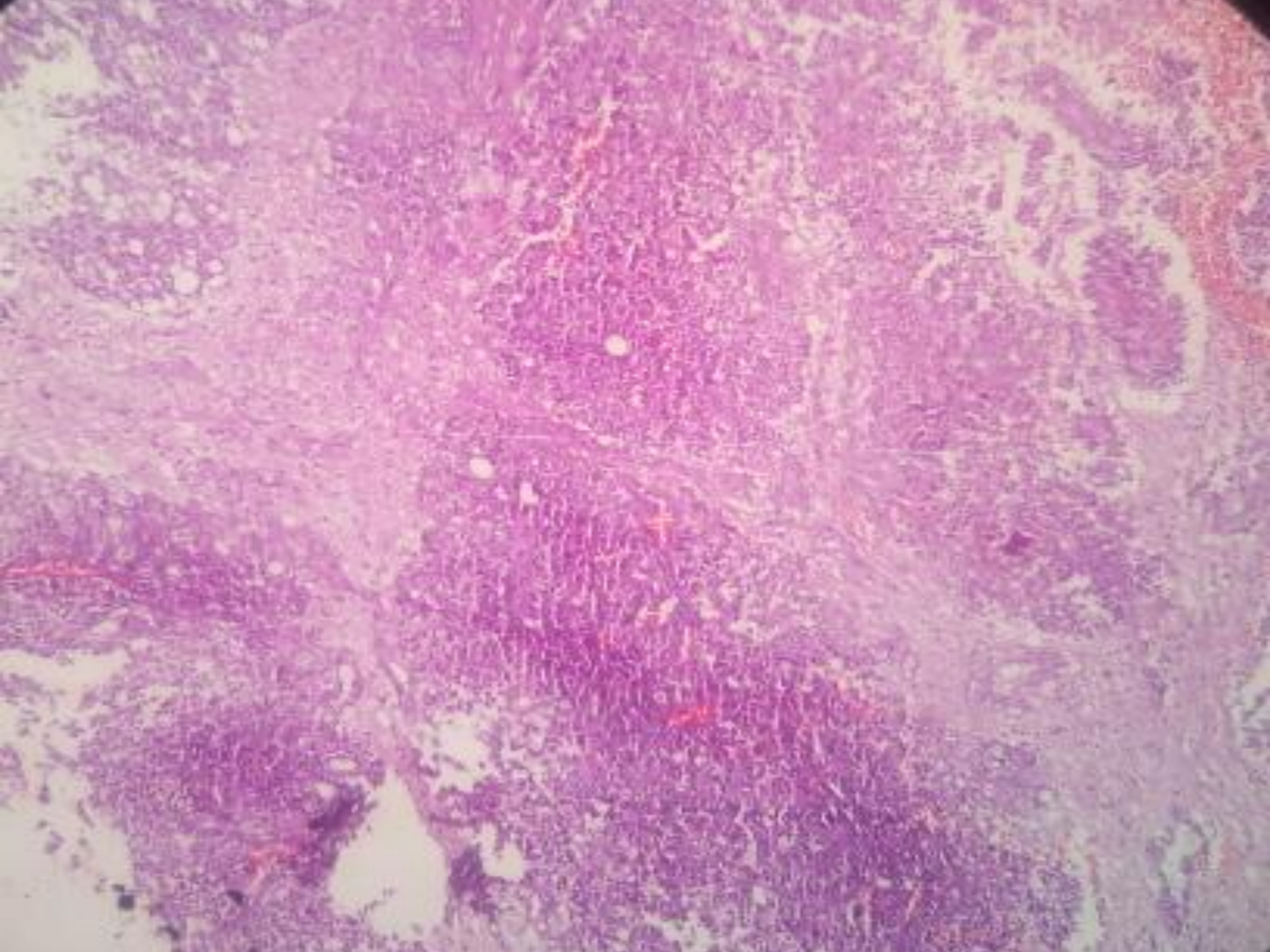


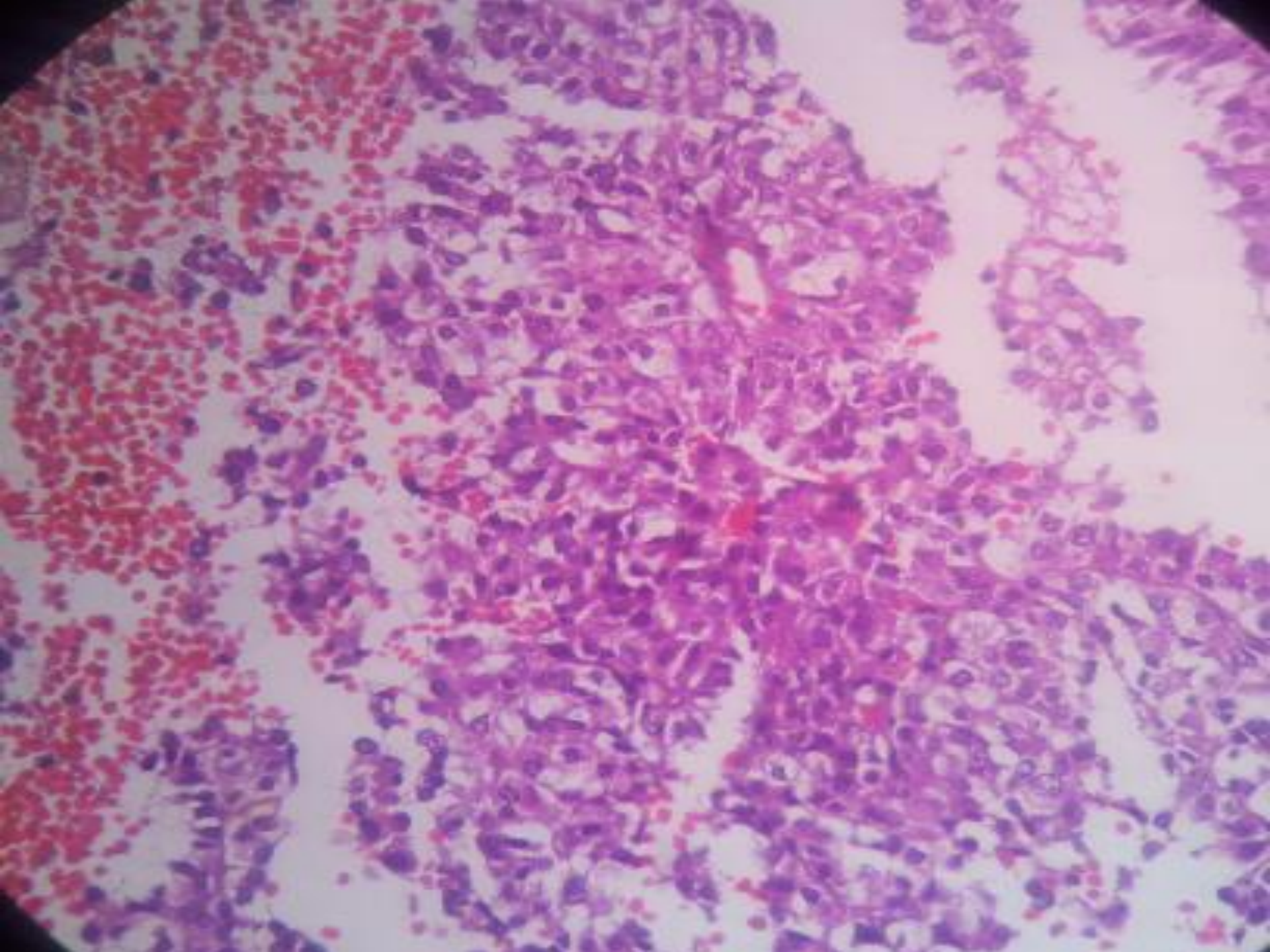
- 2 Y.M temporo-parietal brain tumor



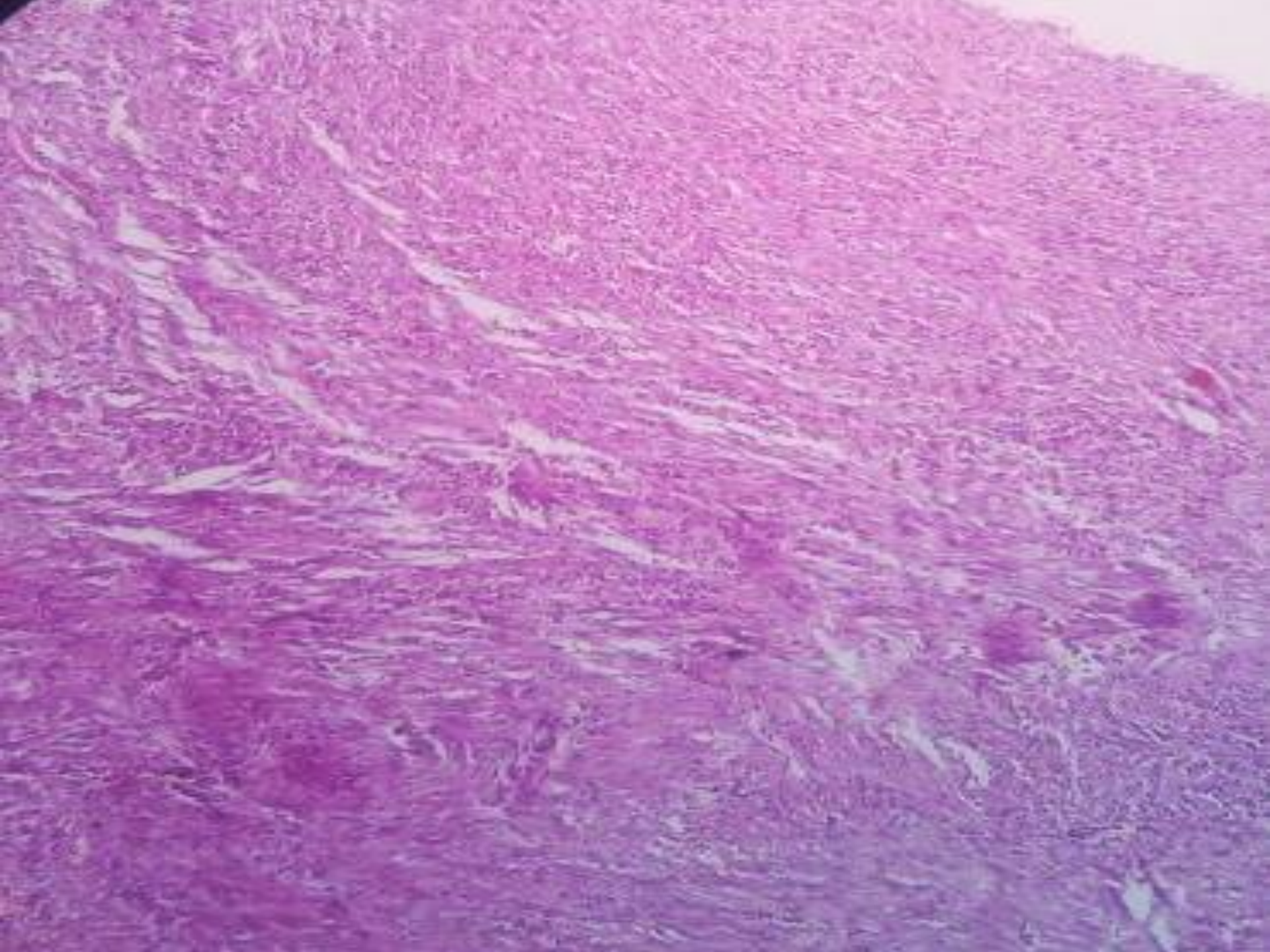


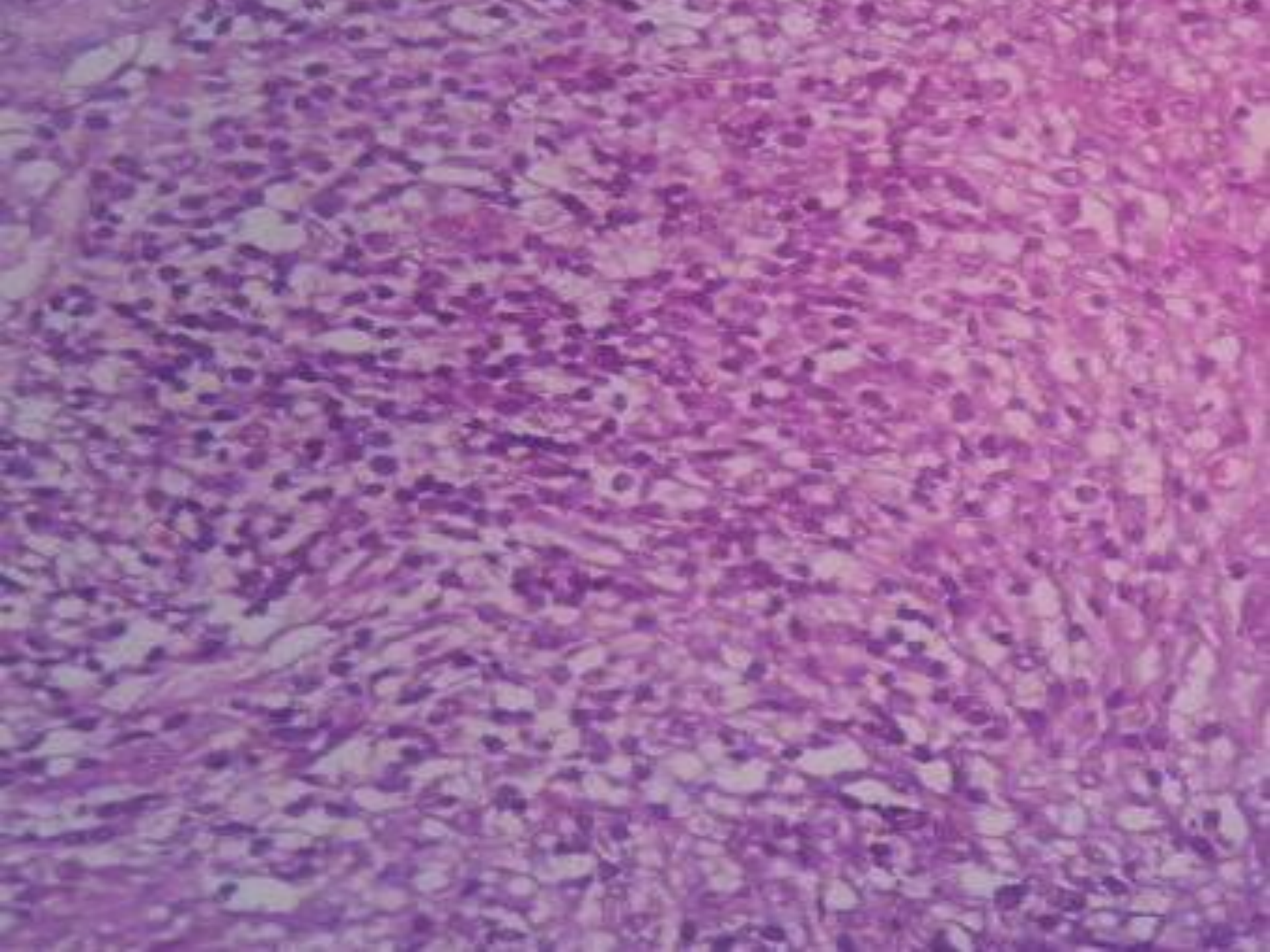


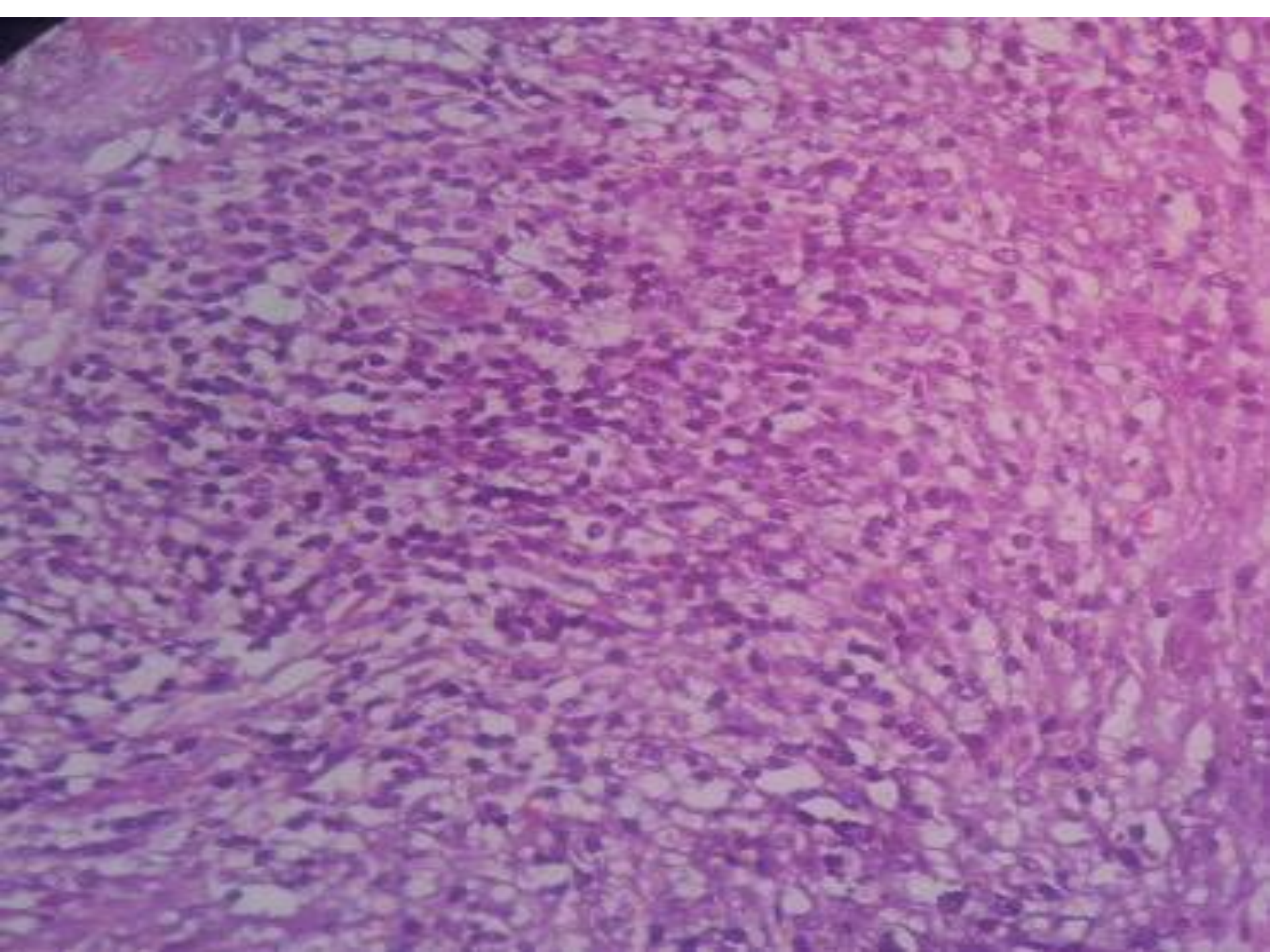


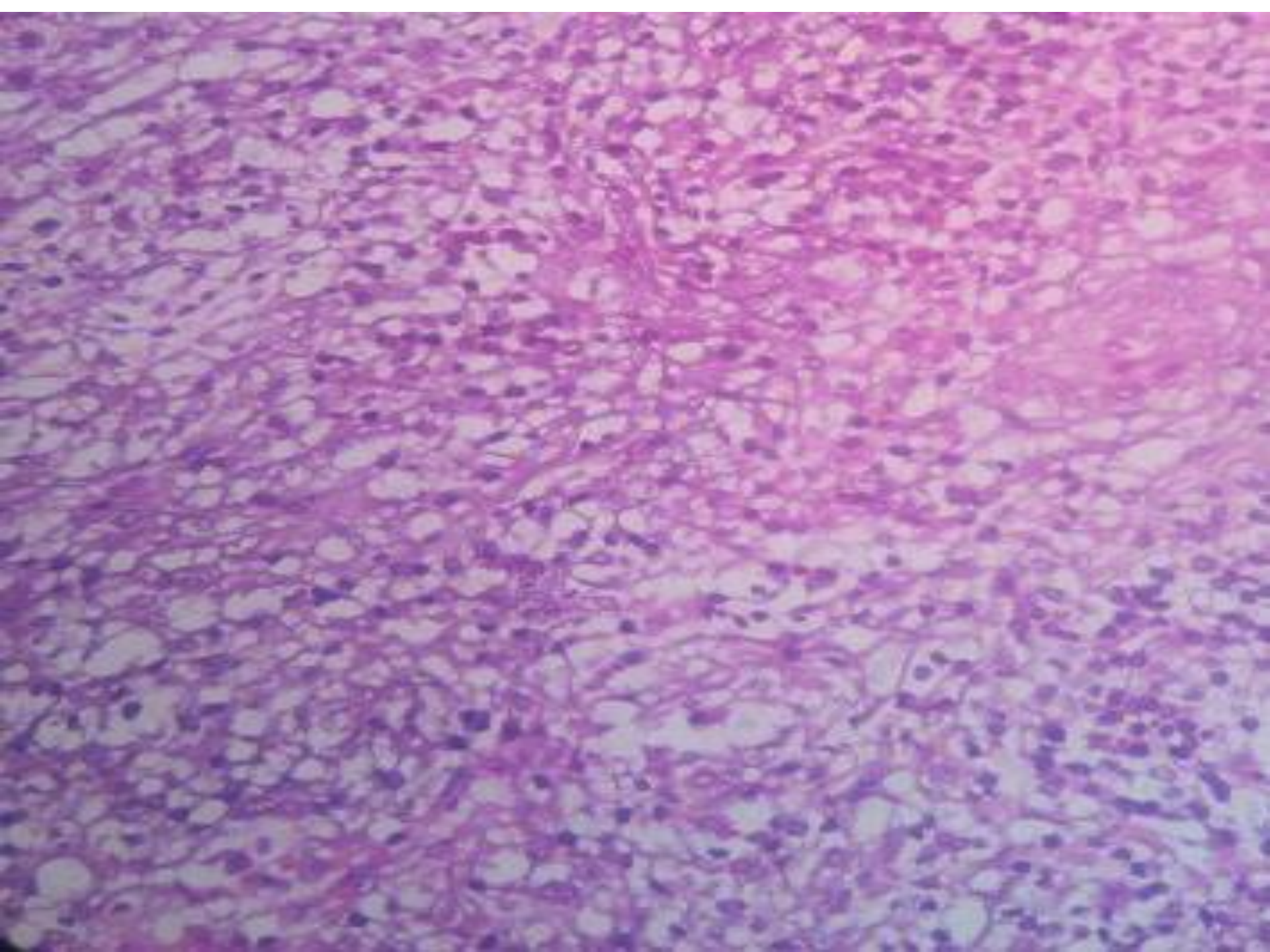


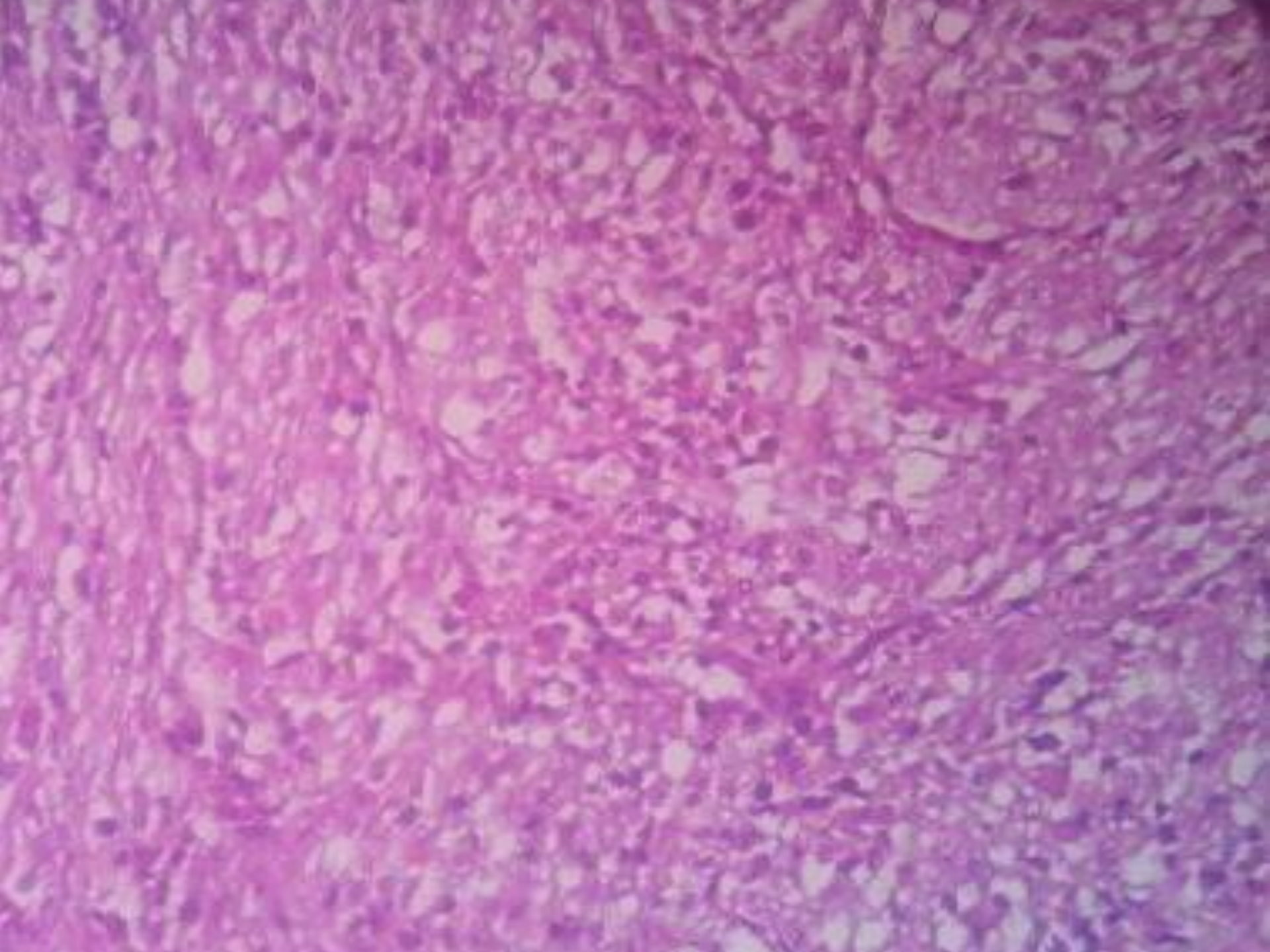
- 6 Y.M intra-abdominal mass.











Thank you