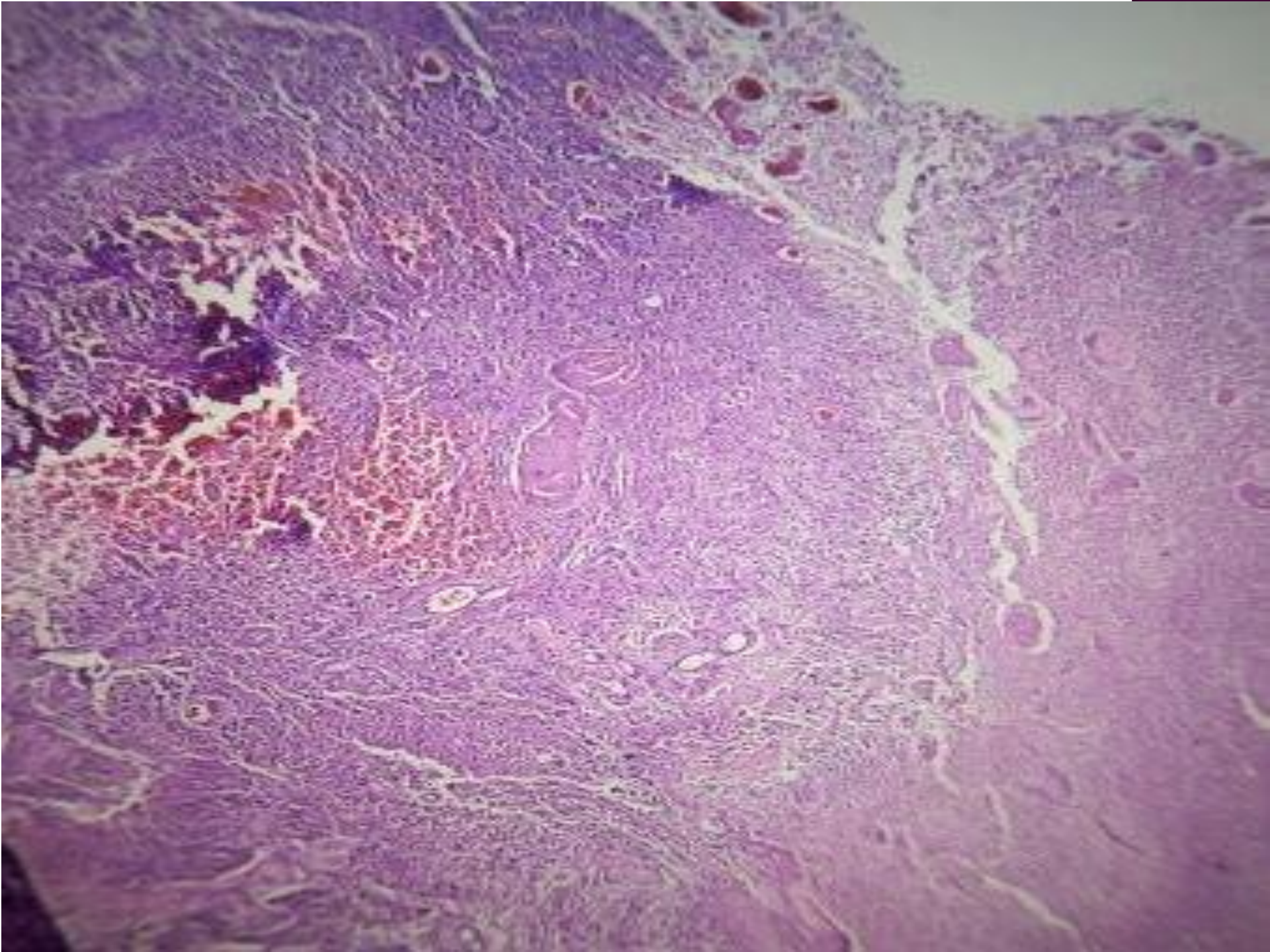
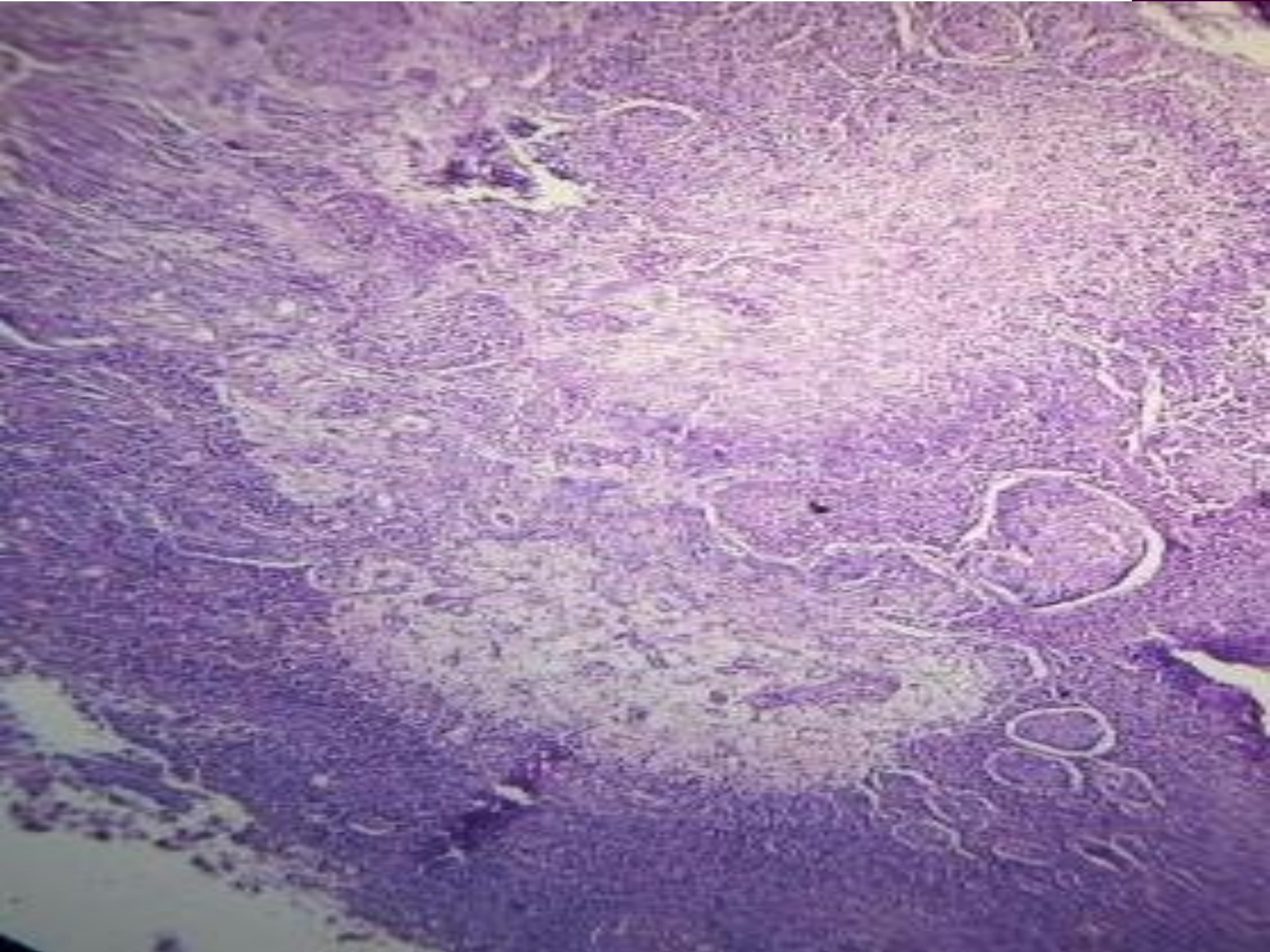
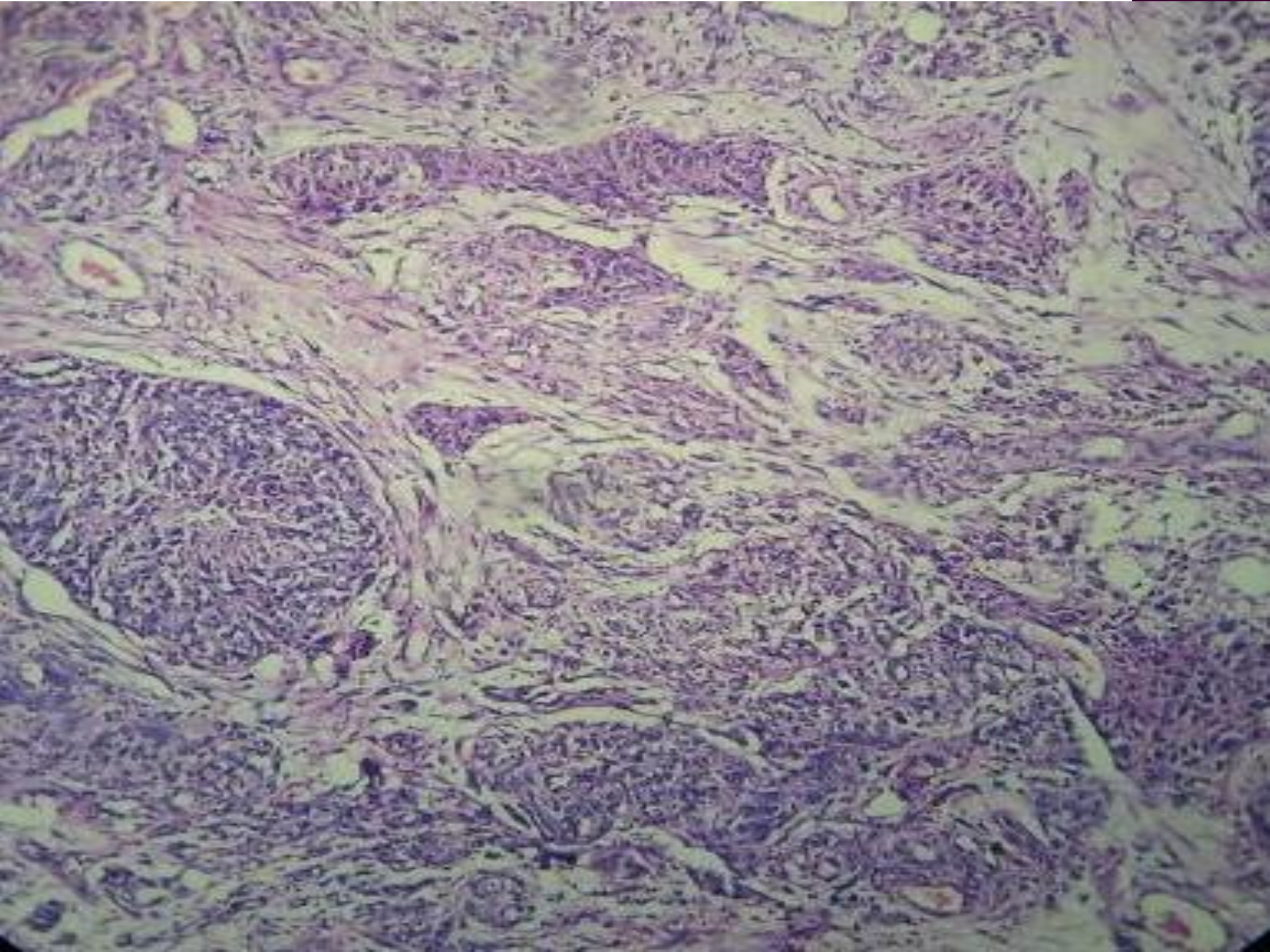


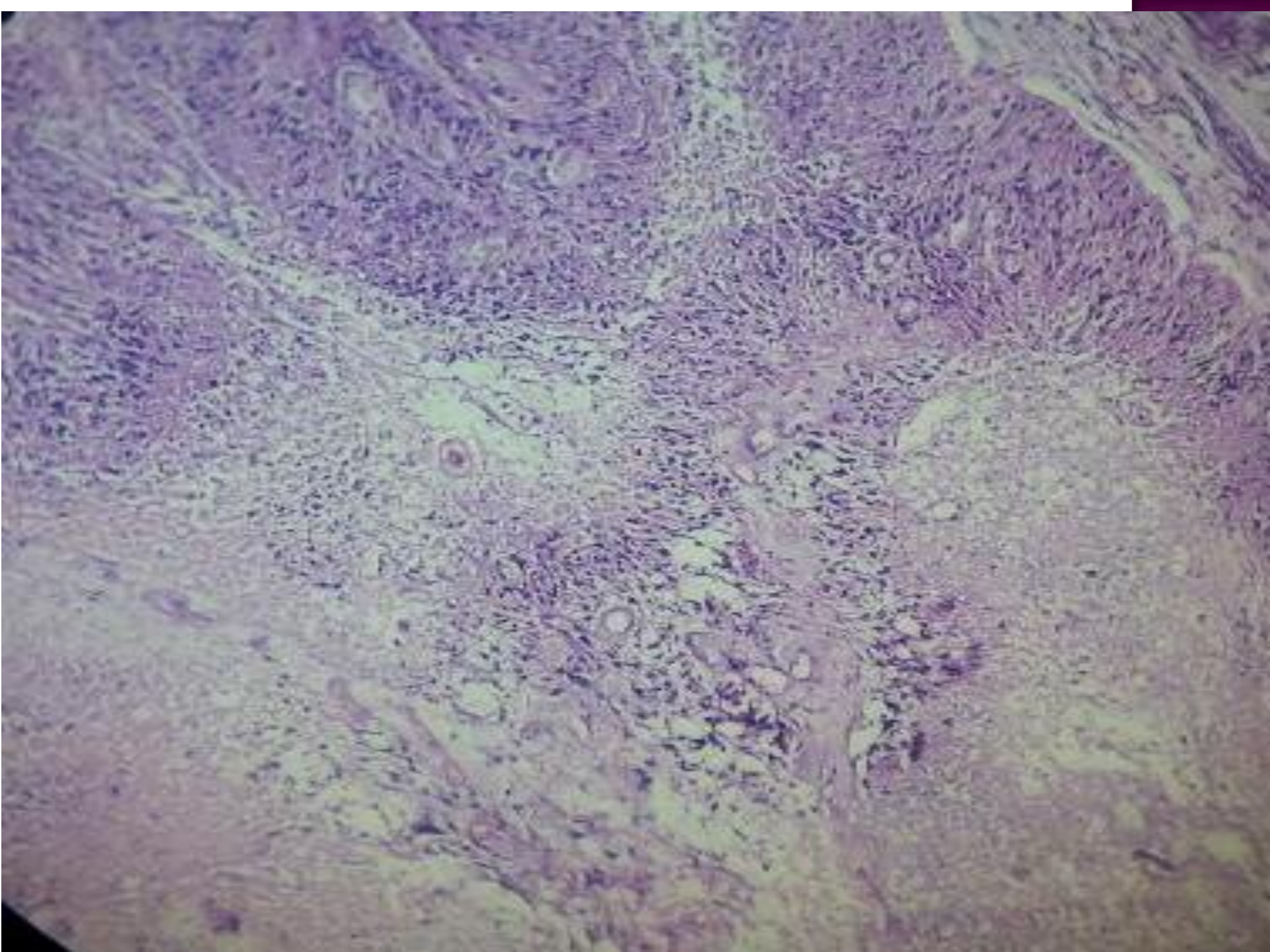
3RD SLIDE MEETING

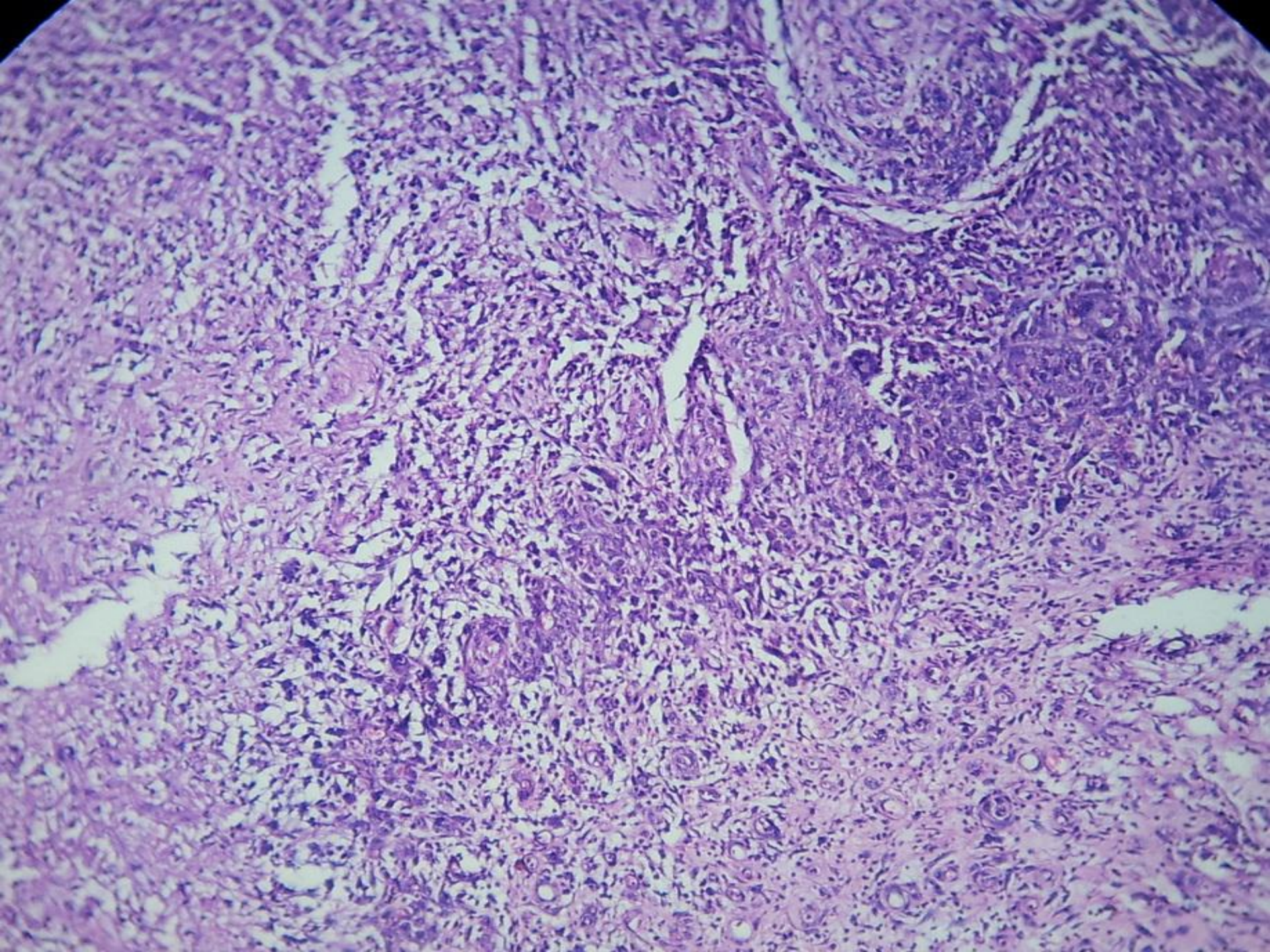
◎ 48 Y.F. brain tumor

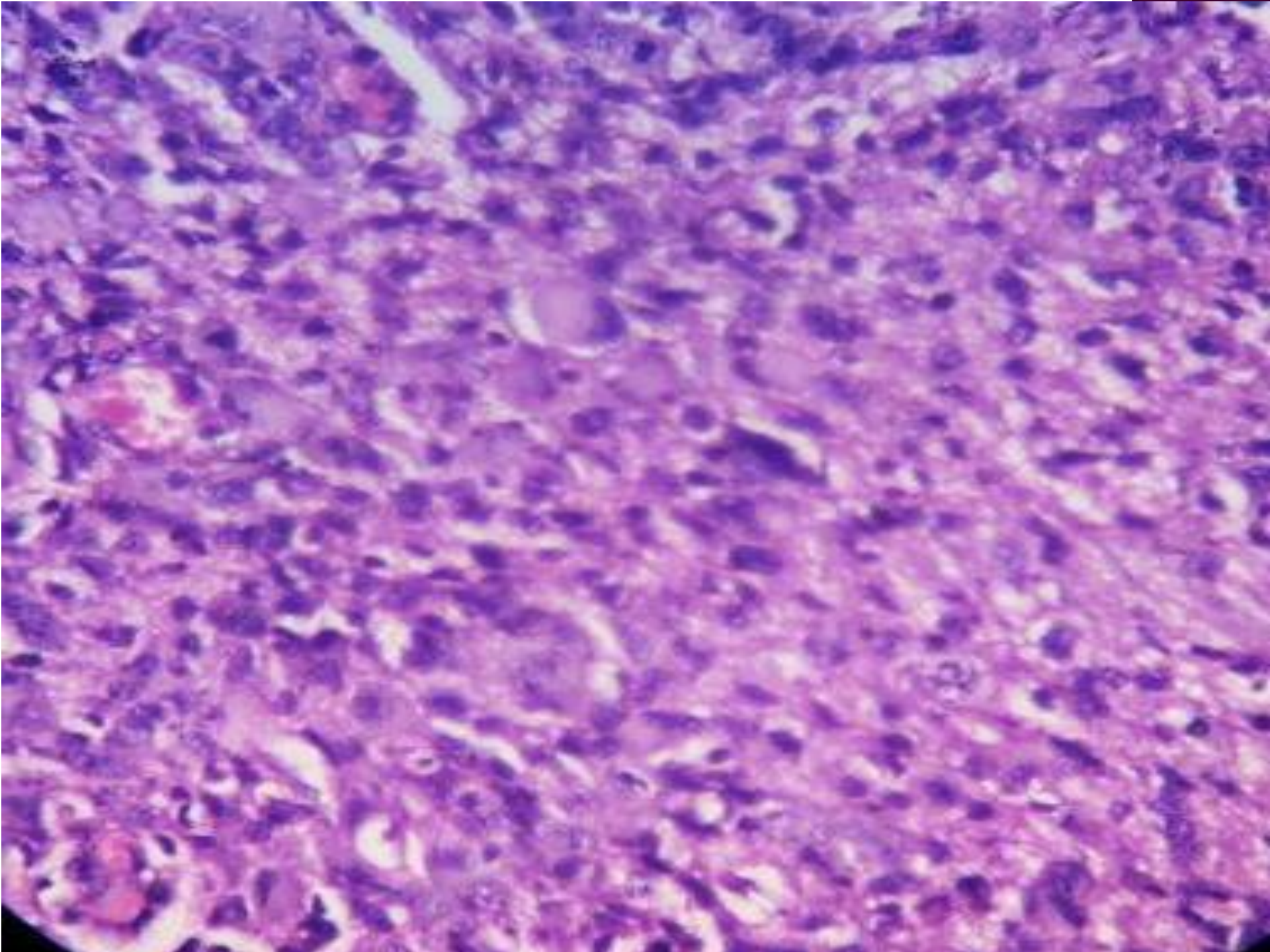


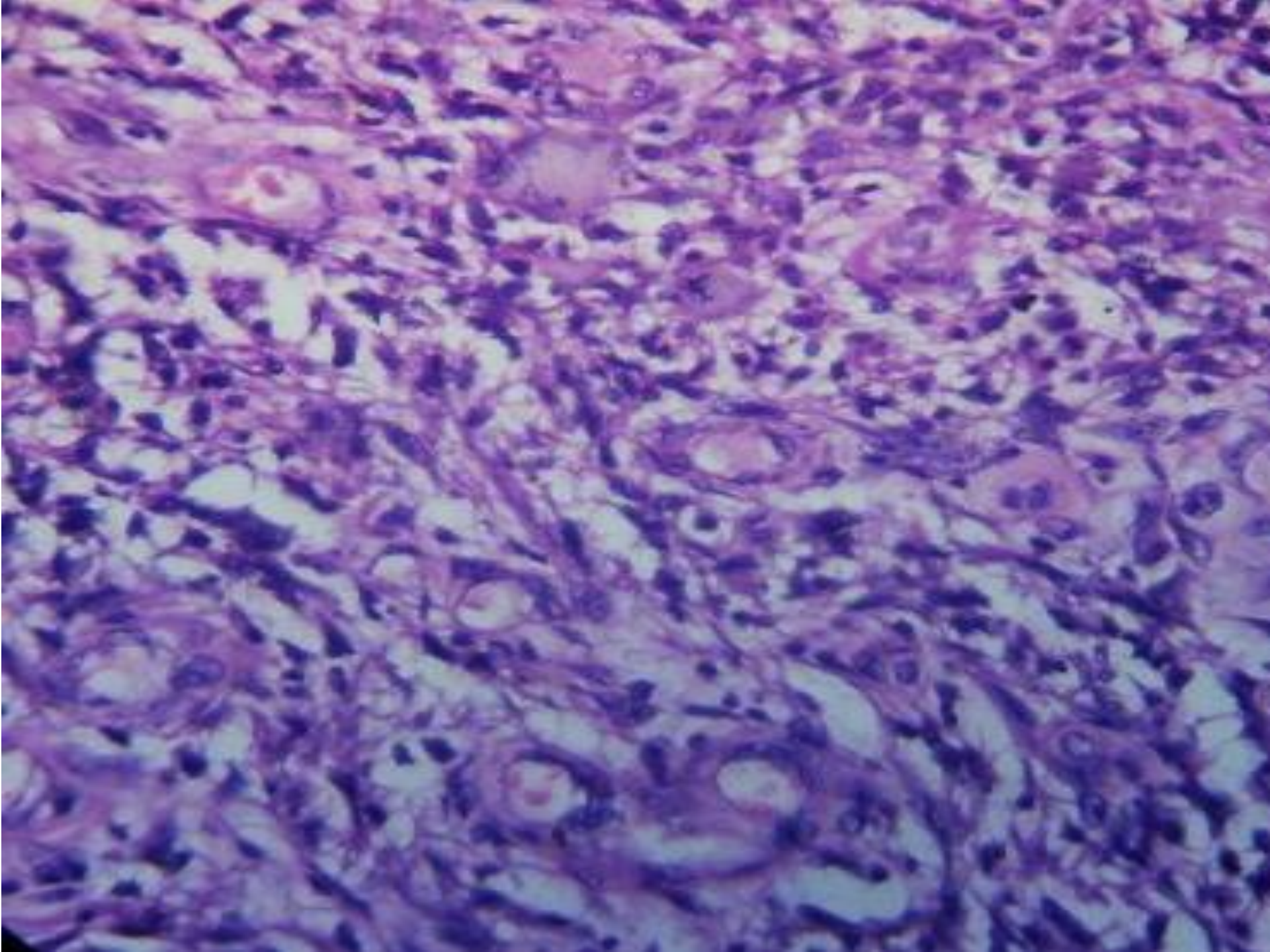




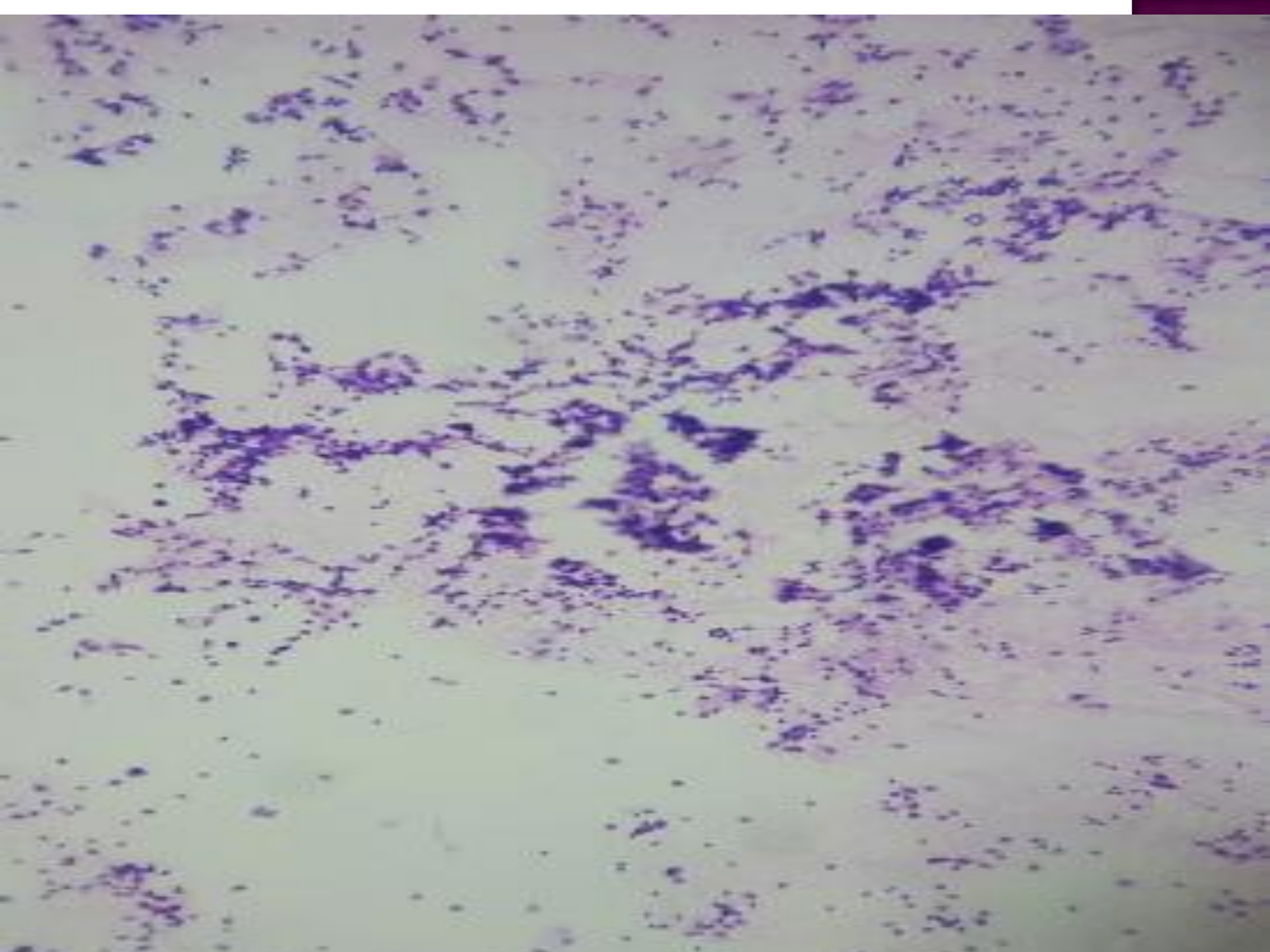


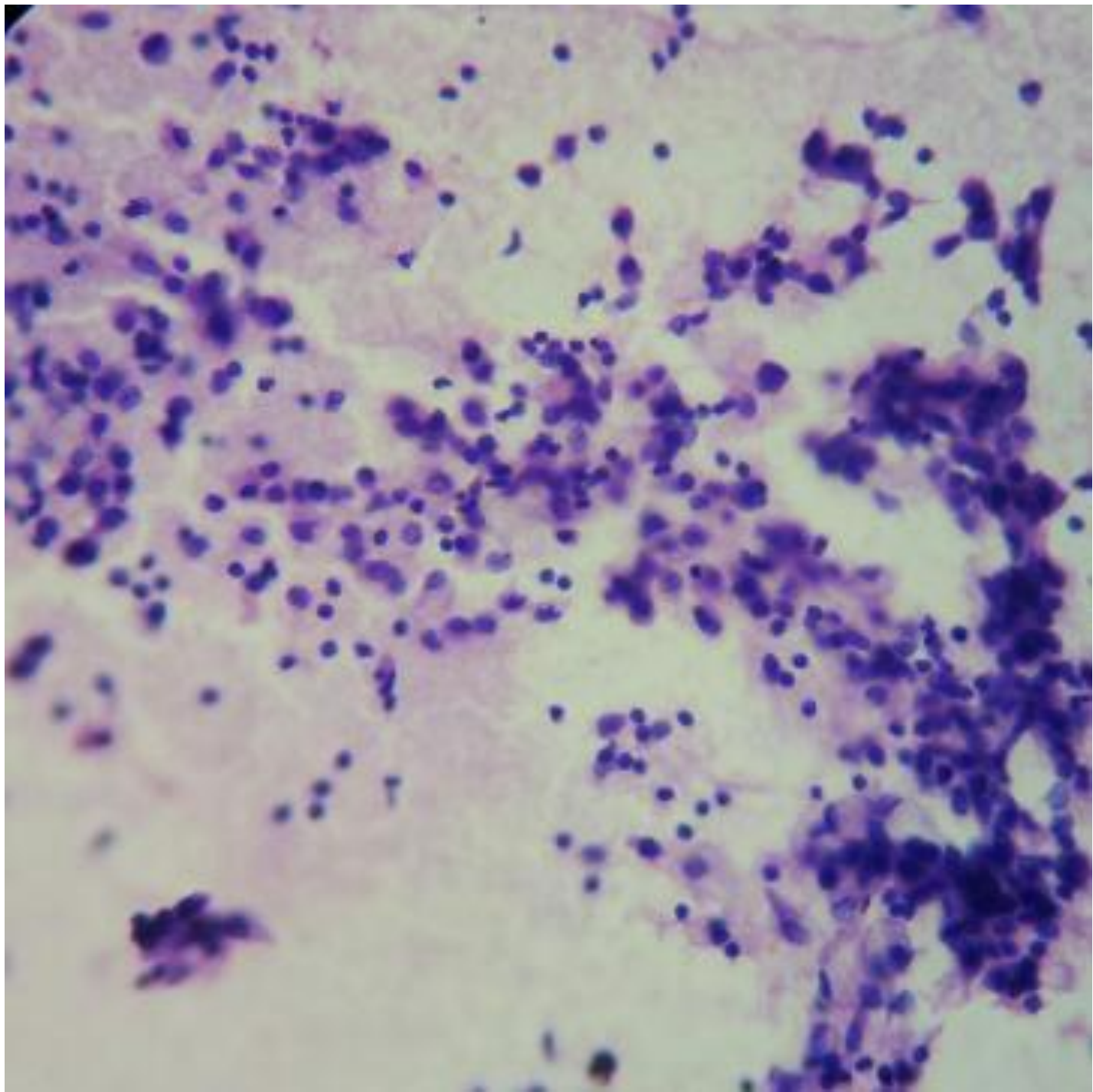




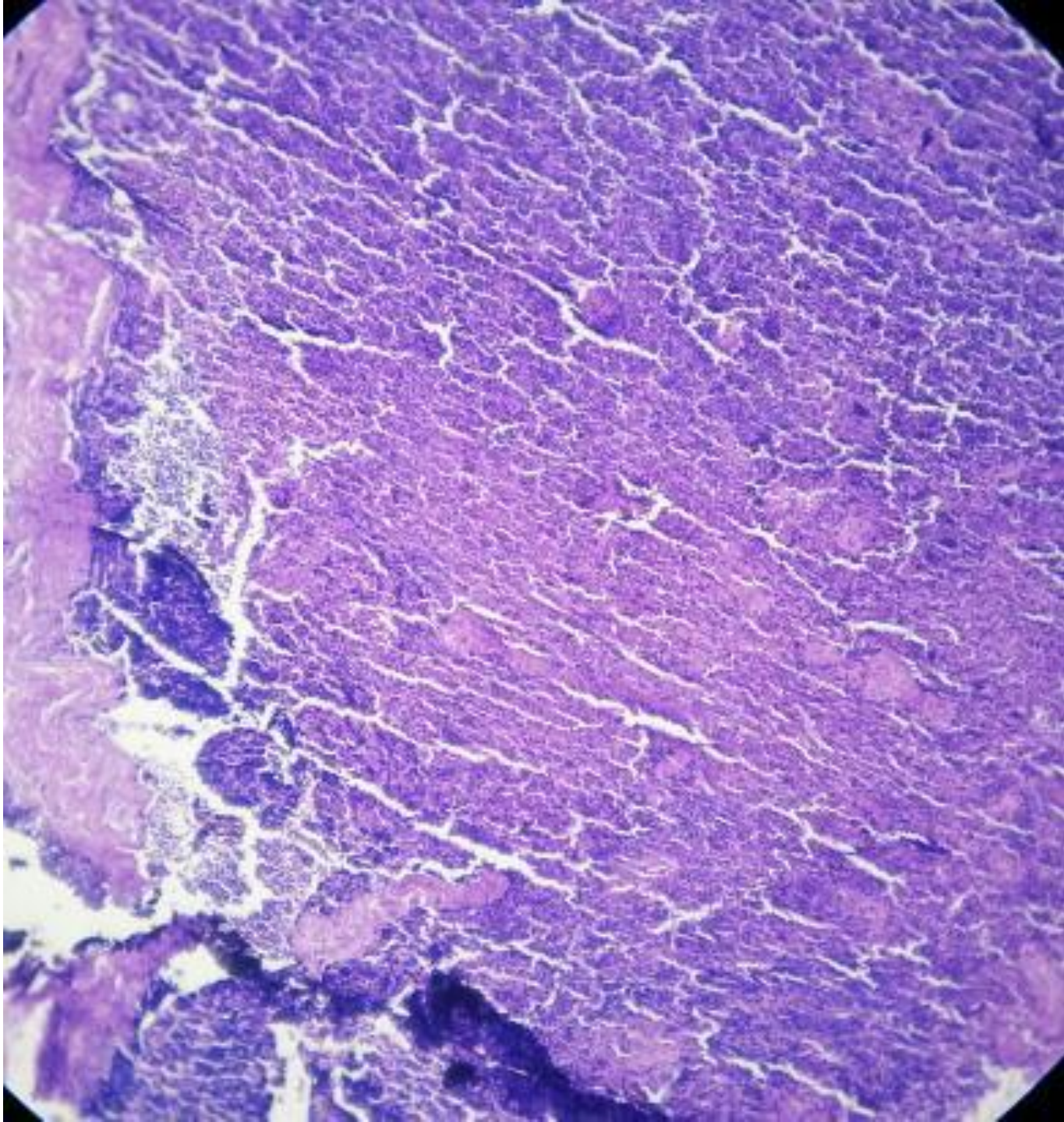


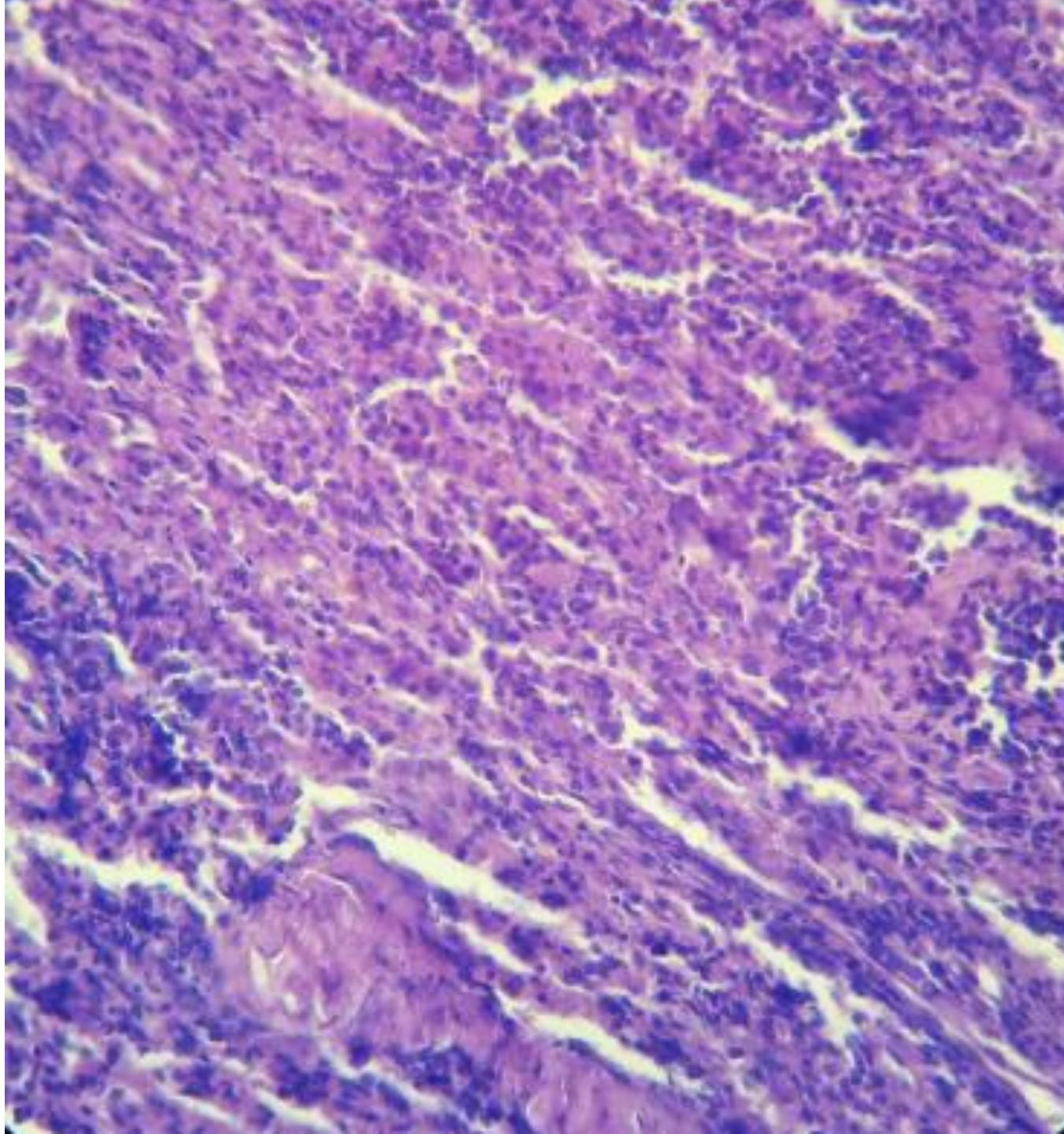
◎ 45 Y.F with Pleural effusion.(cytology)

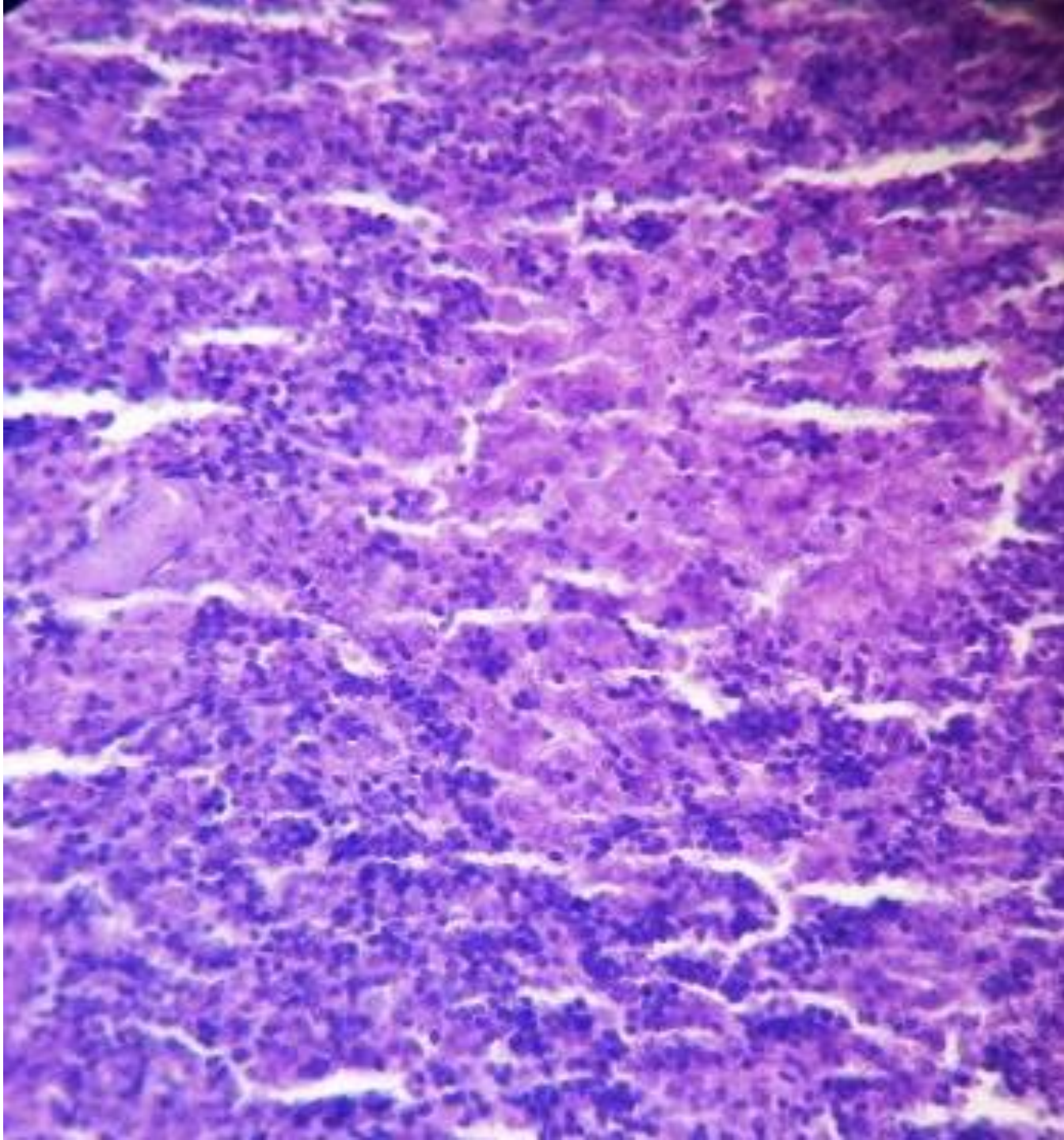




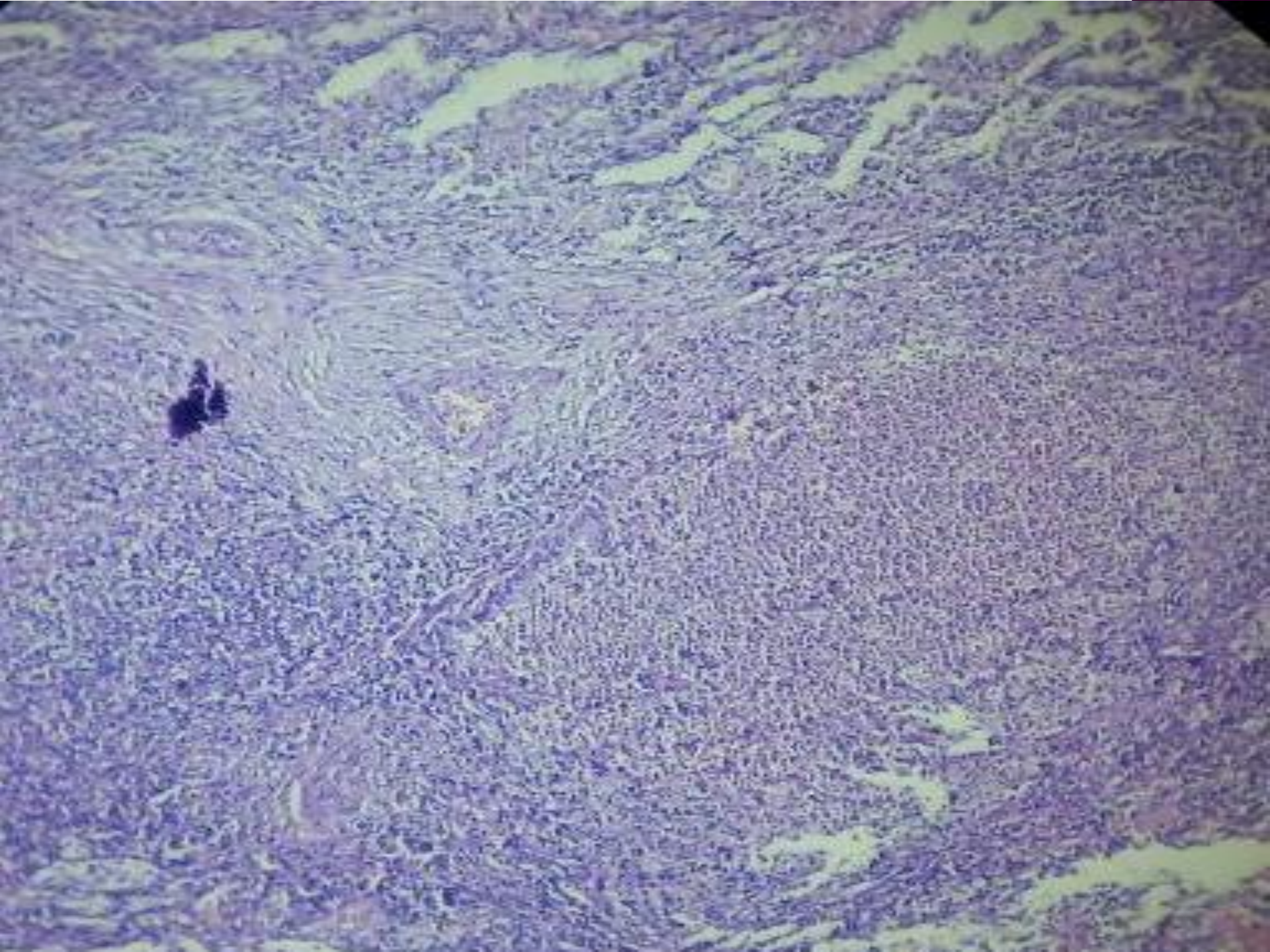
17 Y.M. cervical lymphadenopathy.

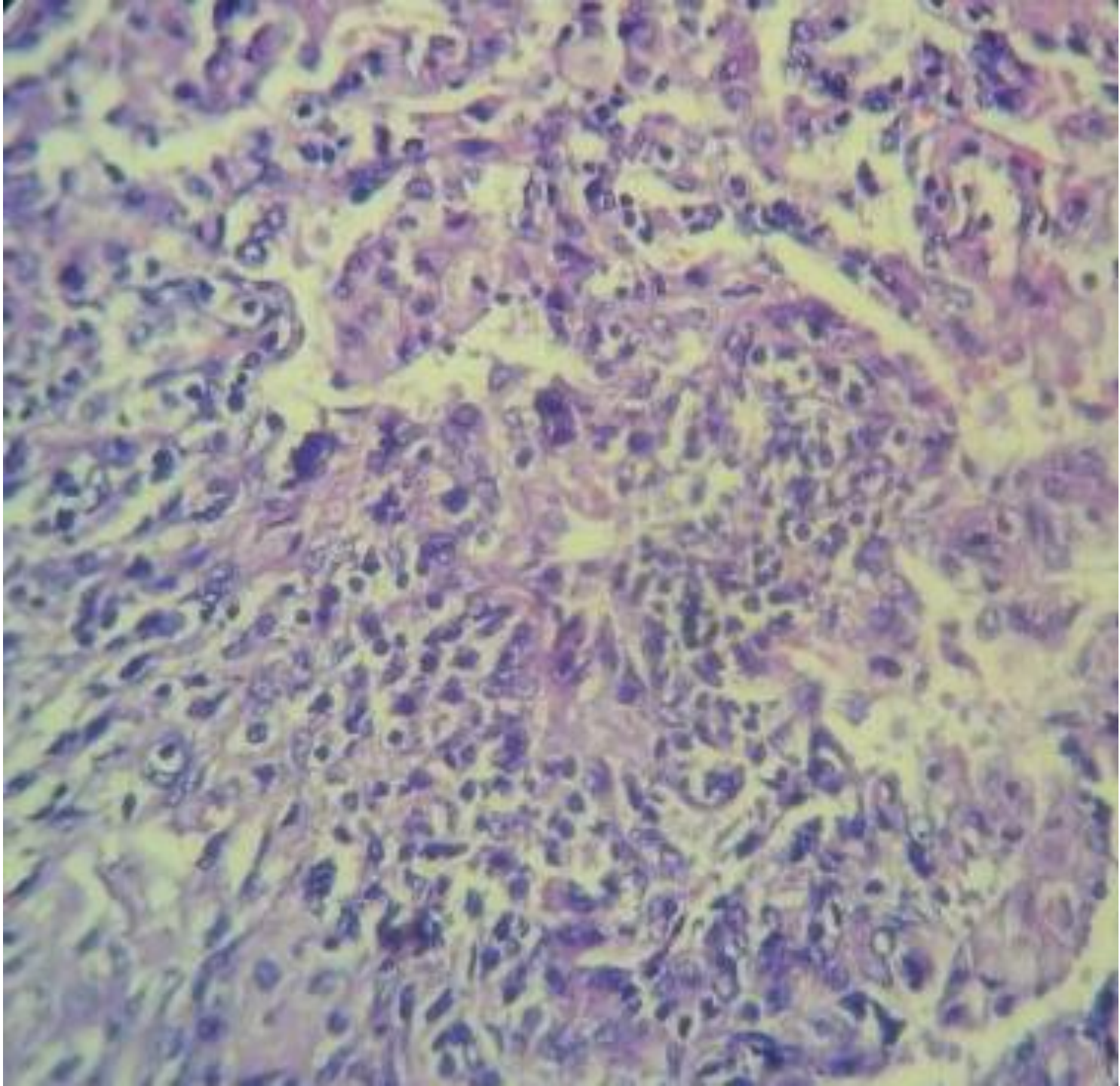


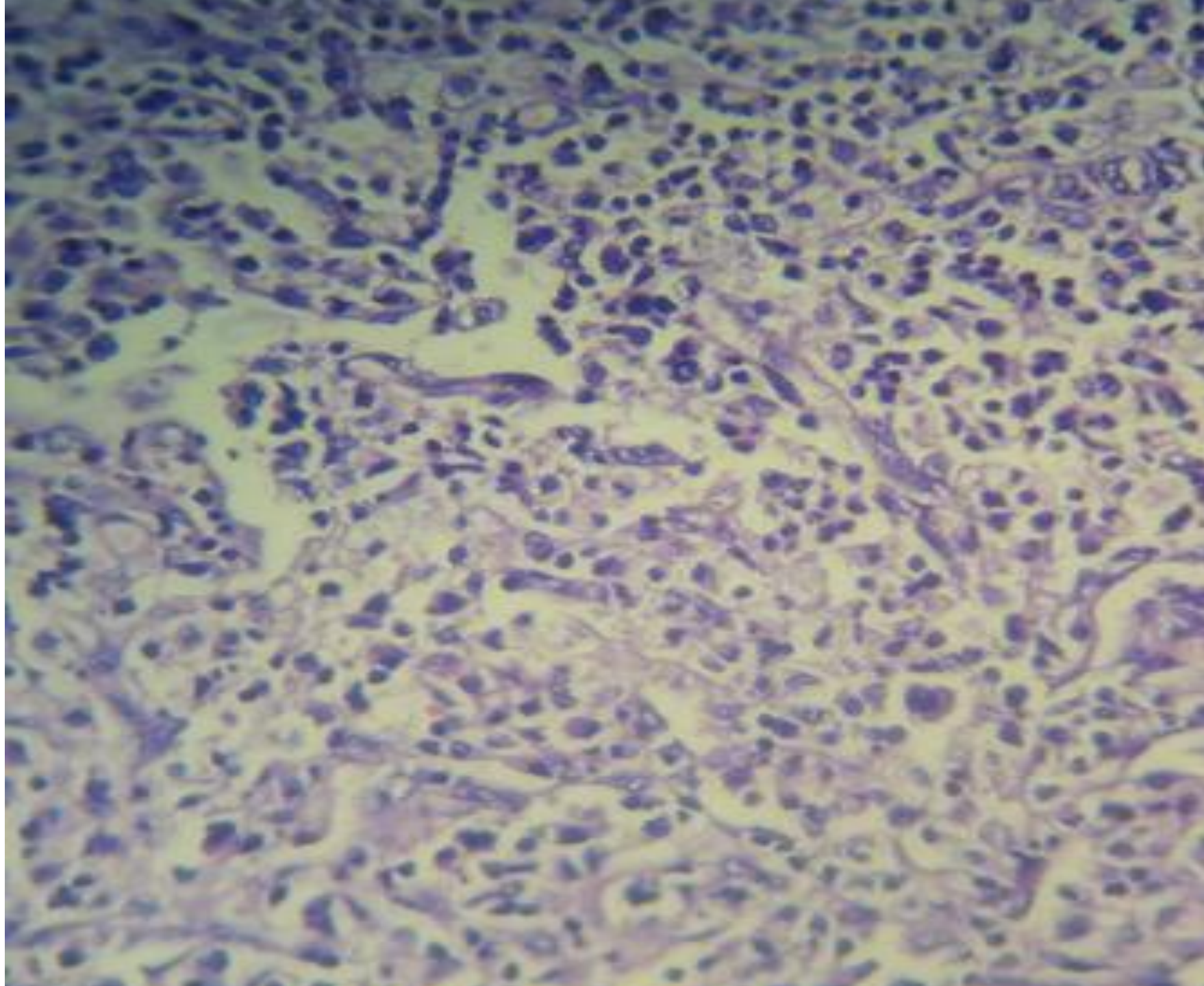




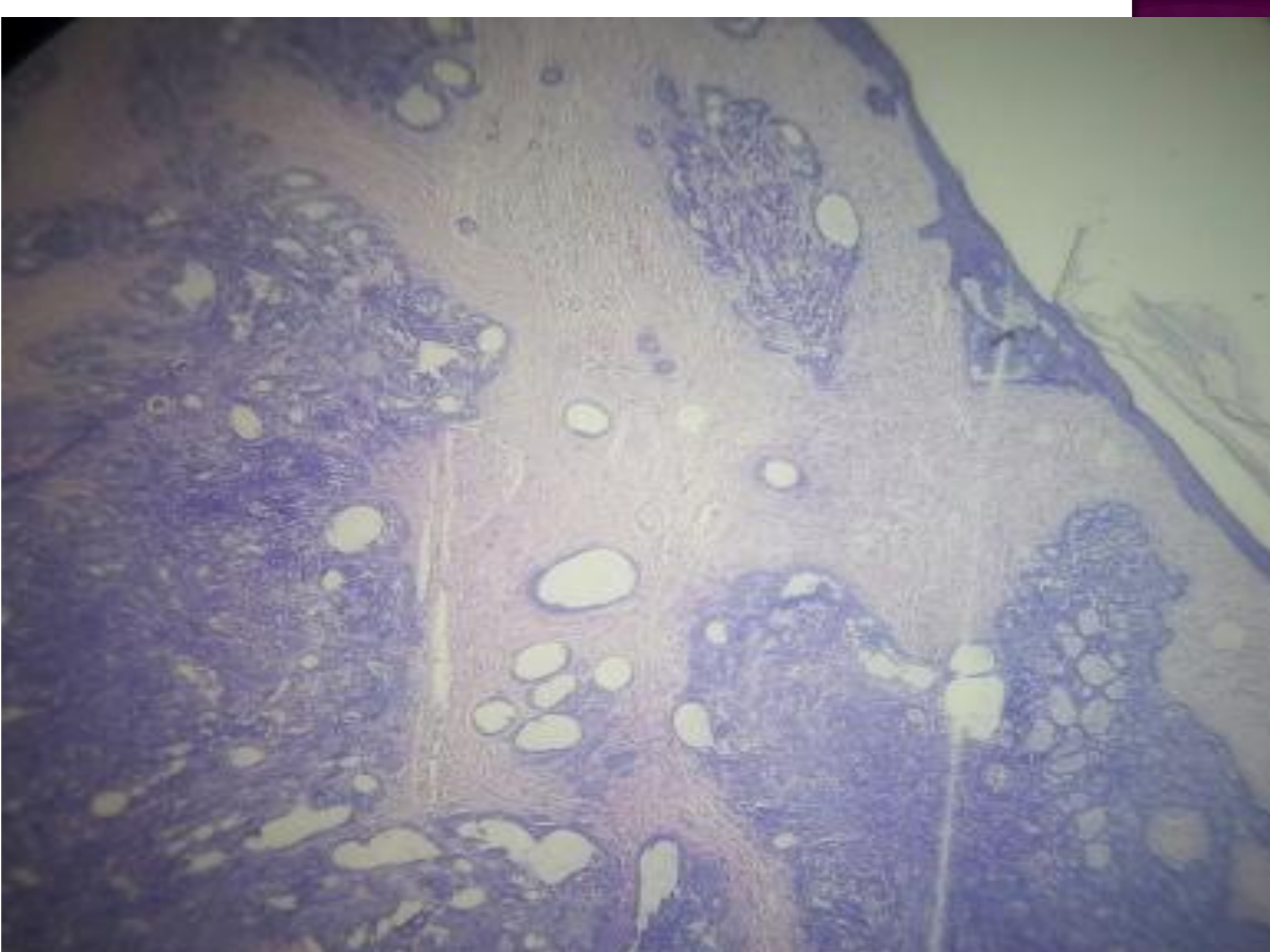
- ⦿ **11 Y.M with PUO and Rt. lung lobe collapse.**

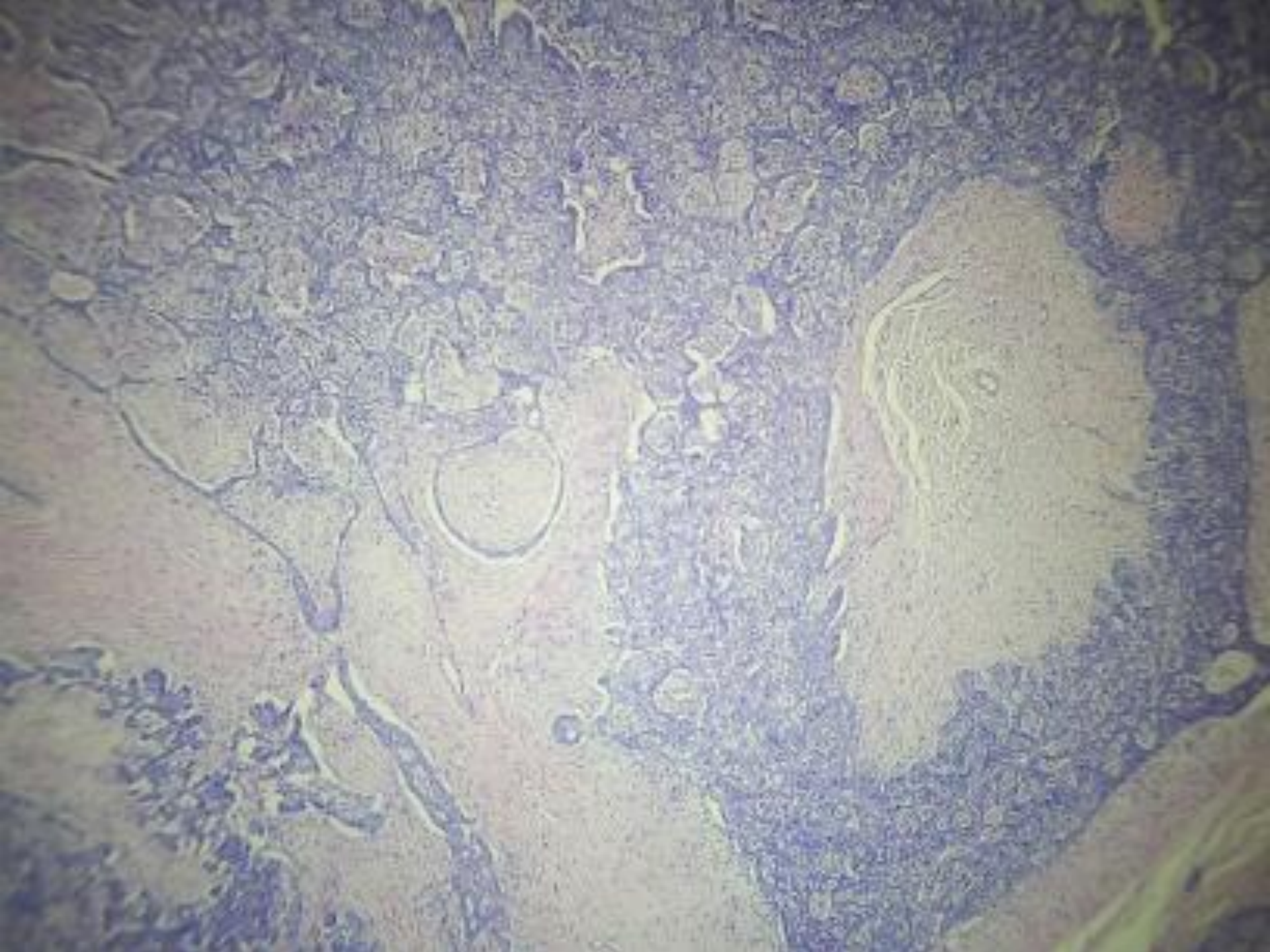


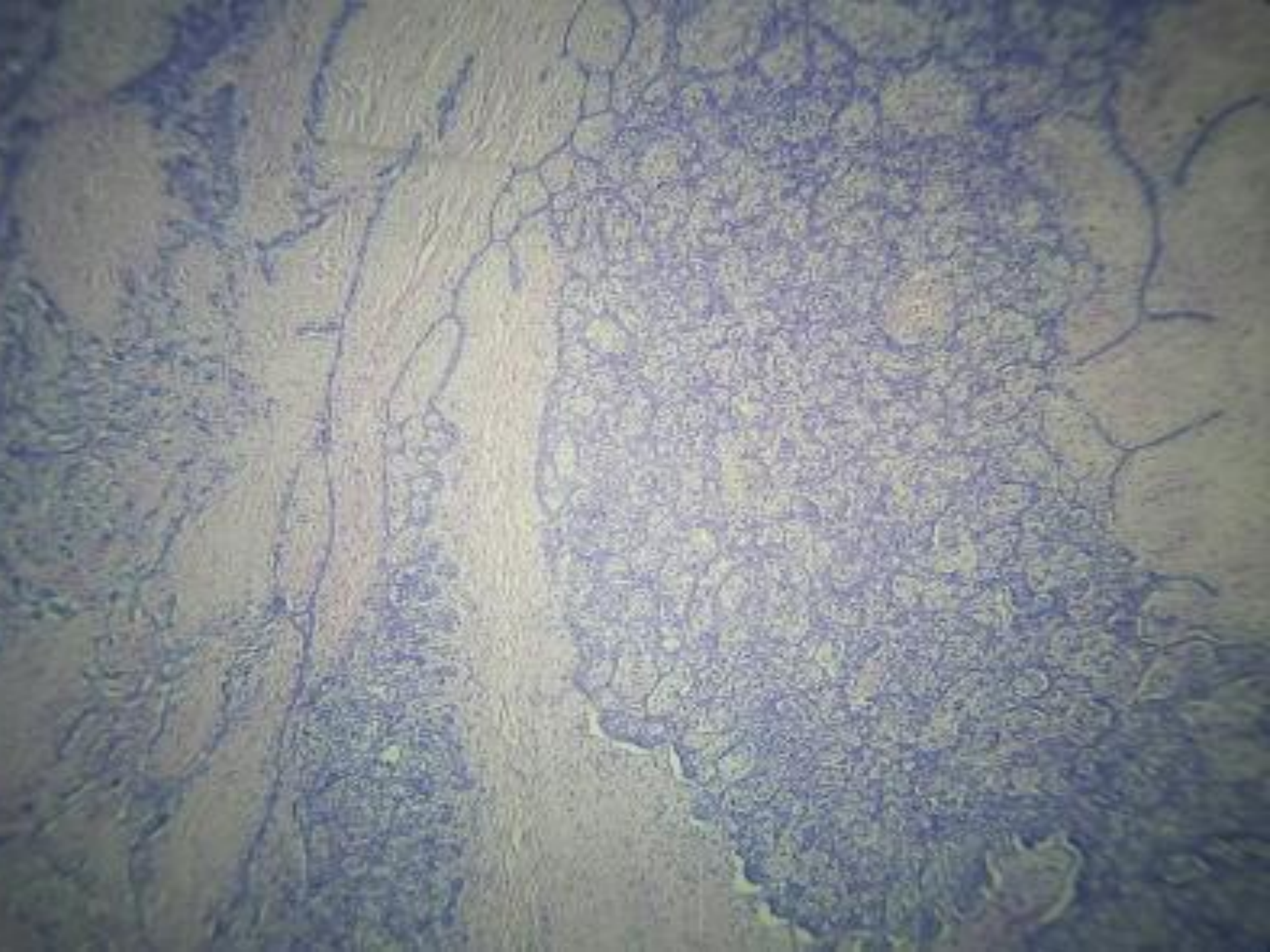


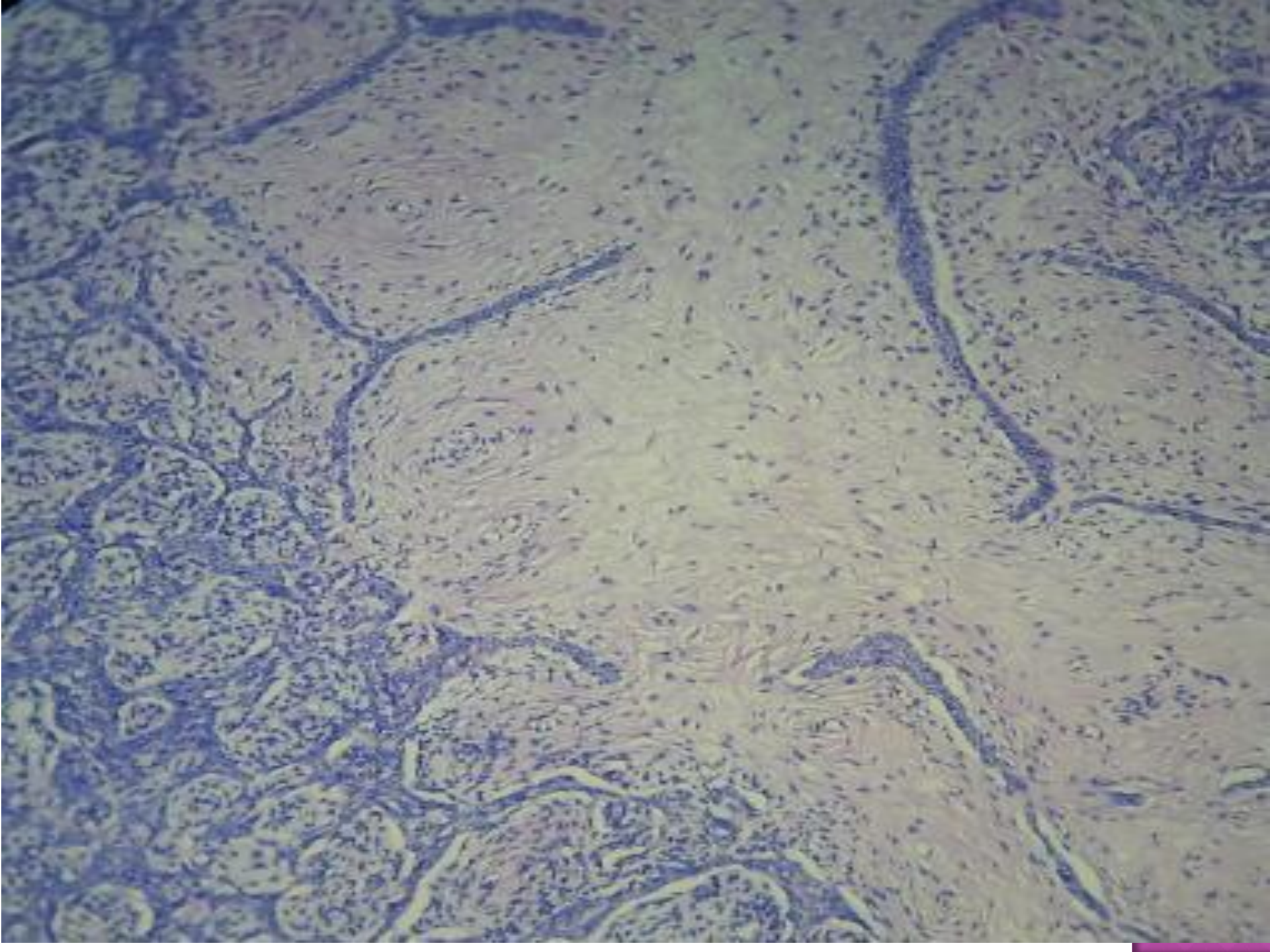


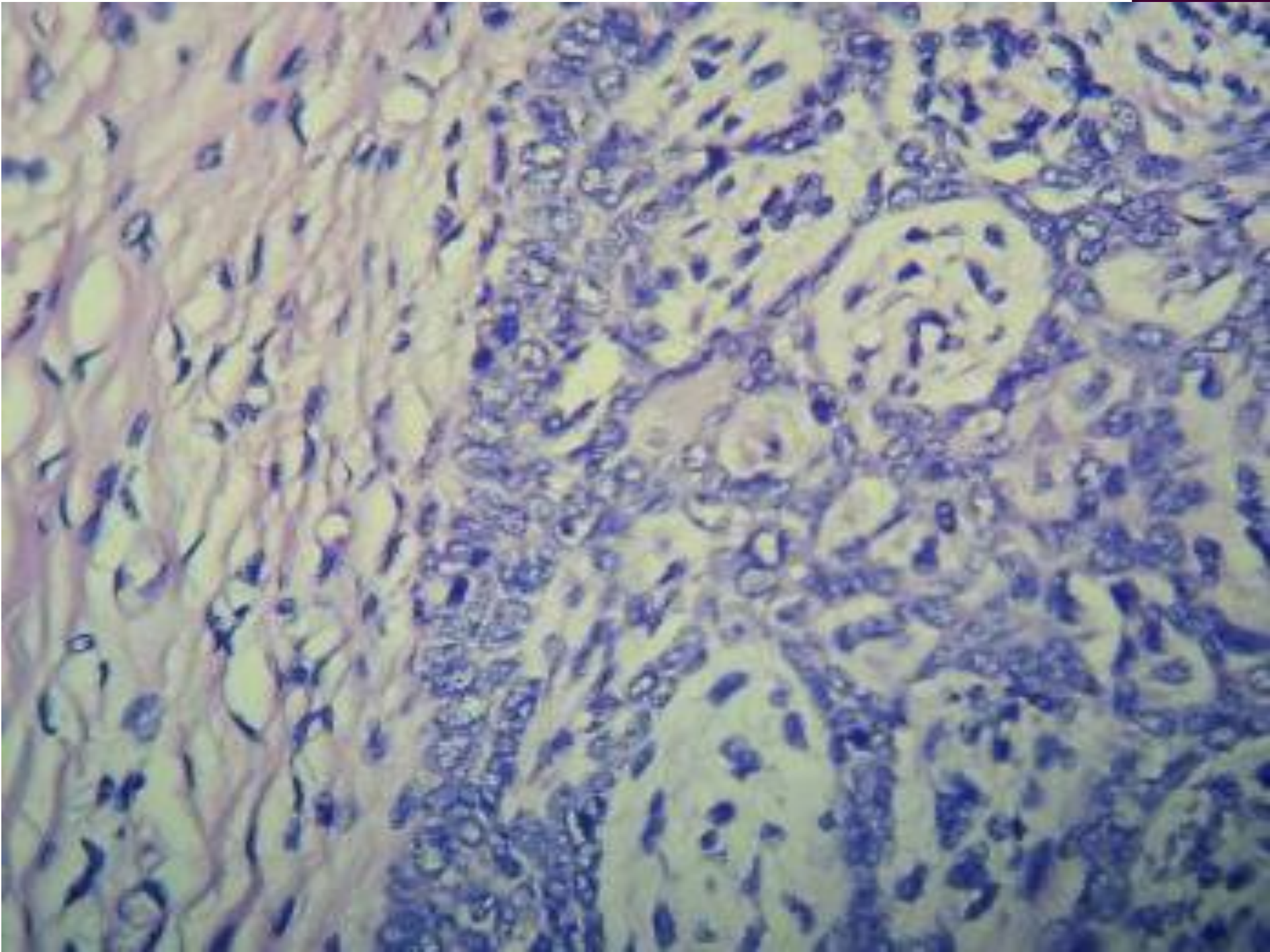
- 30 Y.M skin lesion near the knee joint.











THANK
YOU

