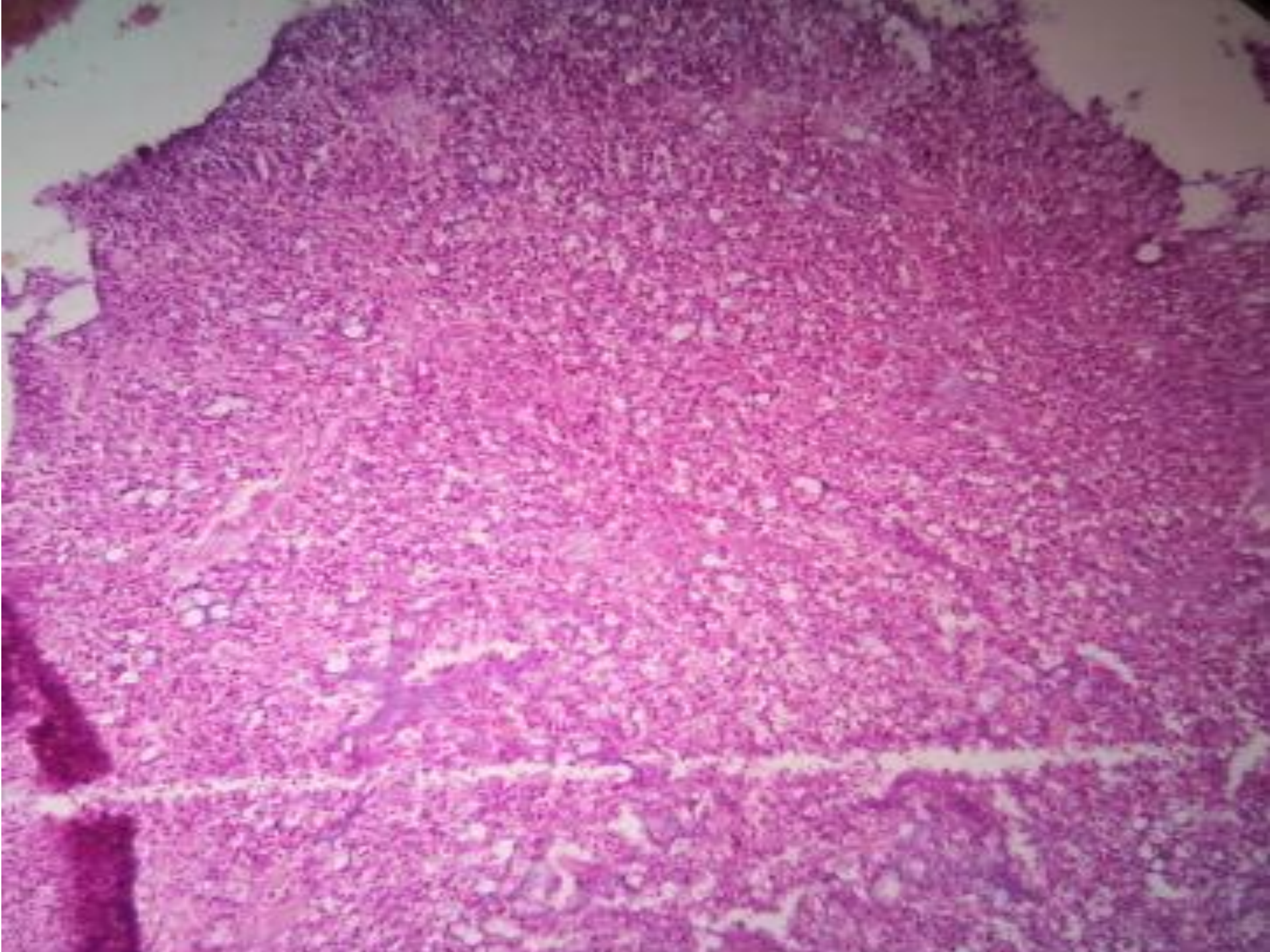
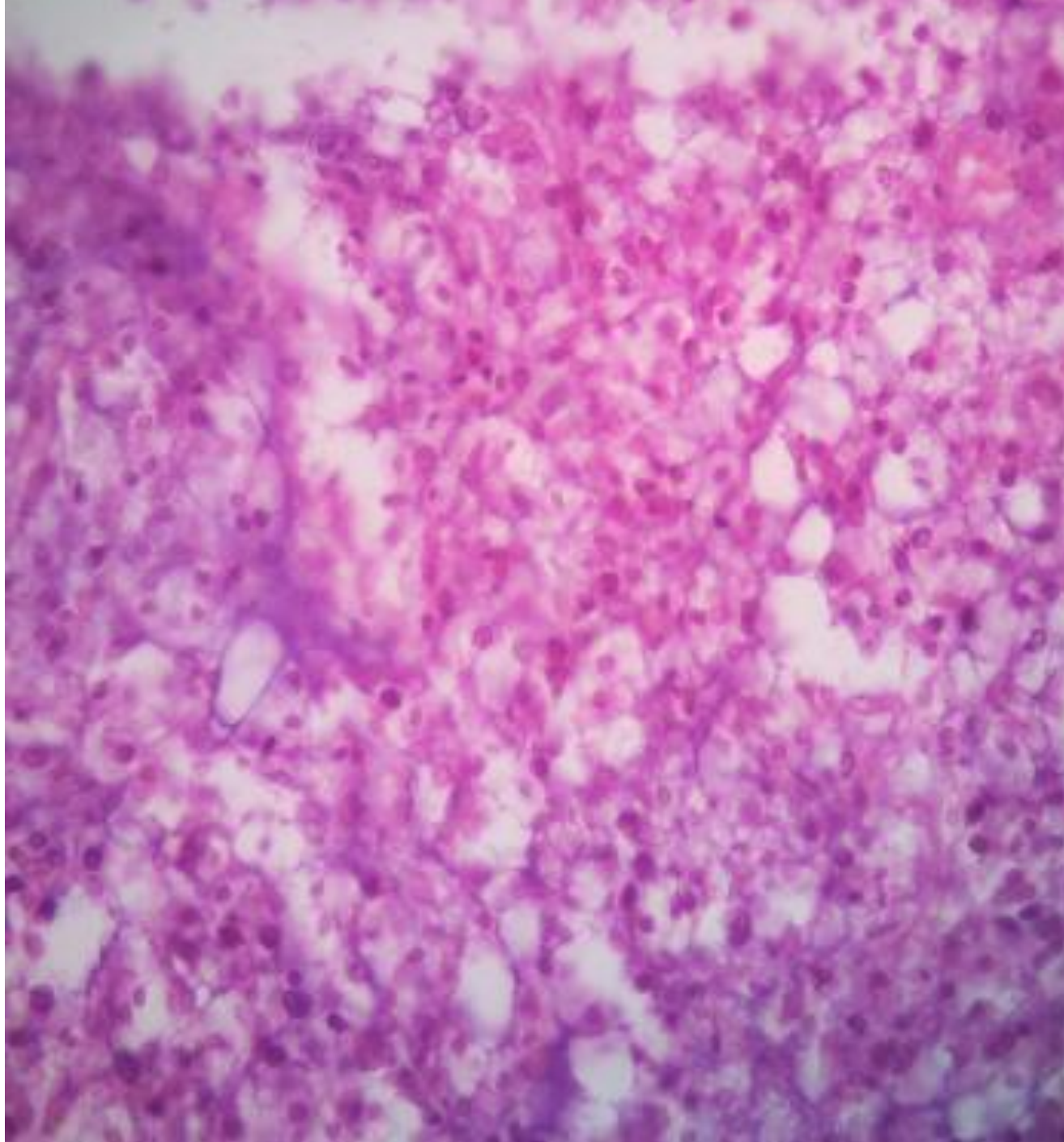
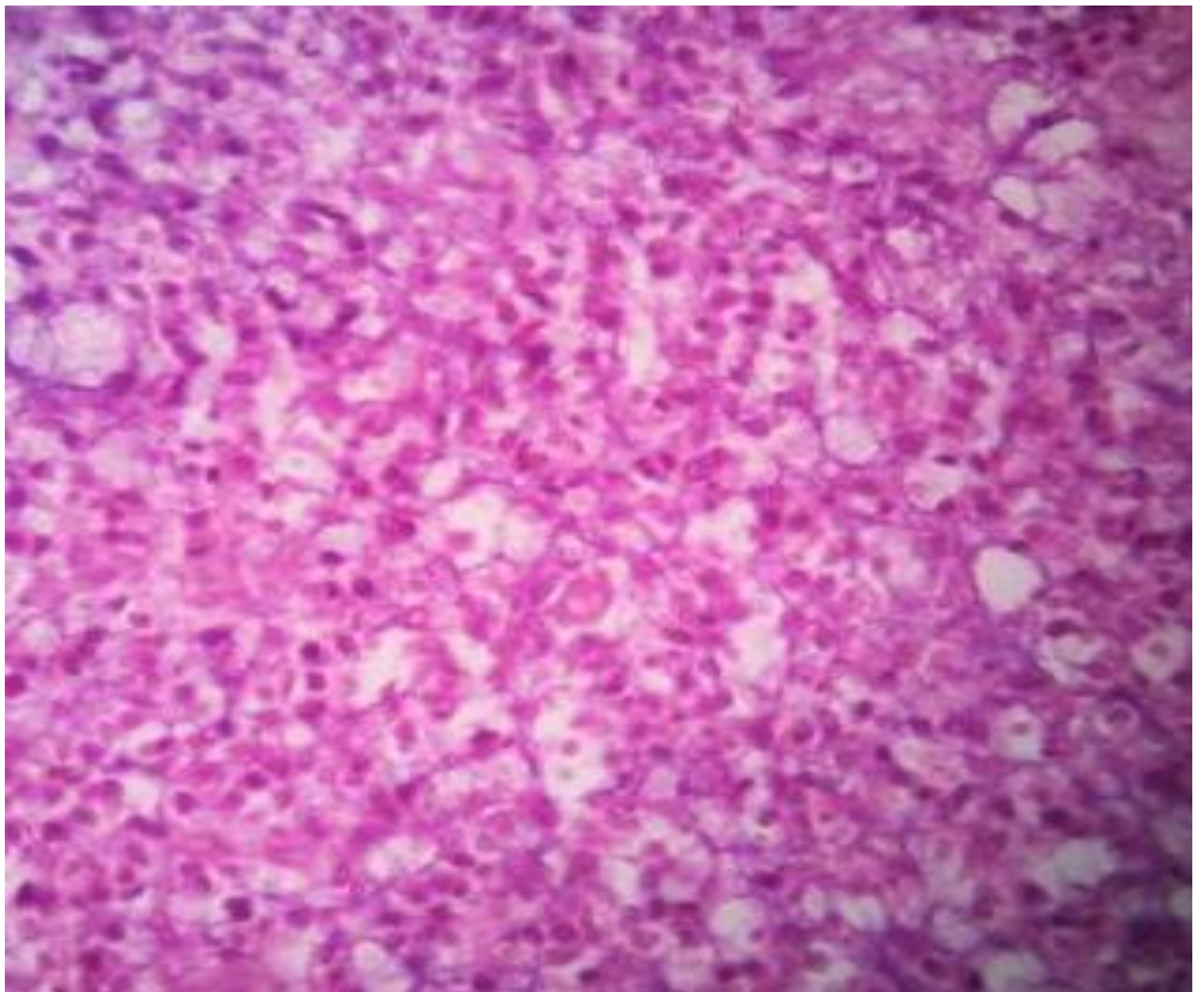


# 6<sup>th</sup> Slide Meeting

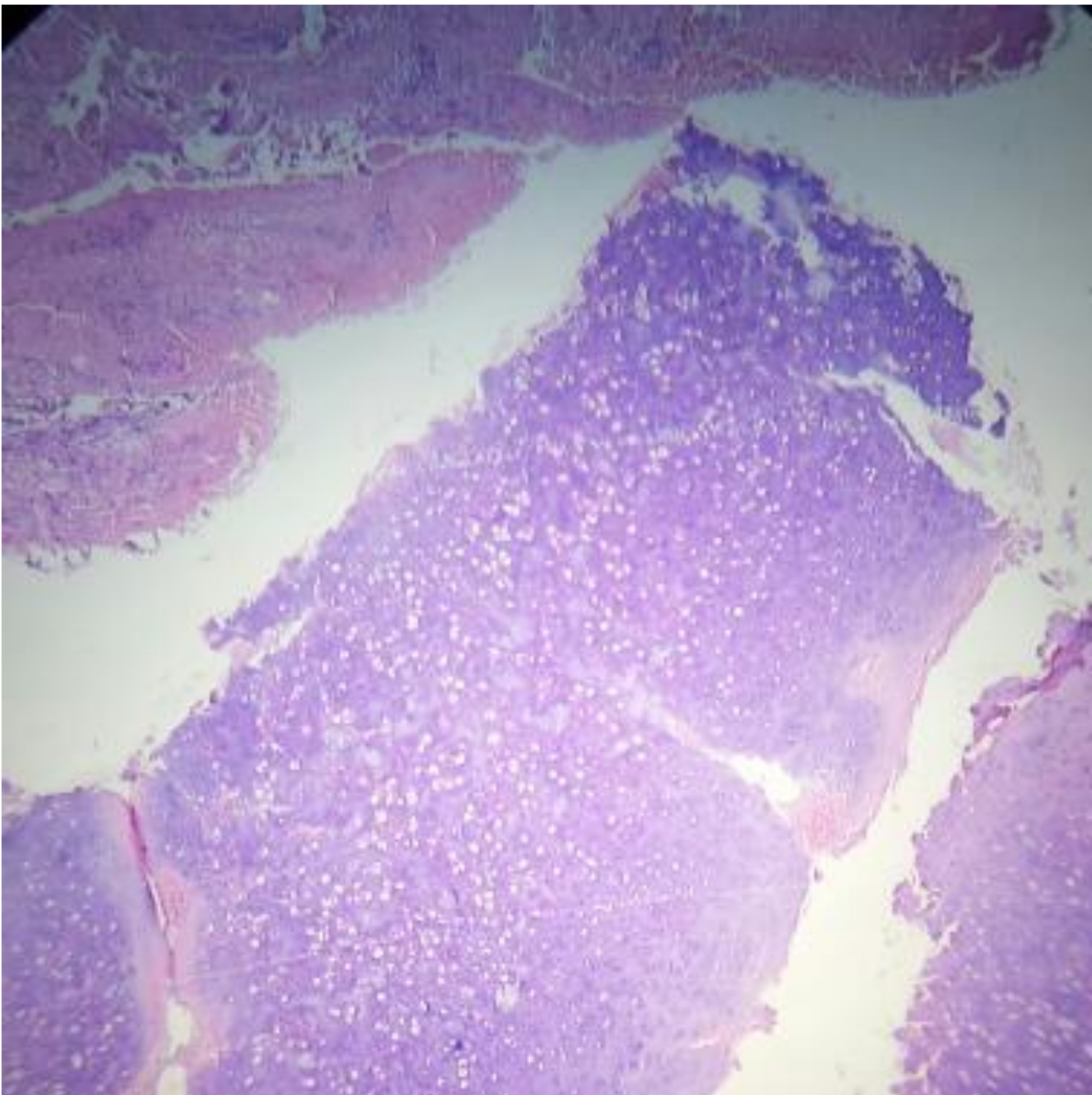
- 43 Y.F. Recurrent brain tumor in corpus callosum

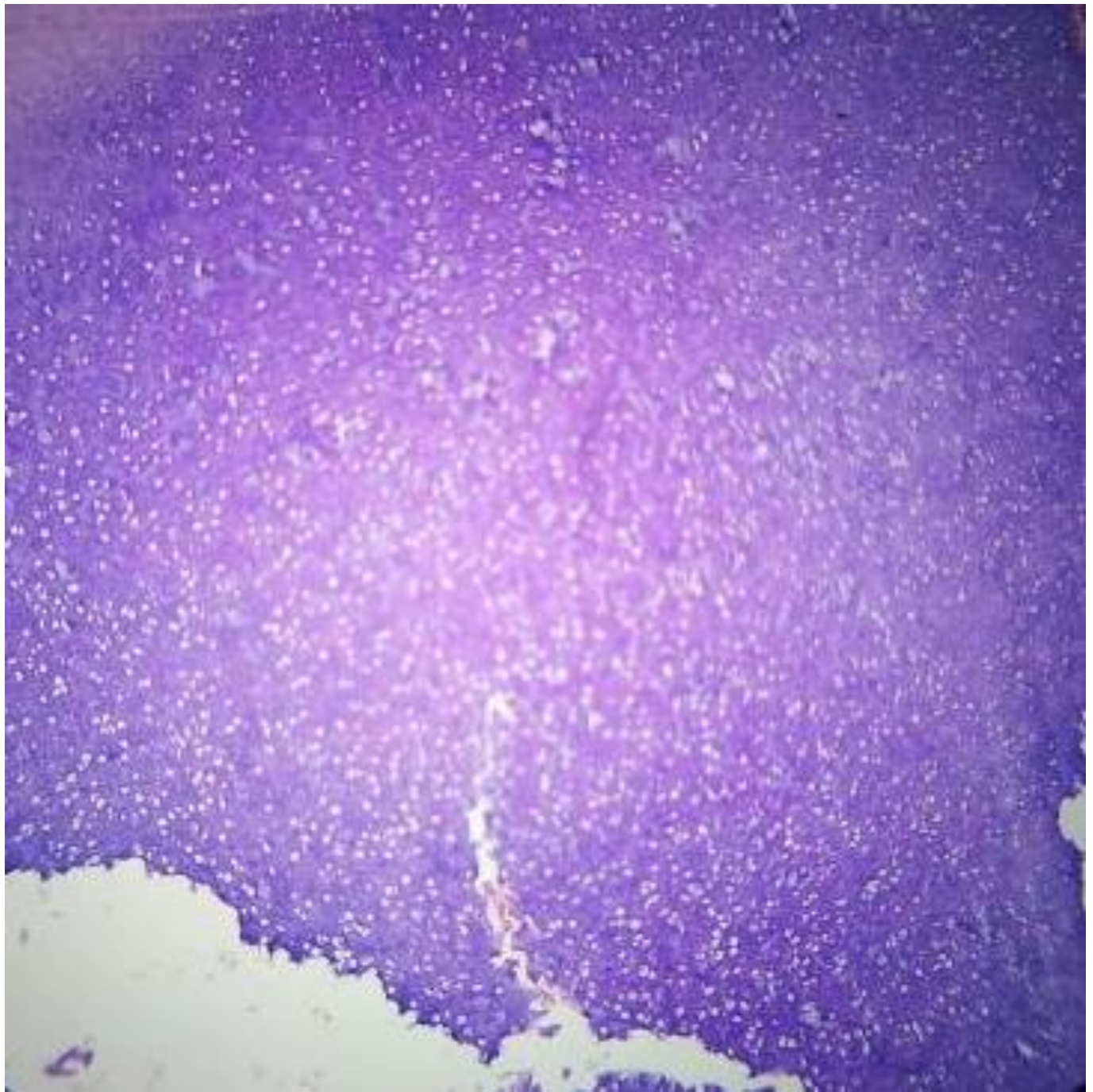




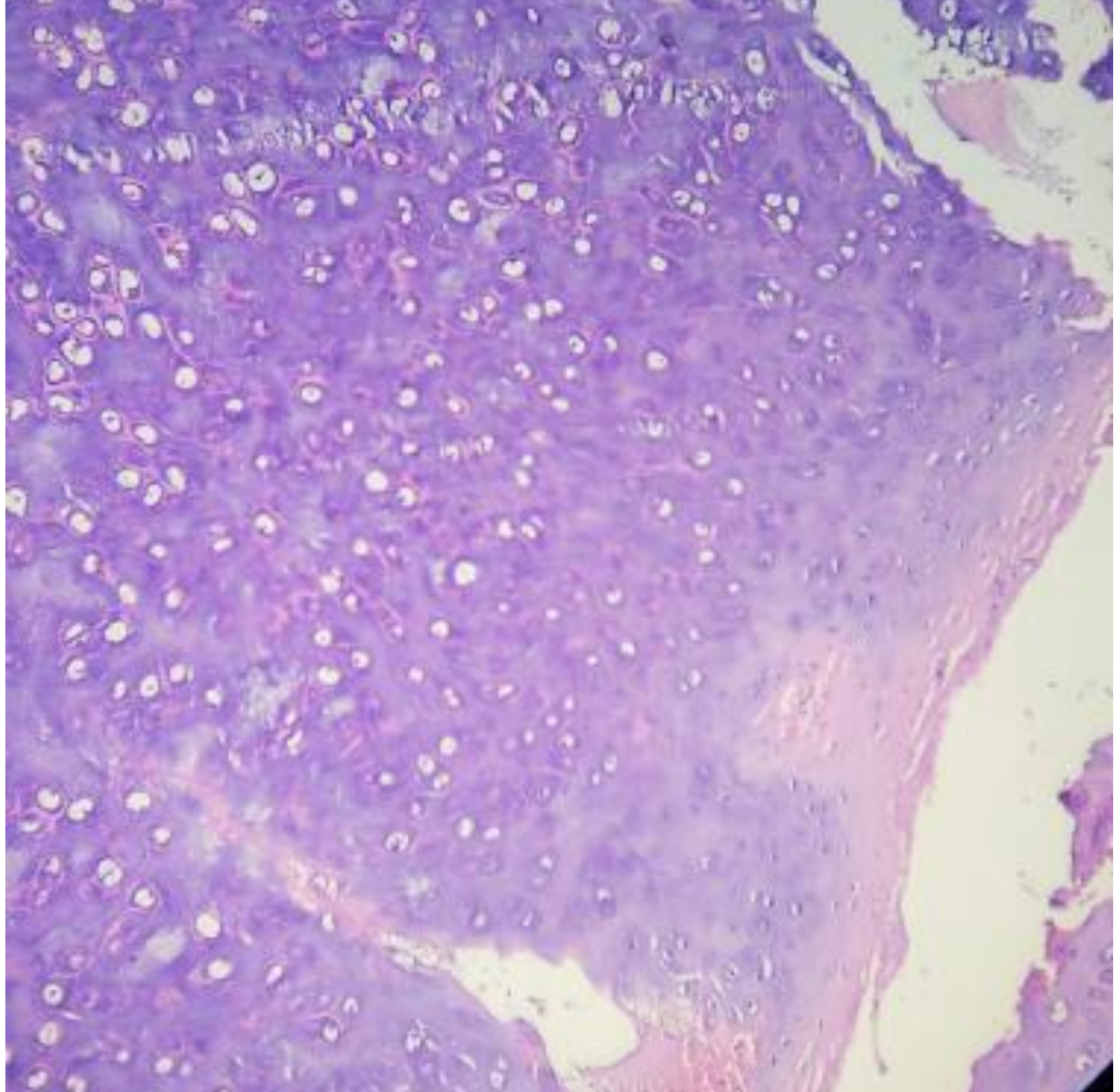


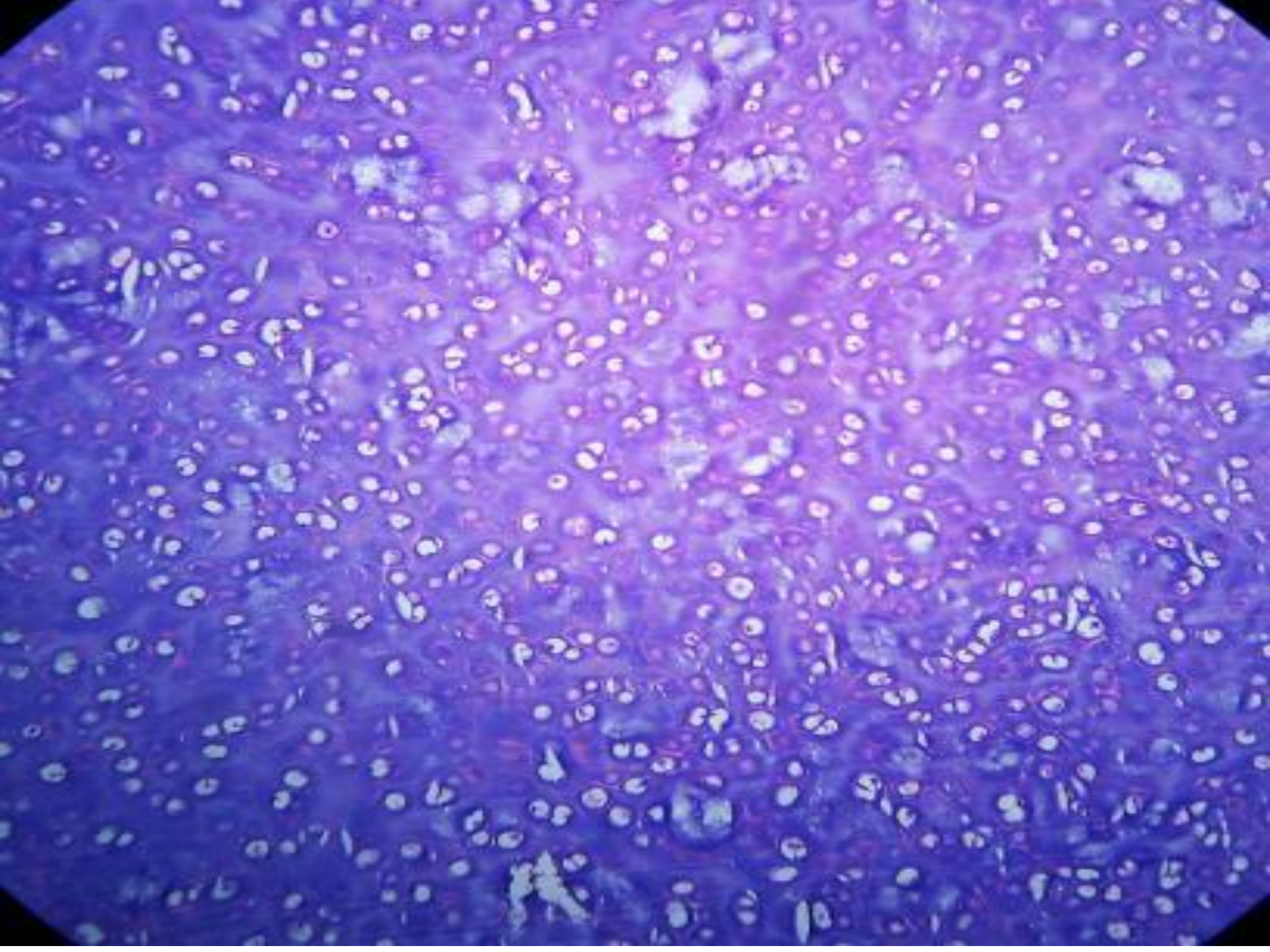
- 24 Y.M. external auditory canal (there is swelling extend to post auricular area )



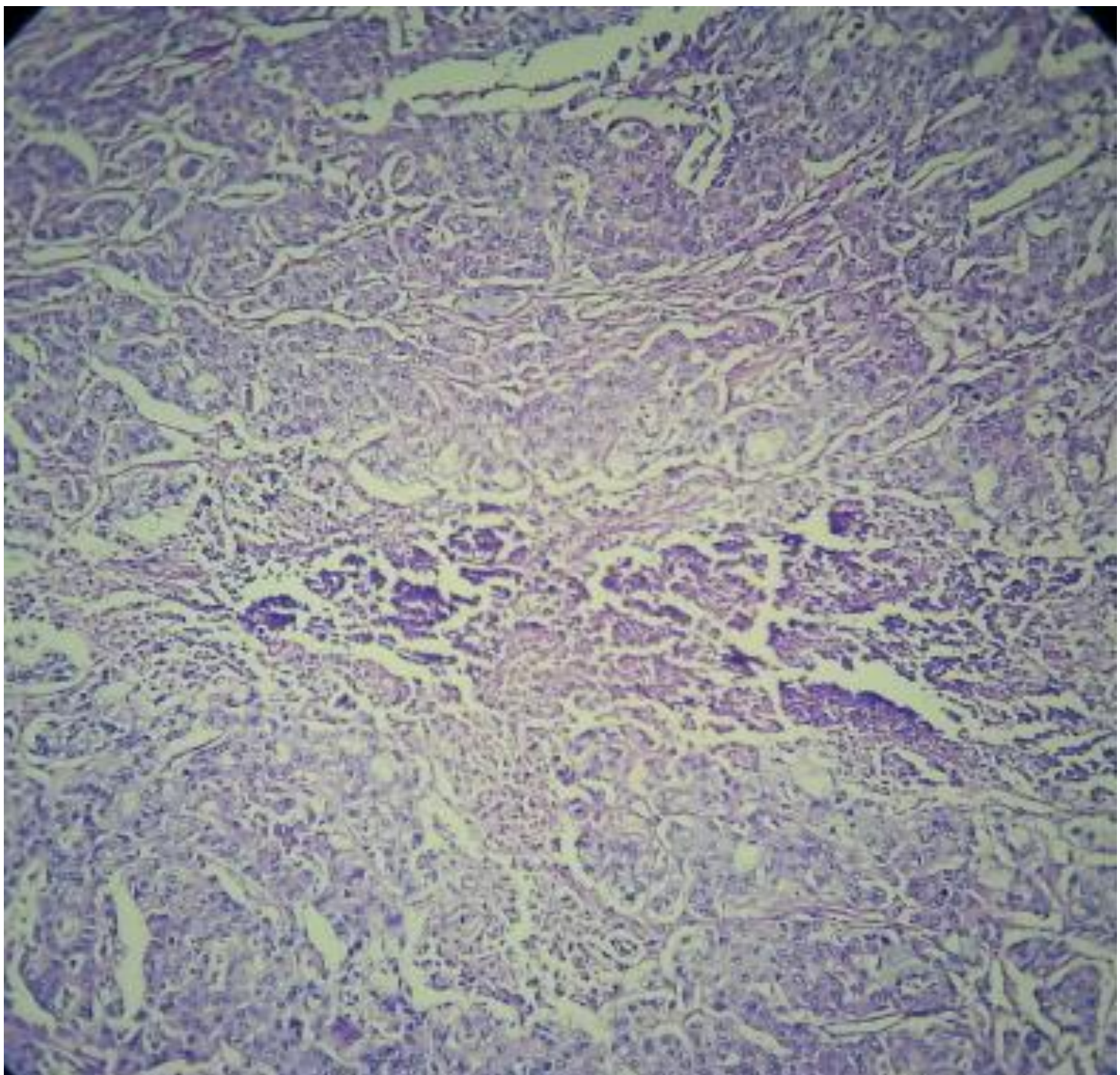


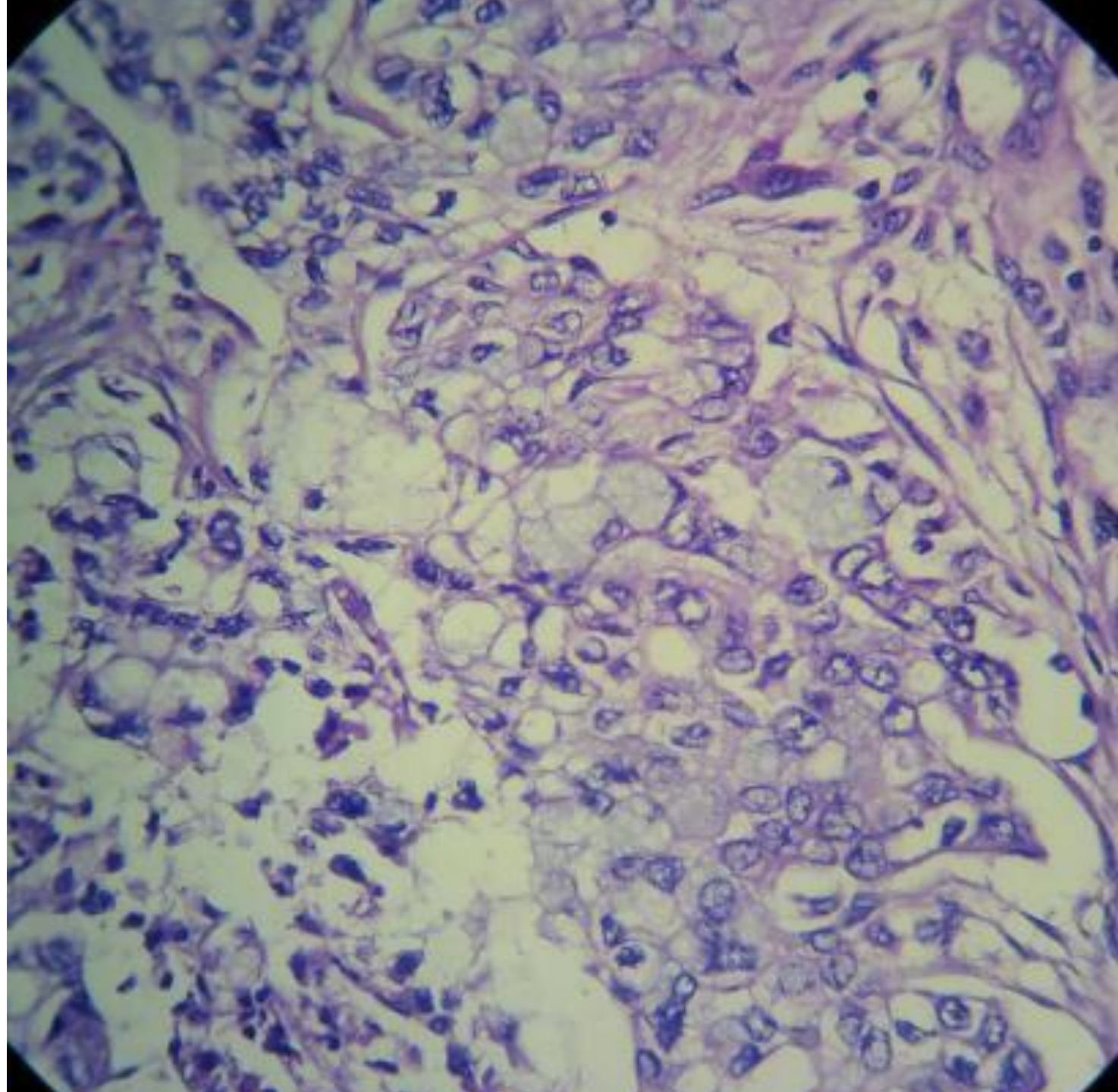


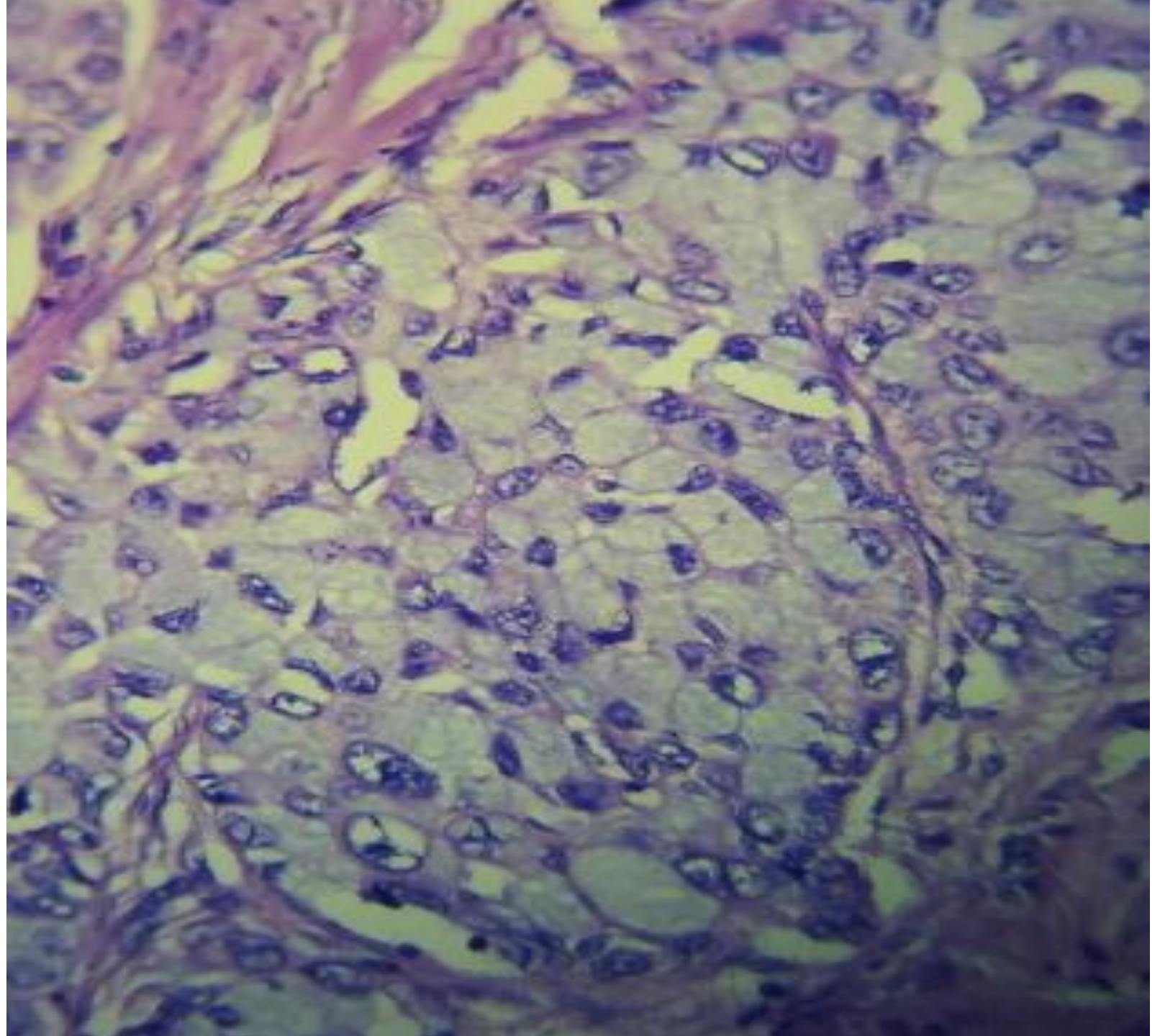




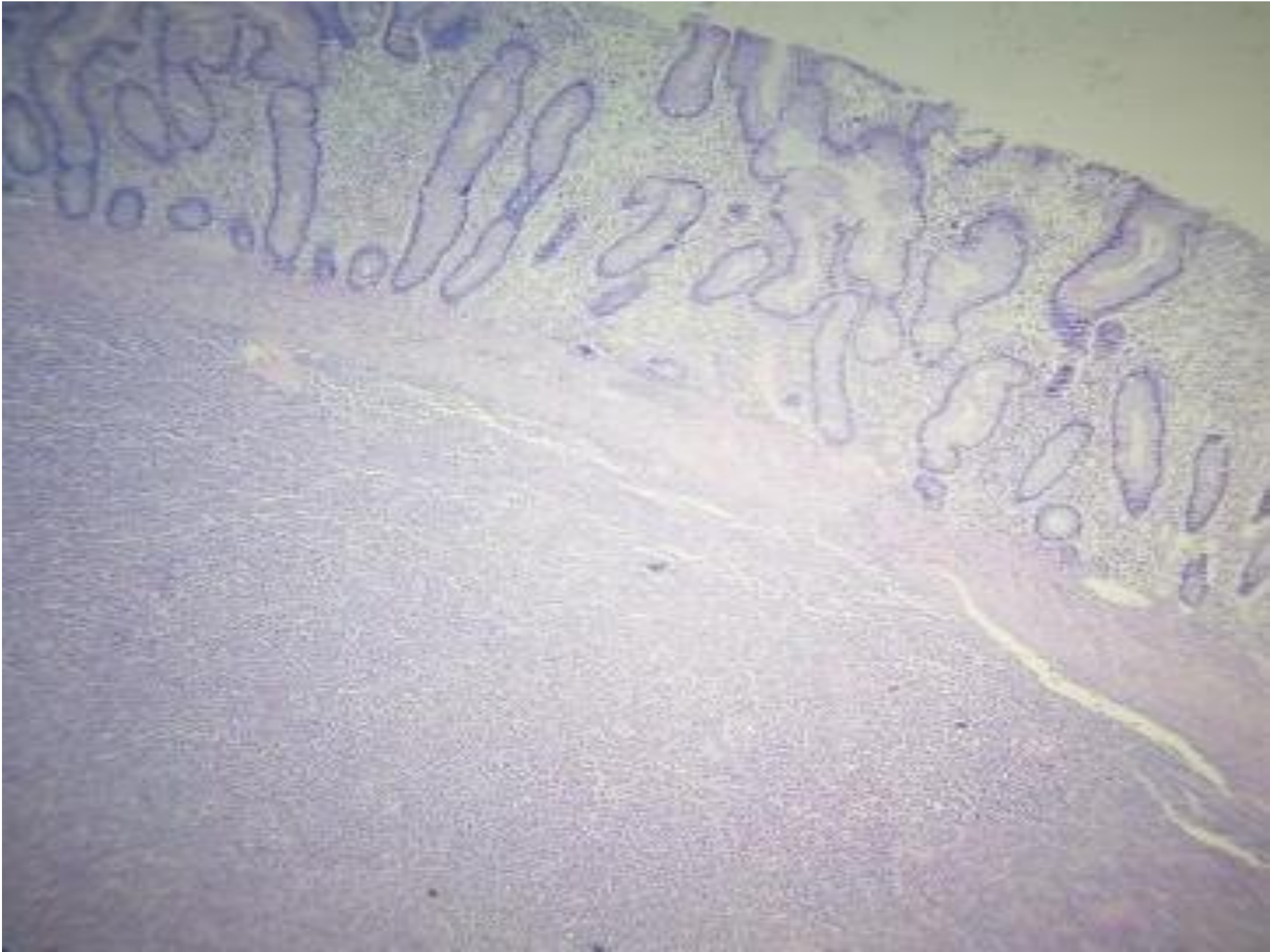
- 25 Y.M supraclavicular L.N



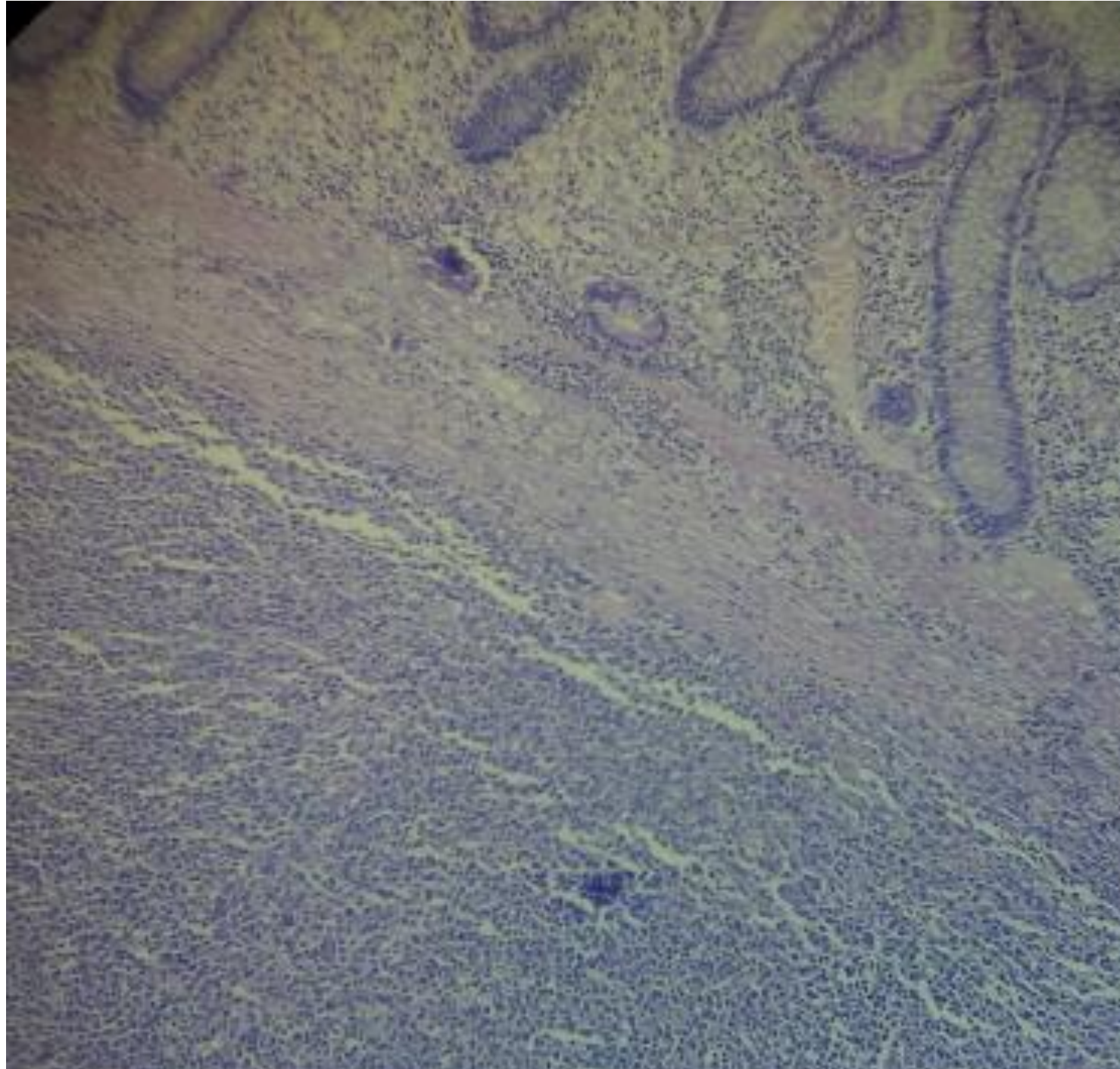


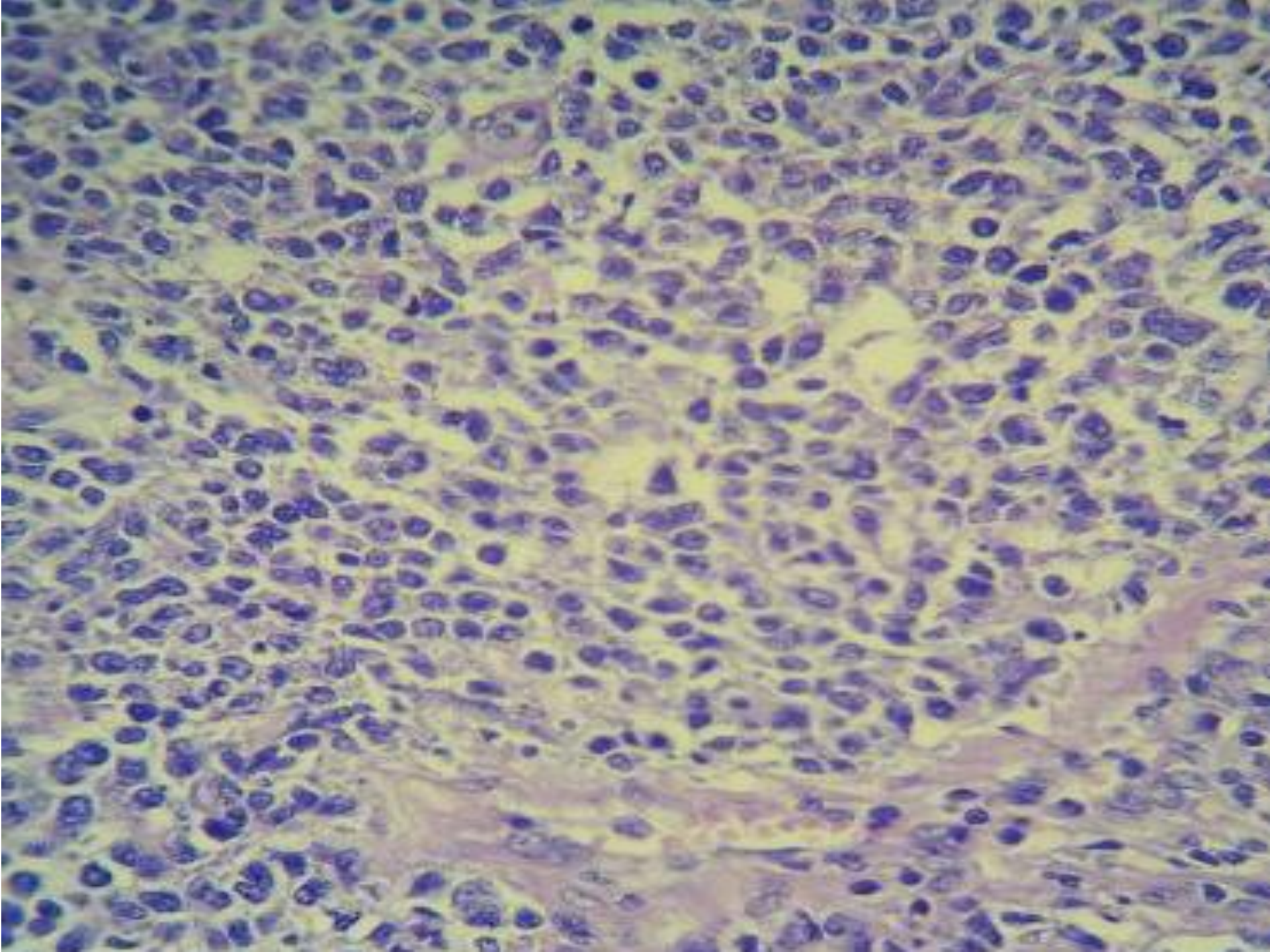


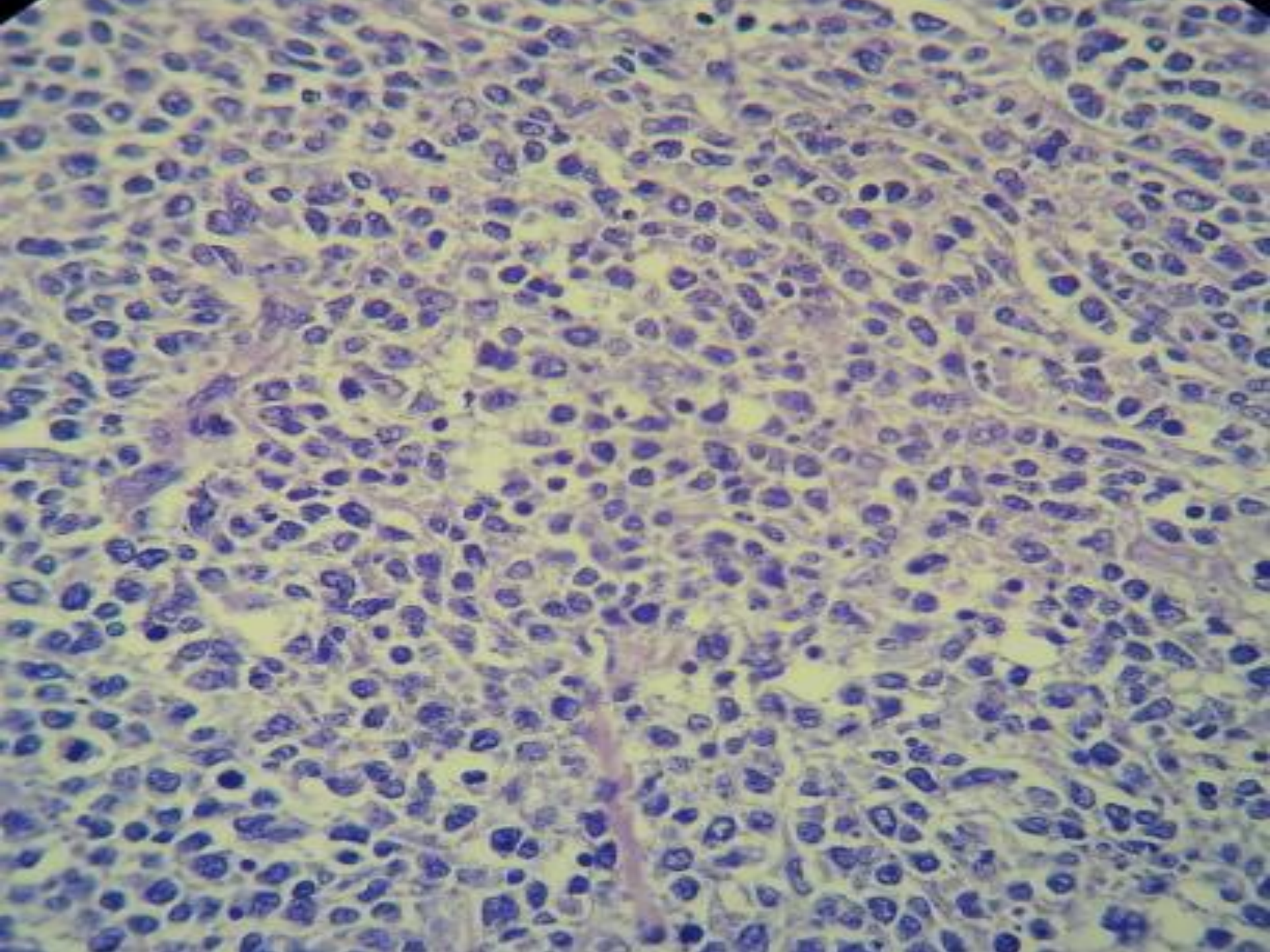
- 40 Y.M. mass at cecum & ascending colon (Rt. Hemicolectomy)

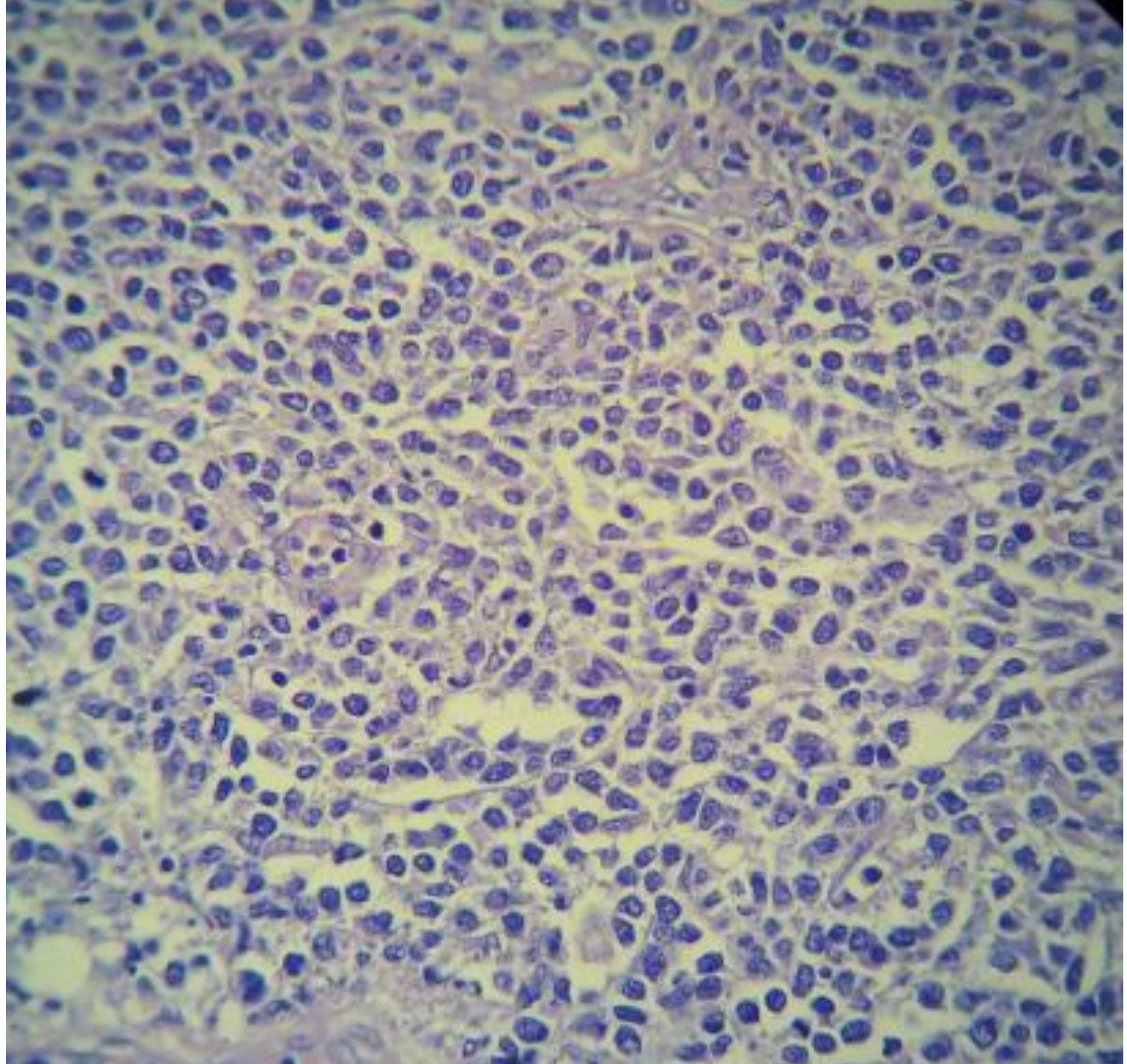




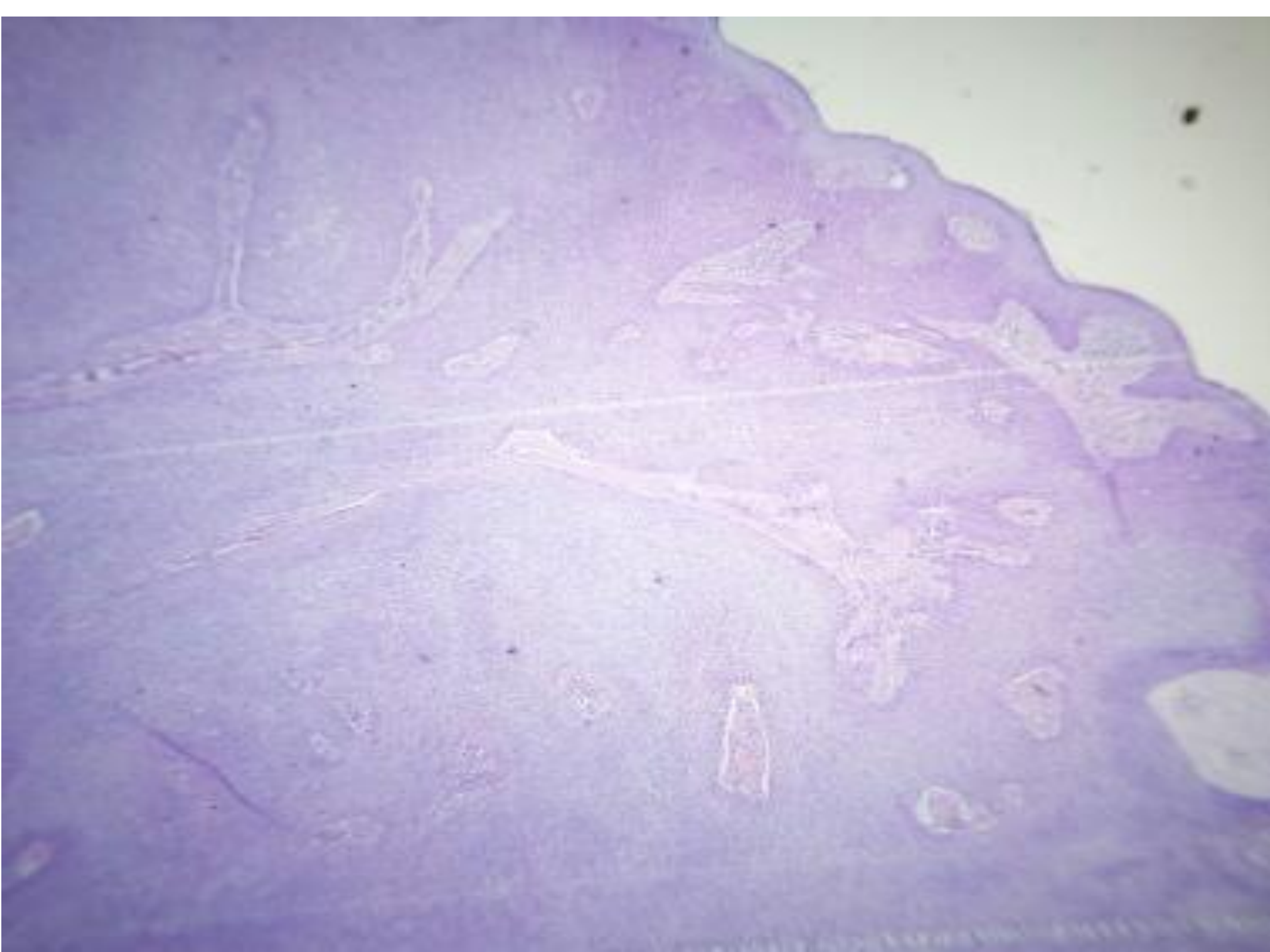


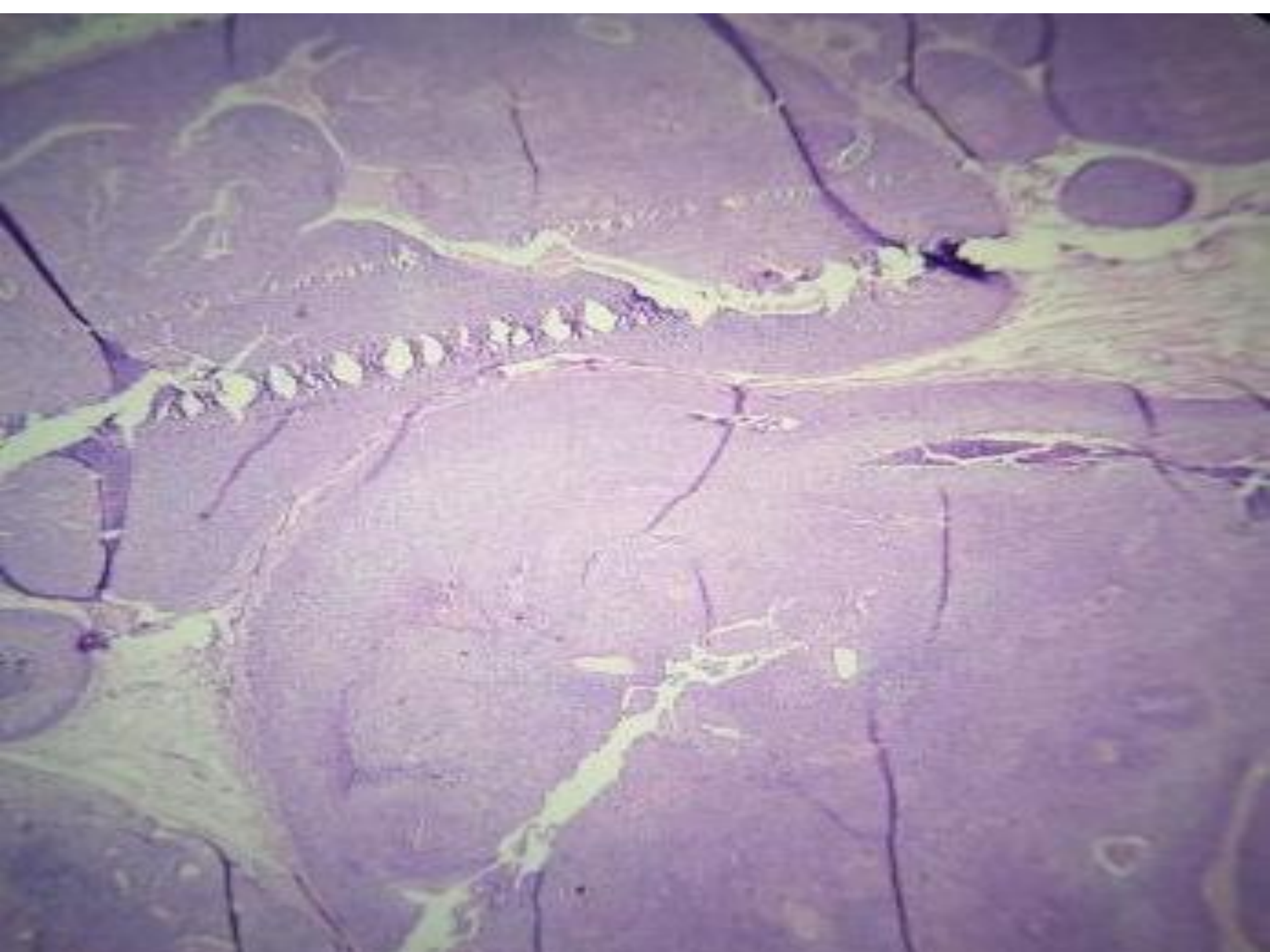


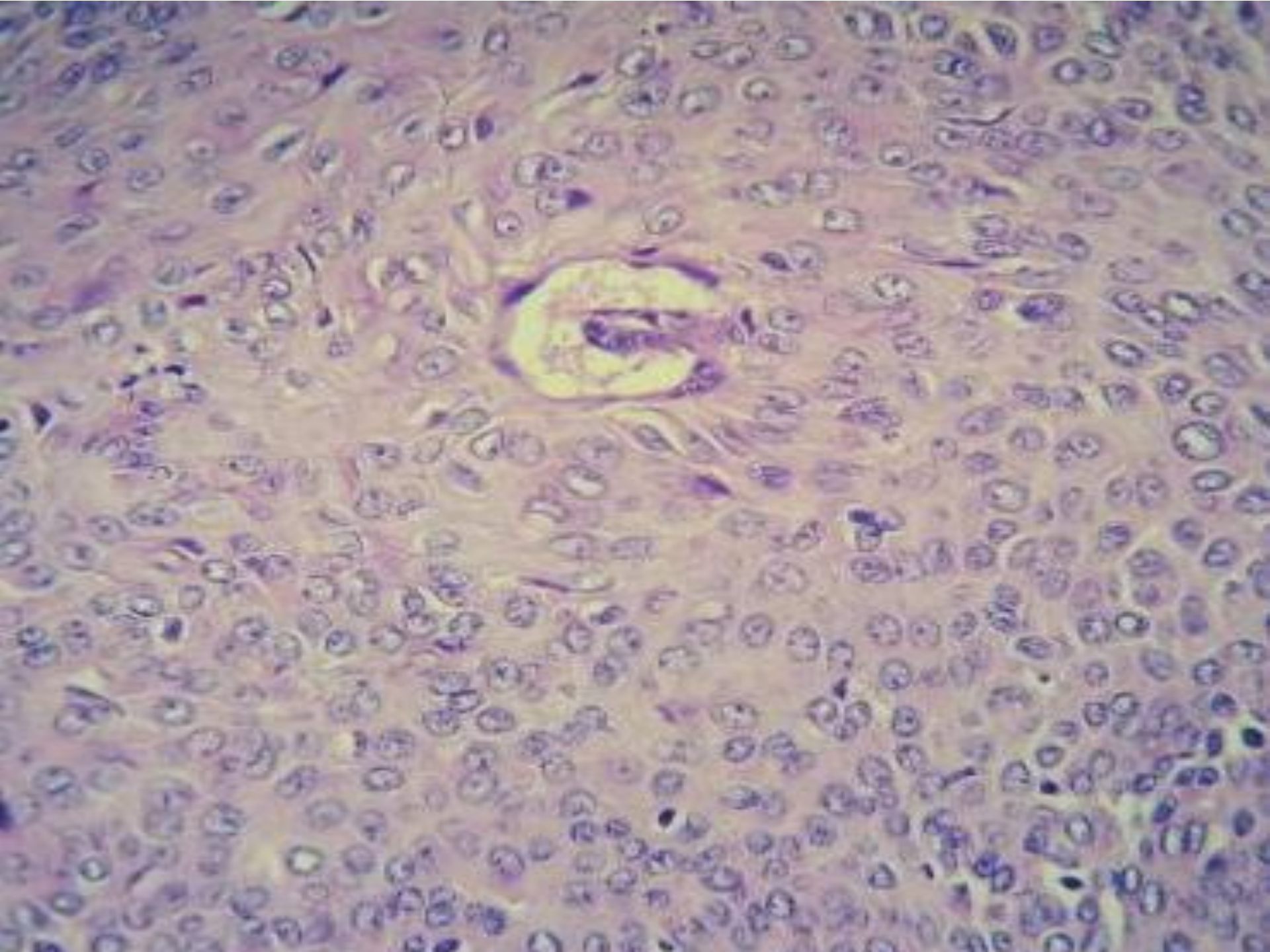




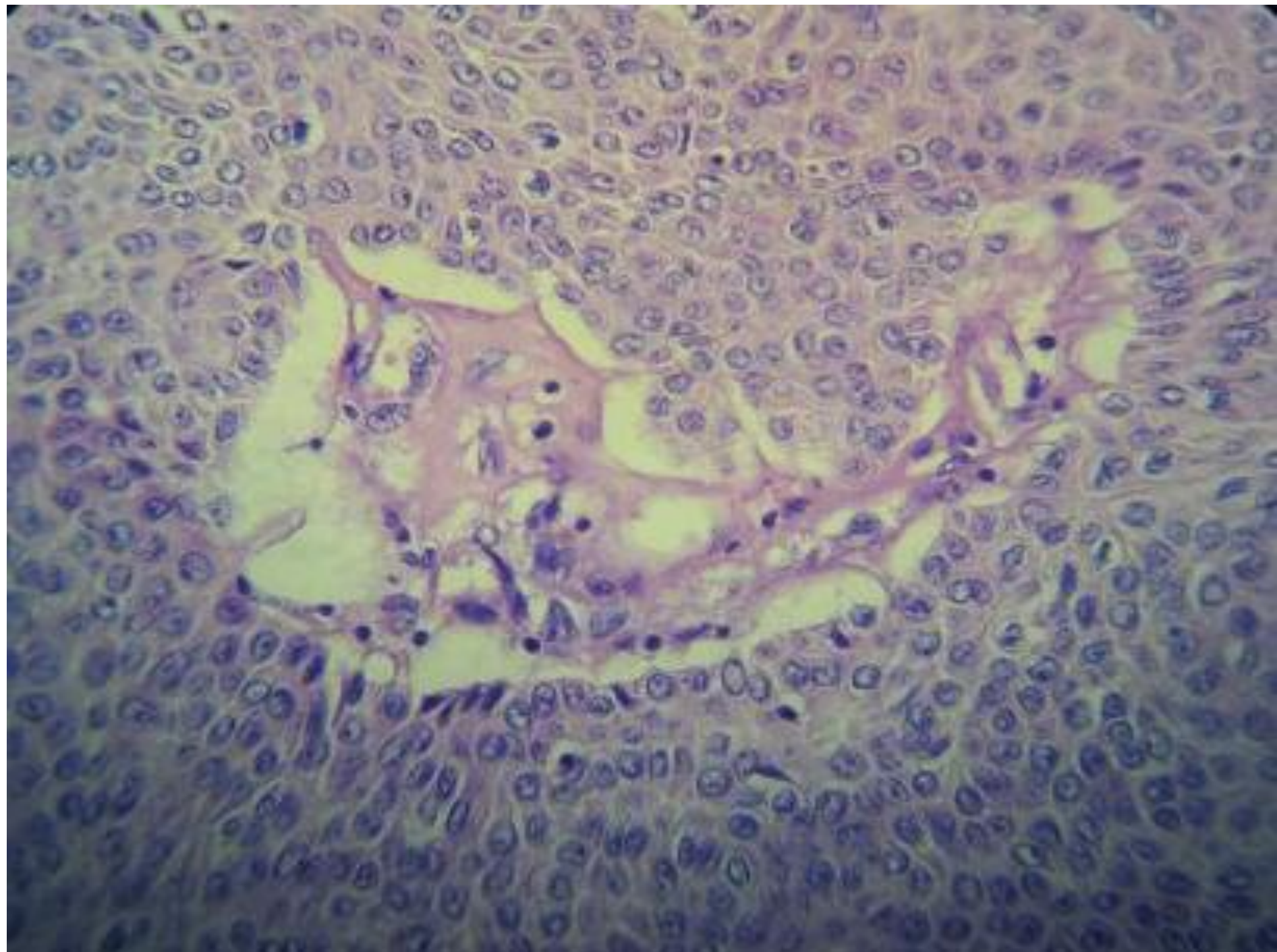
- 40 Y. M nodule at scalp (6 years duration)













THANK YOU