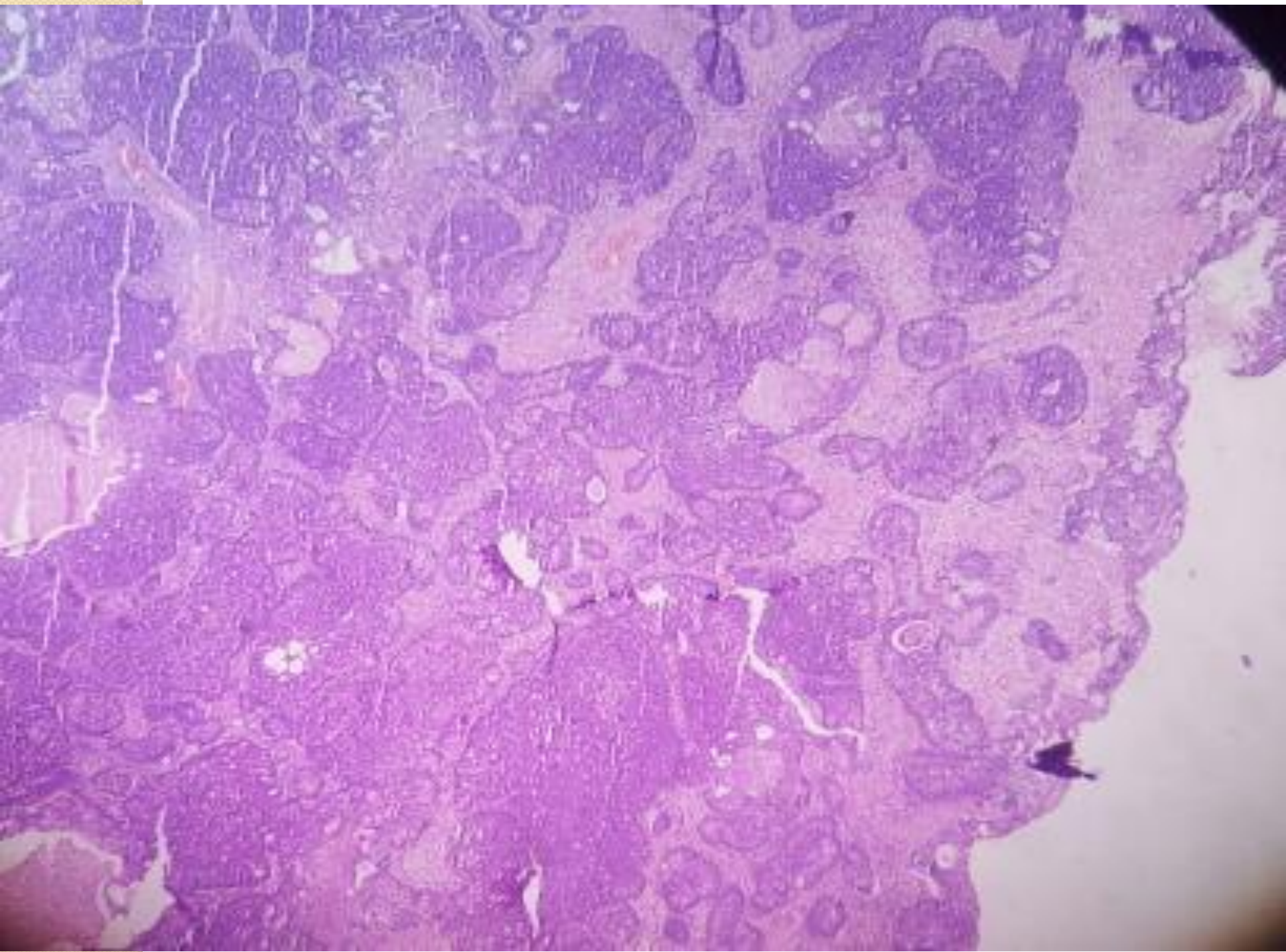
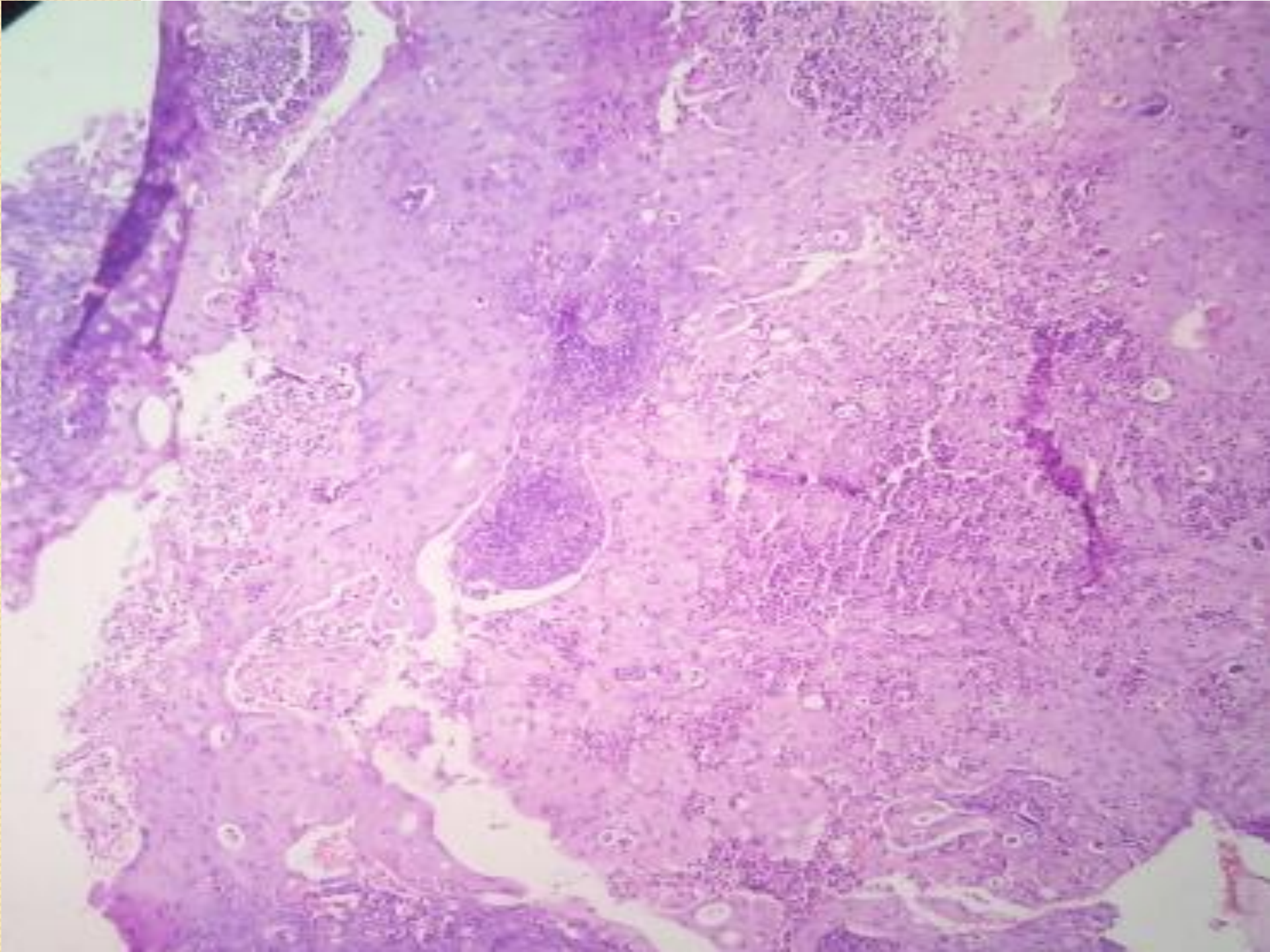


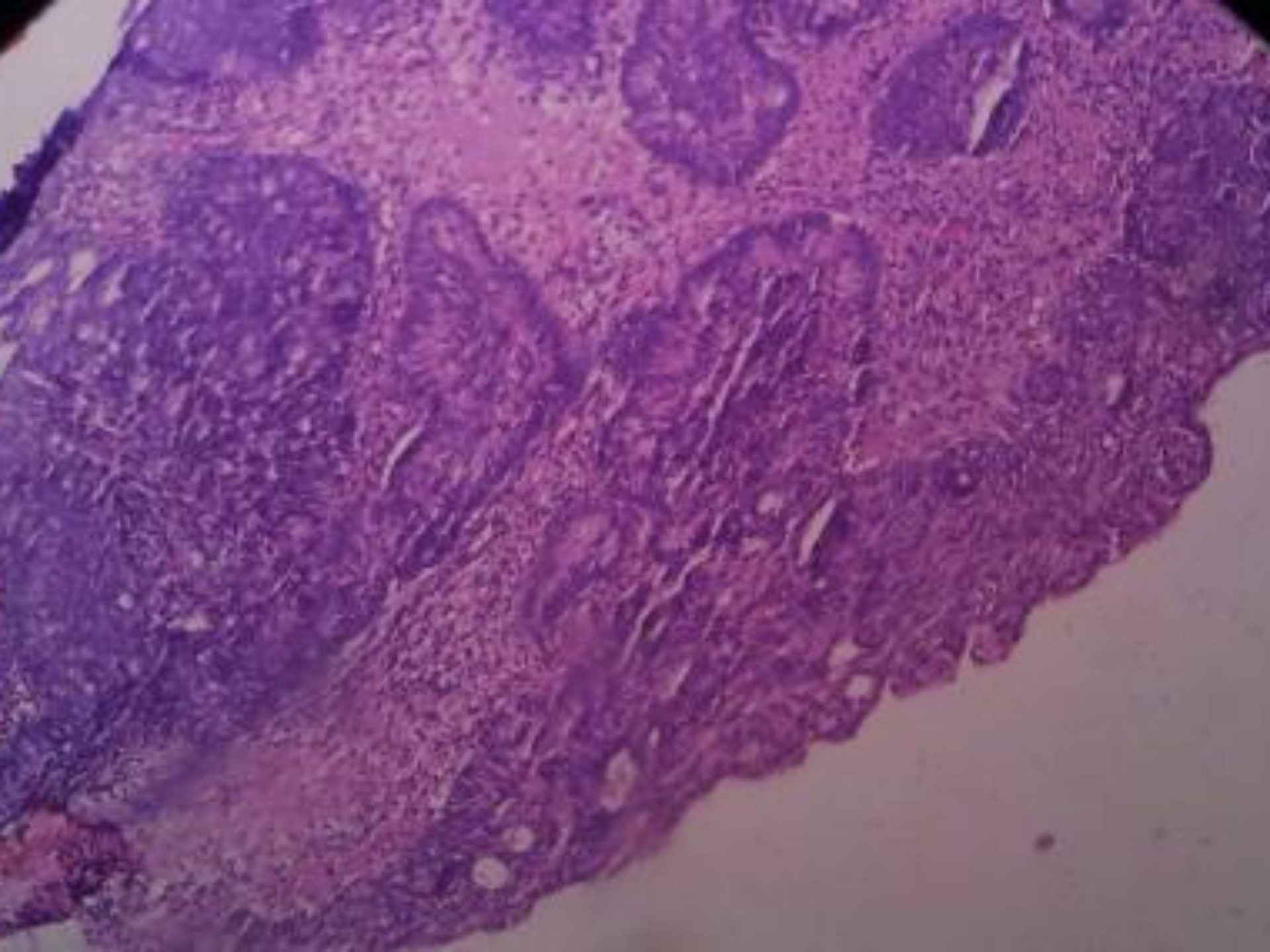


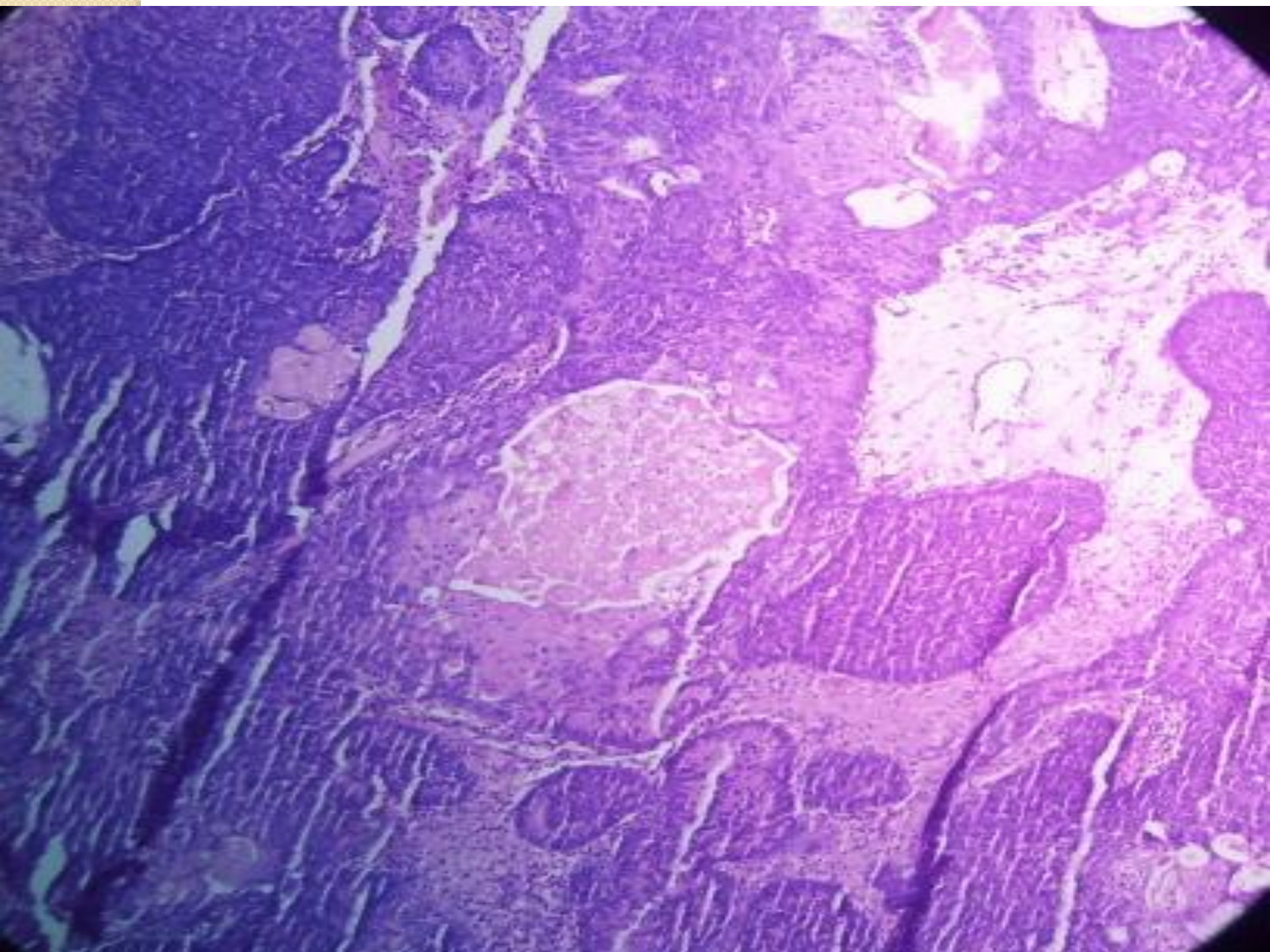
# 5<sup>th</sup> Slide Meeting

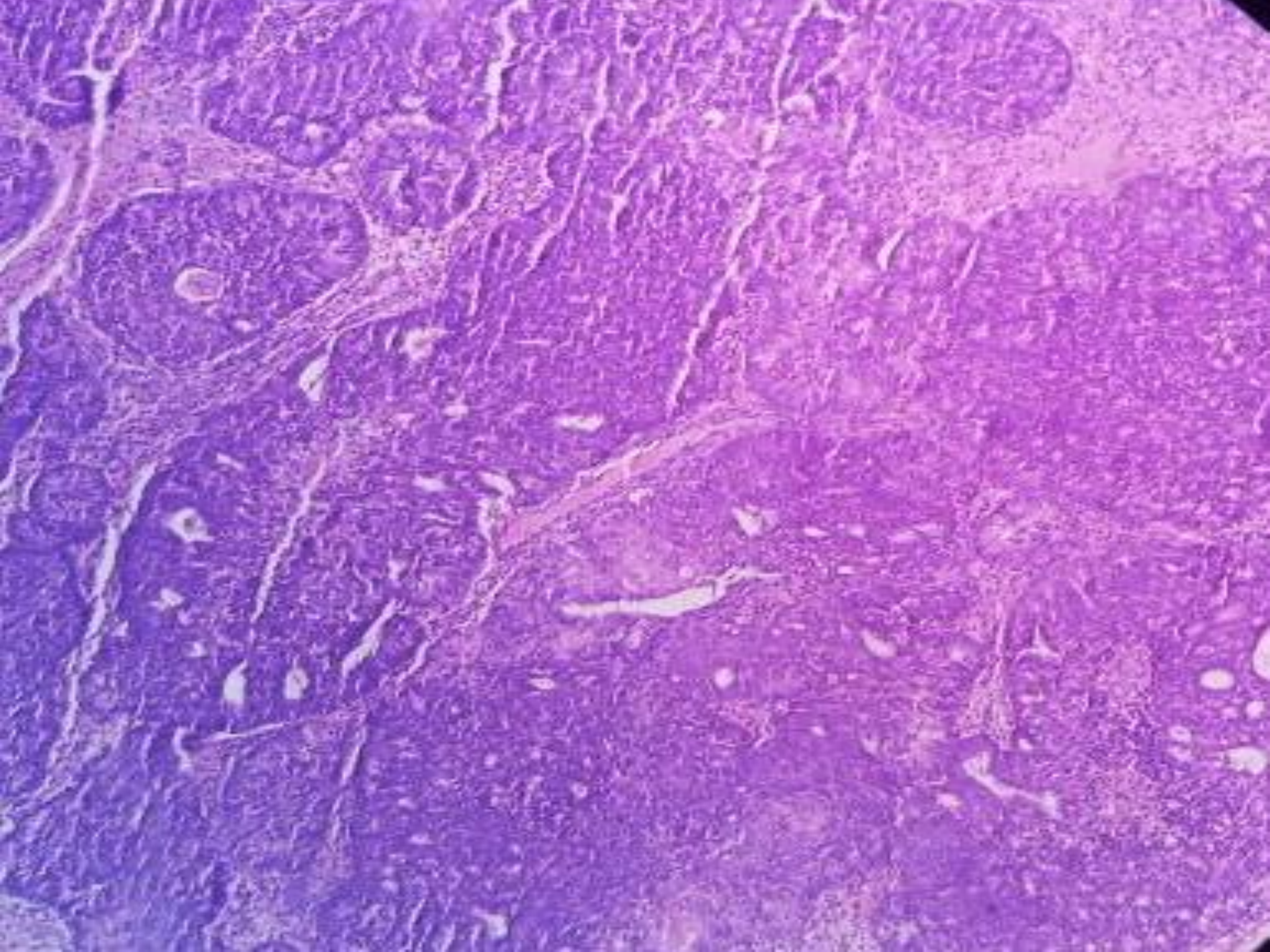
- 
- **60 Y.F Vaginal bleeding**

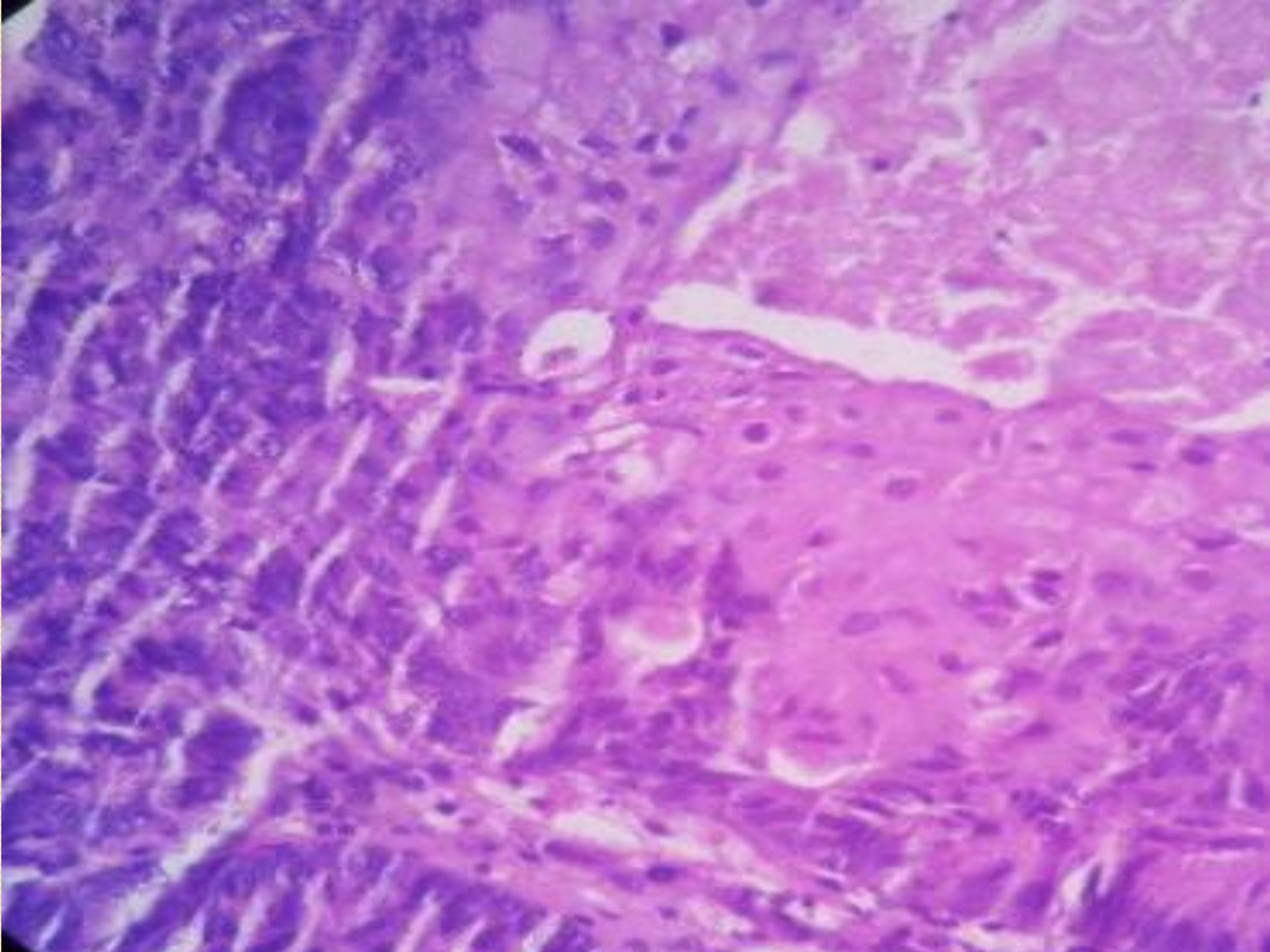




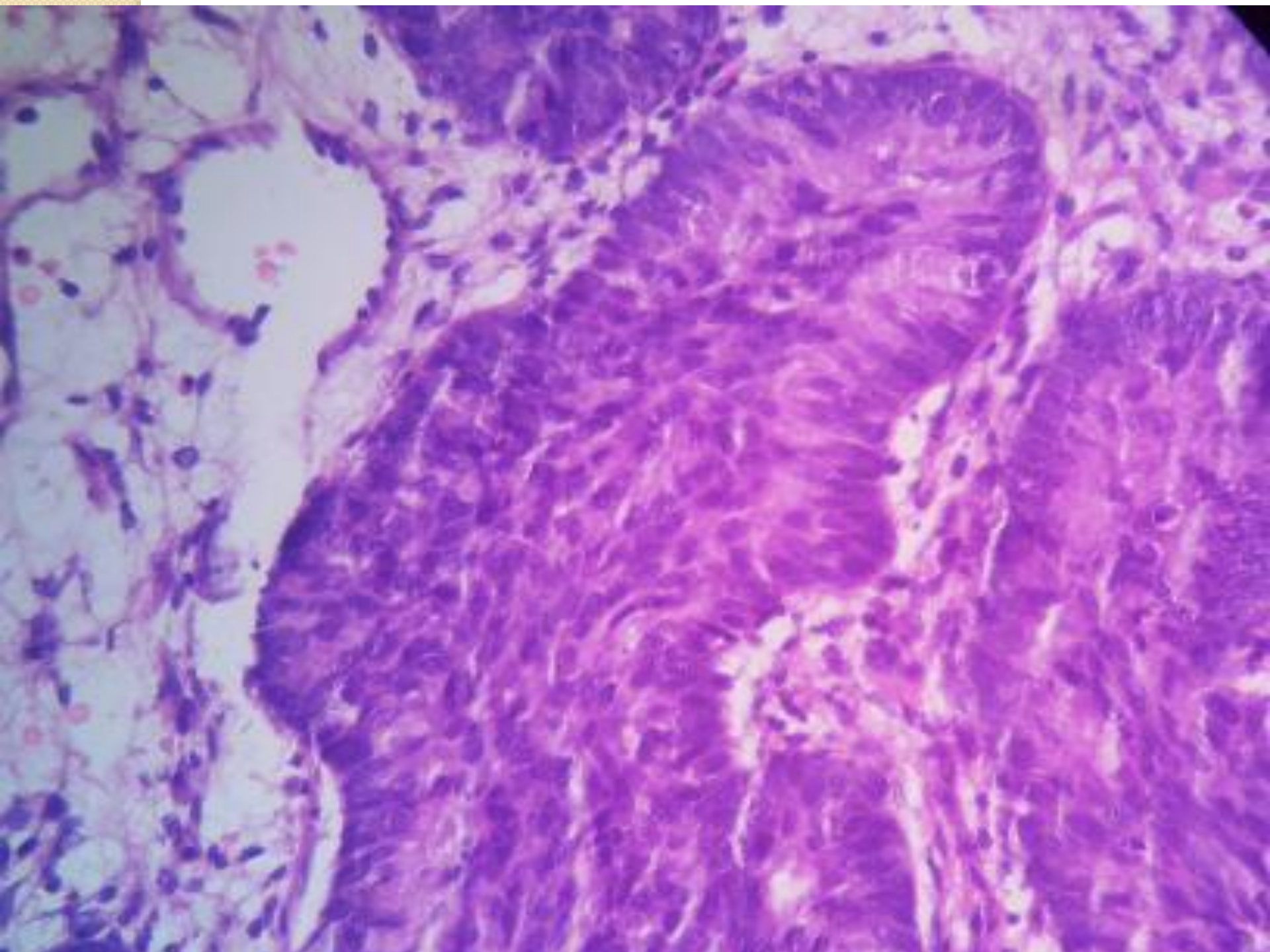




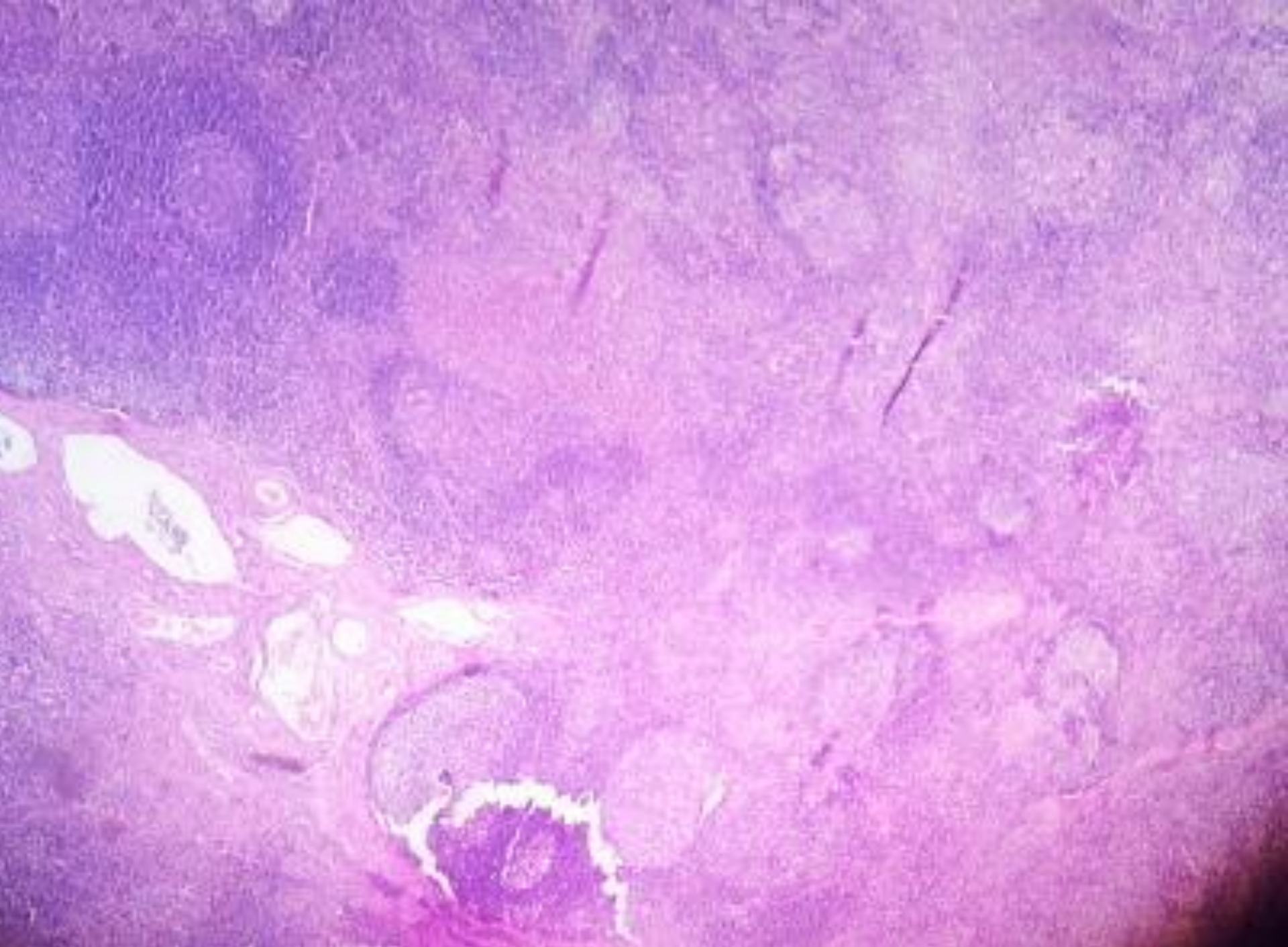


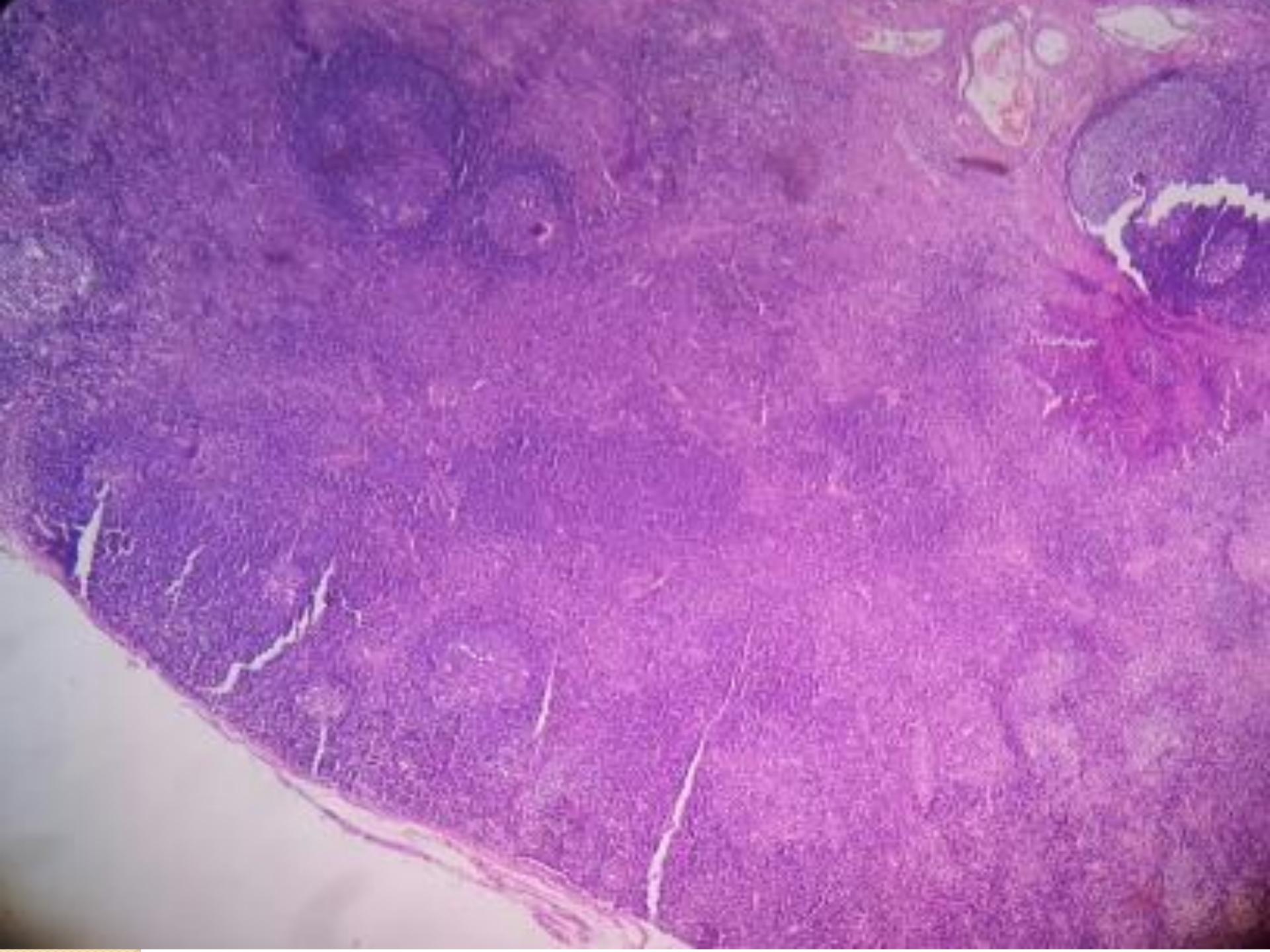


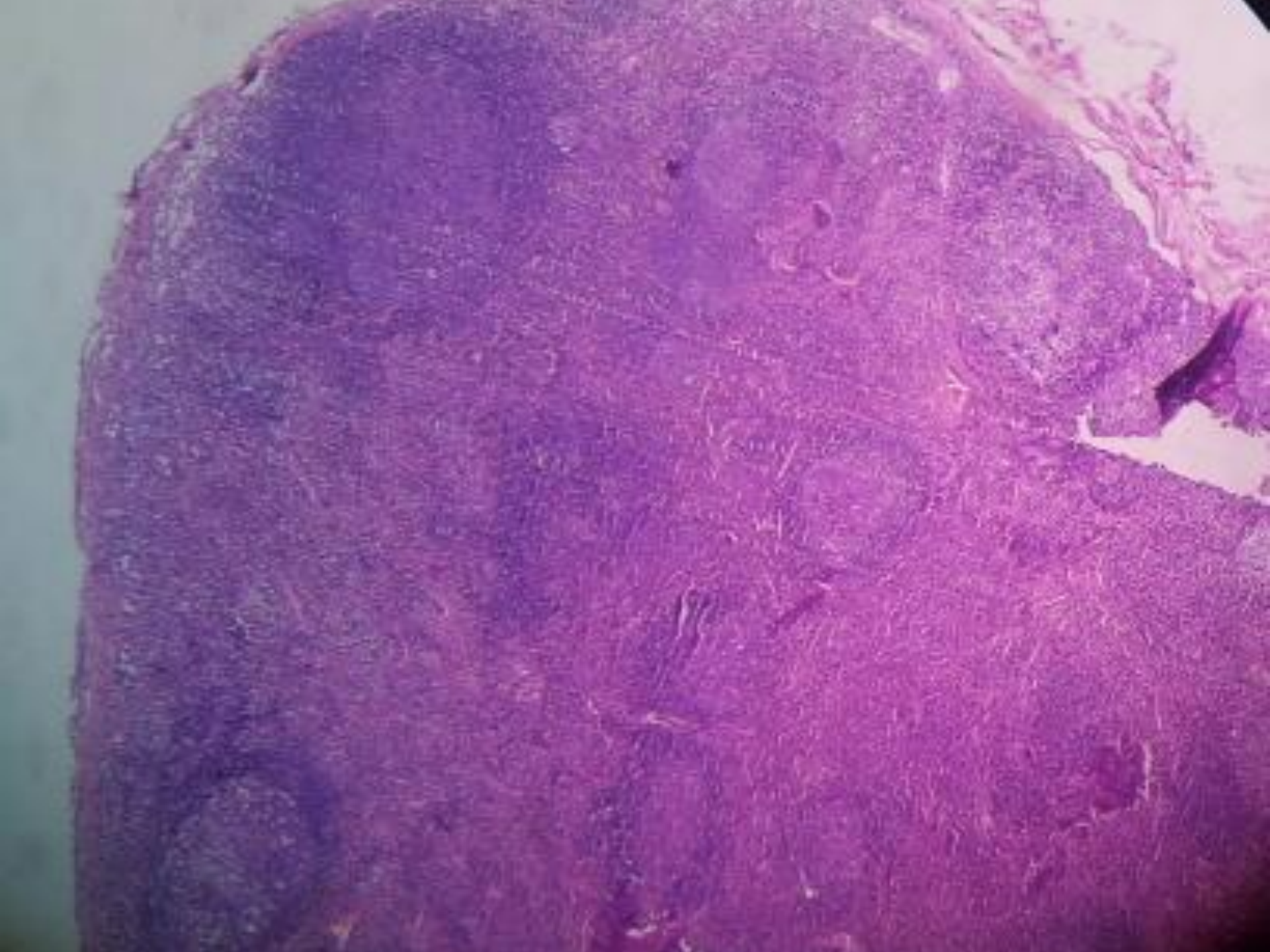

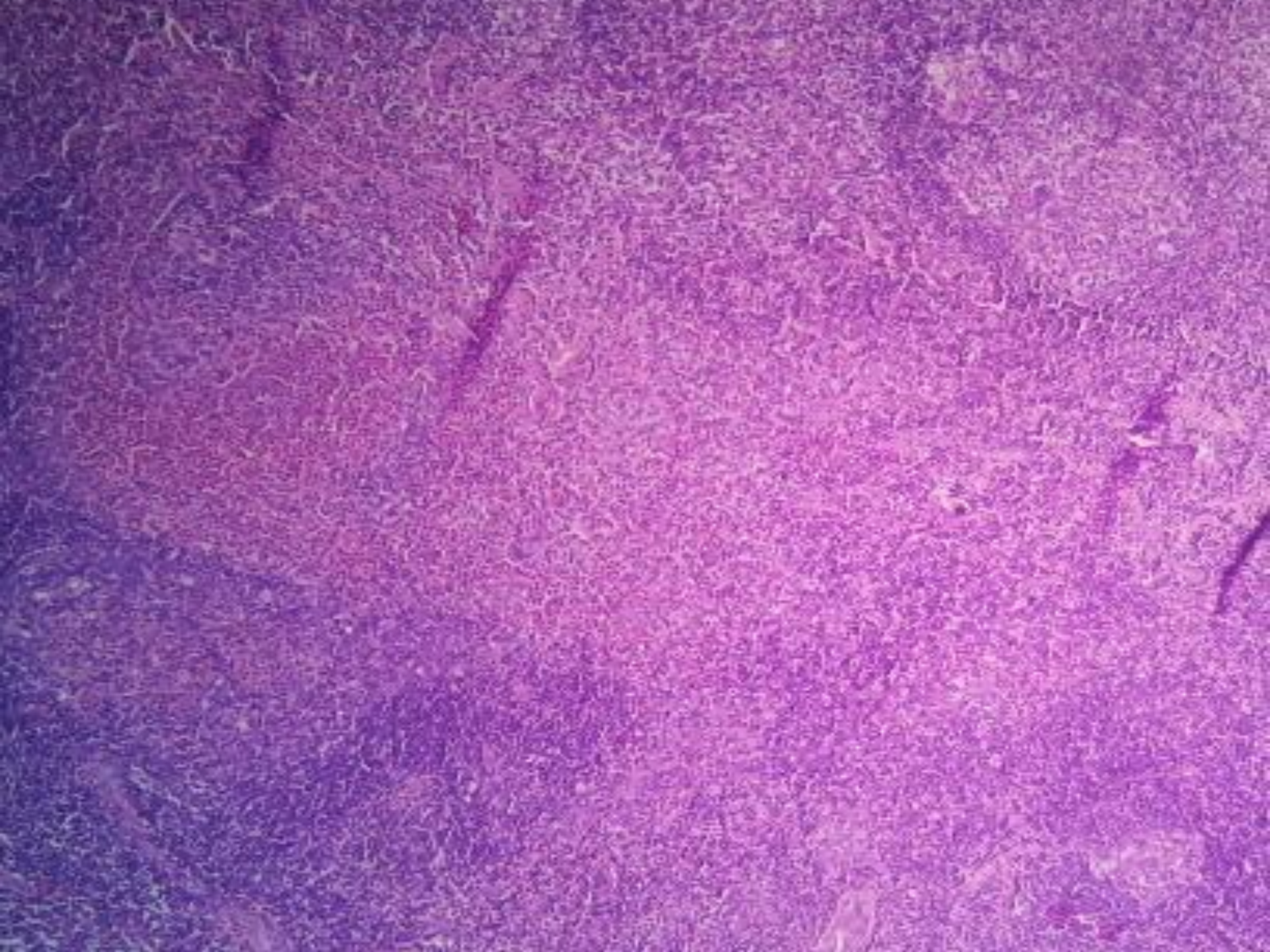


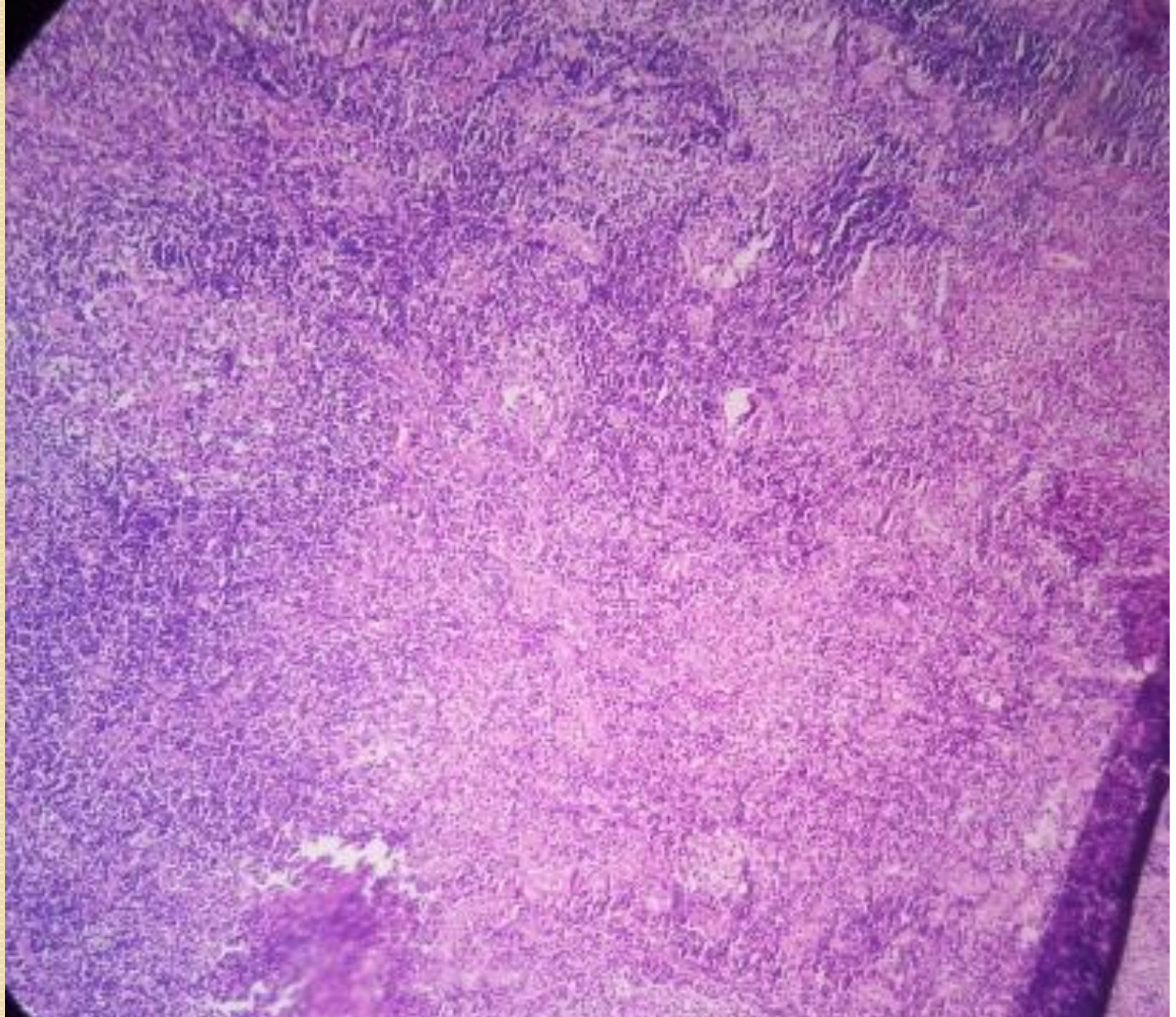
- 
- **84 Y.M. Cervical & occipital L.N**

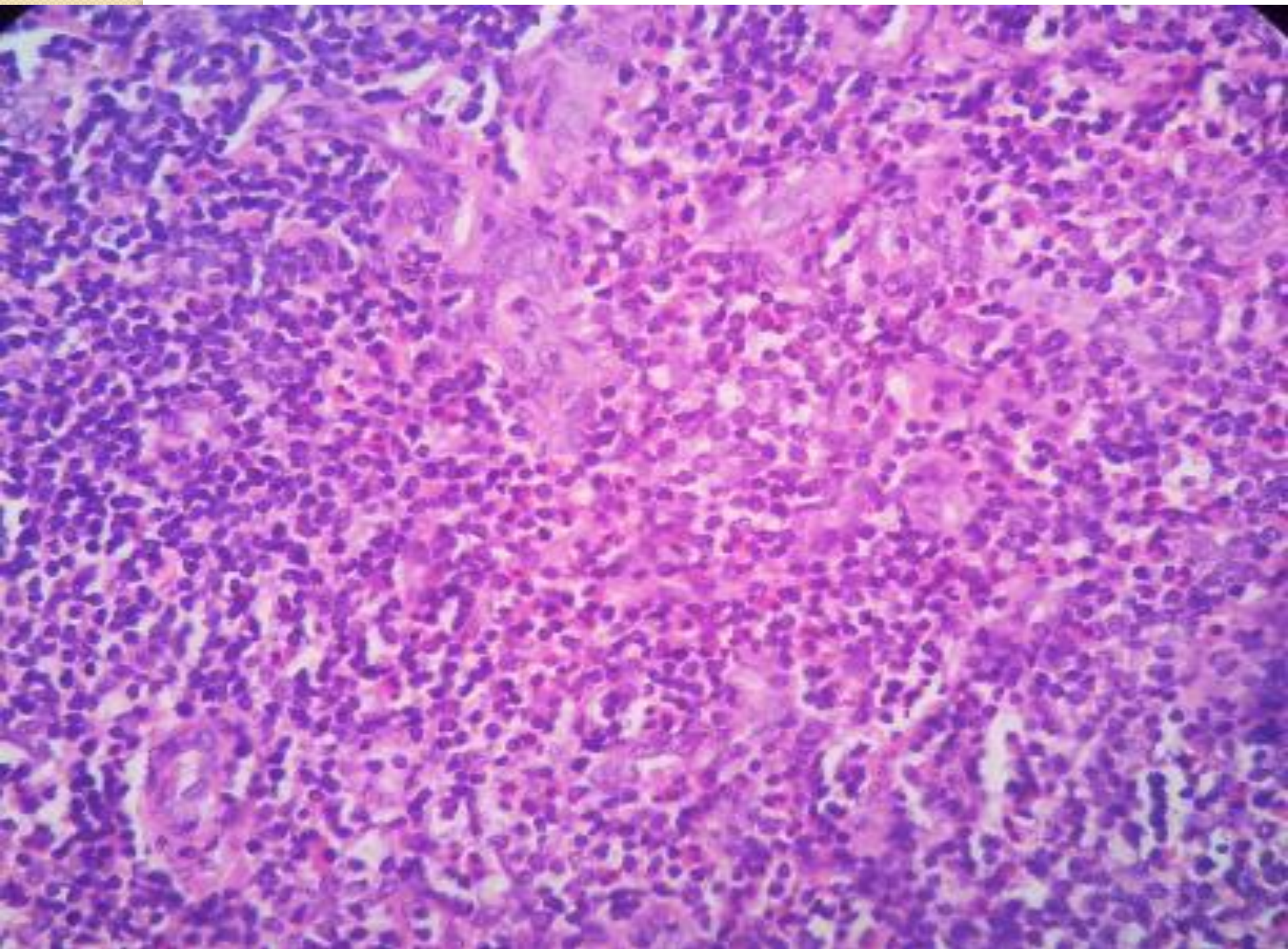




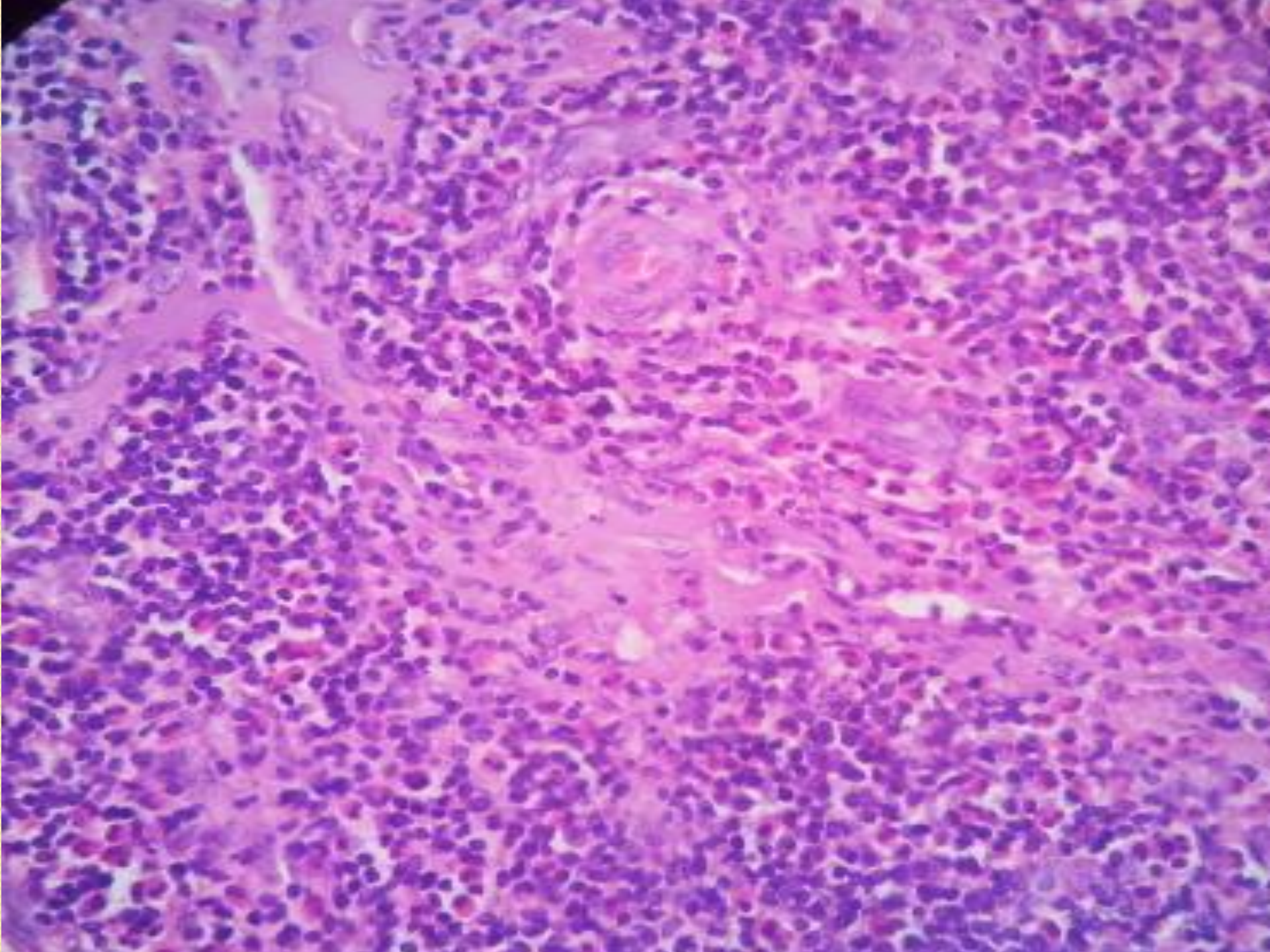


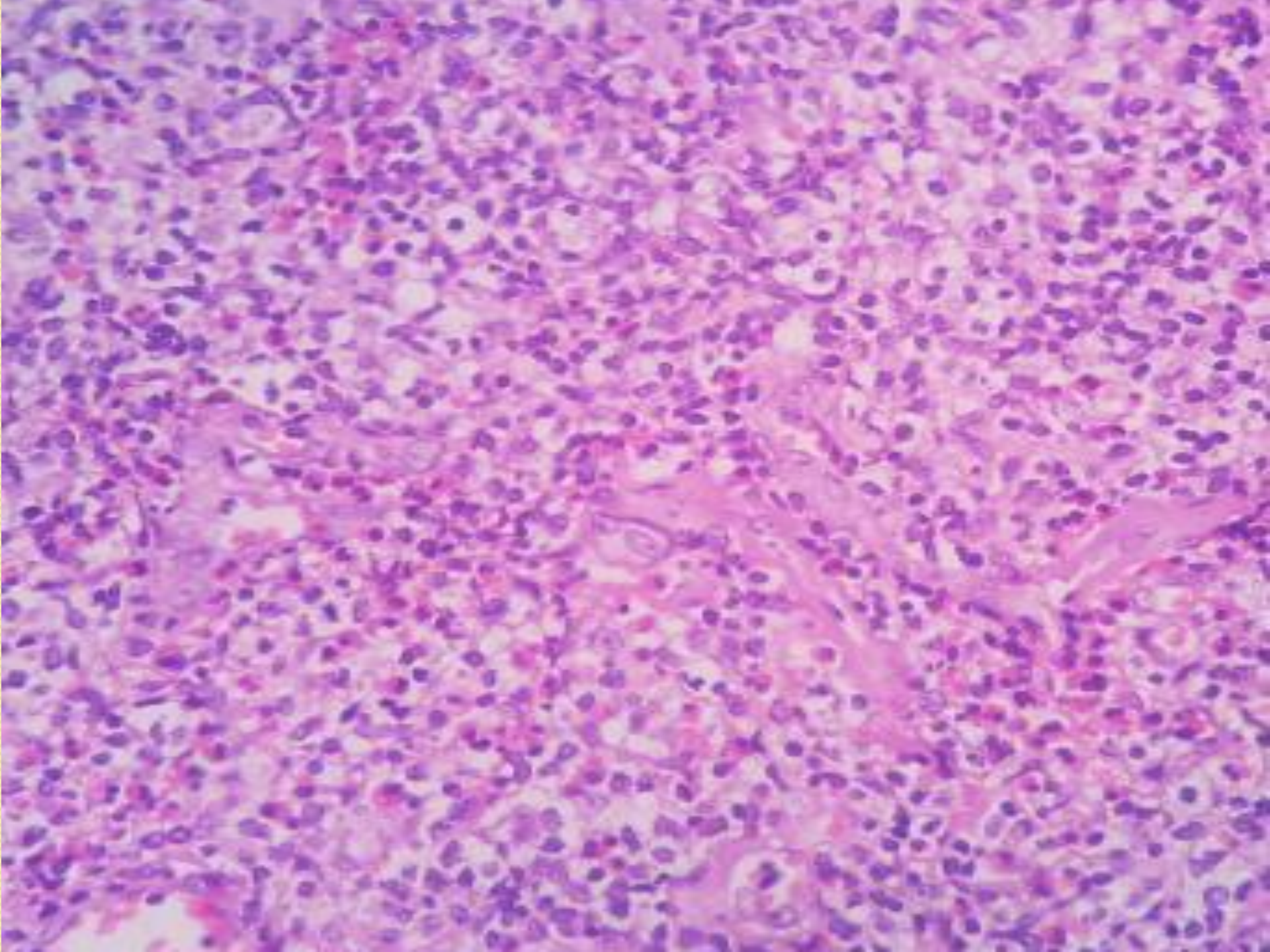




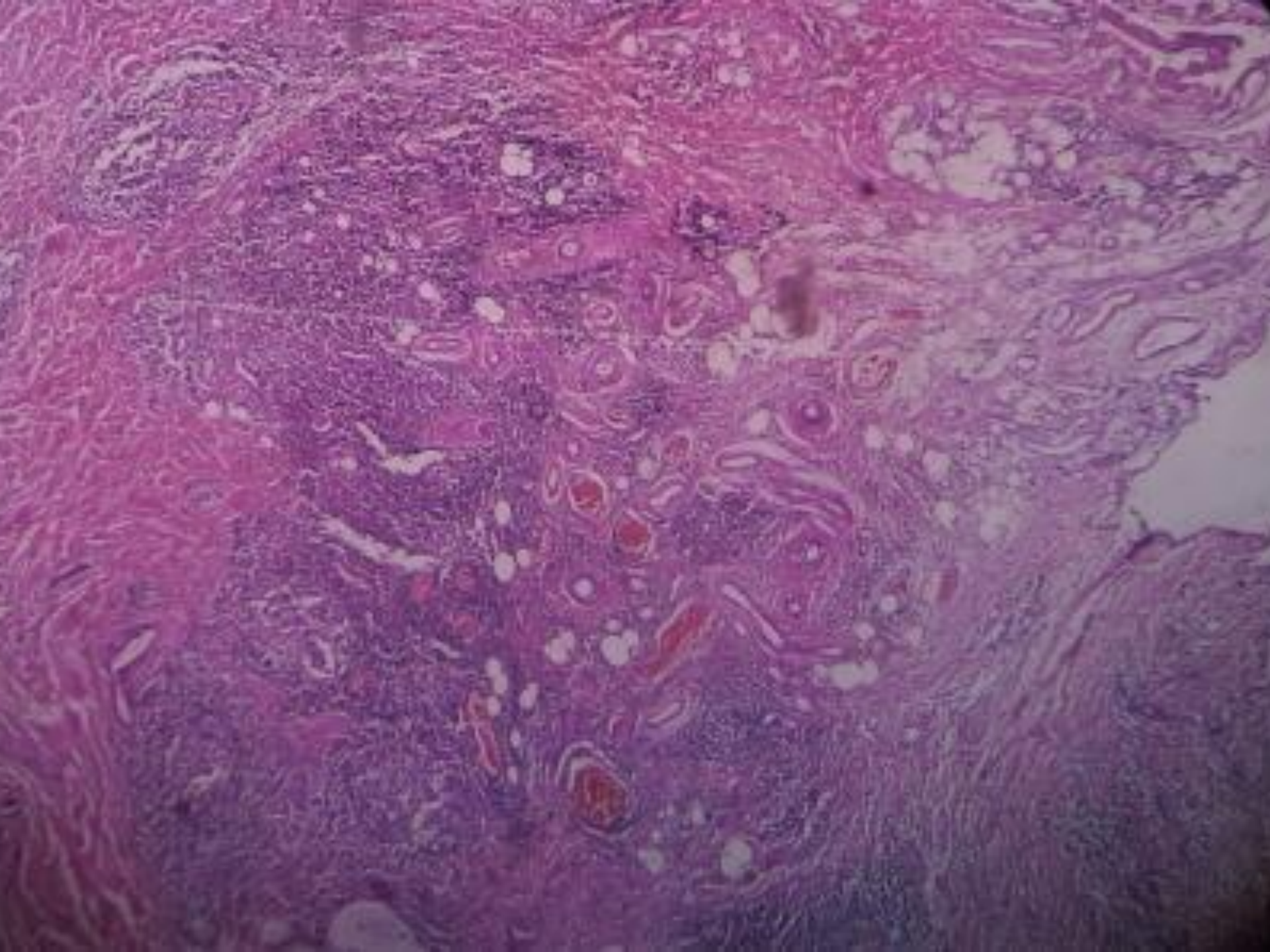


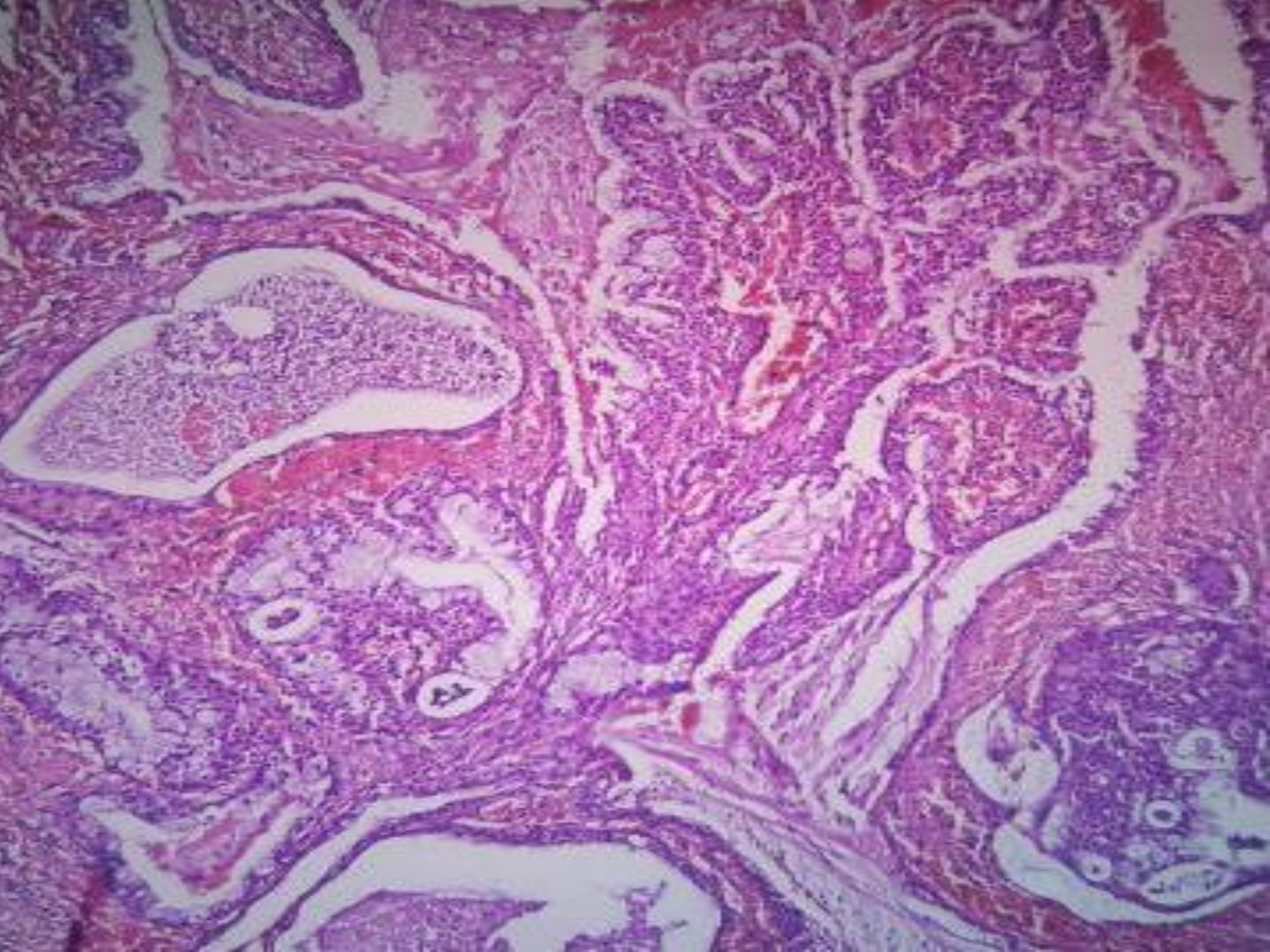


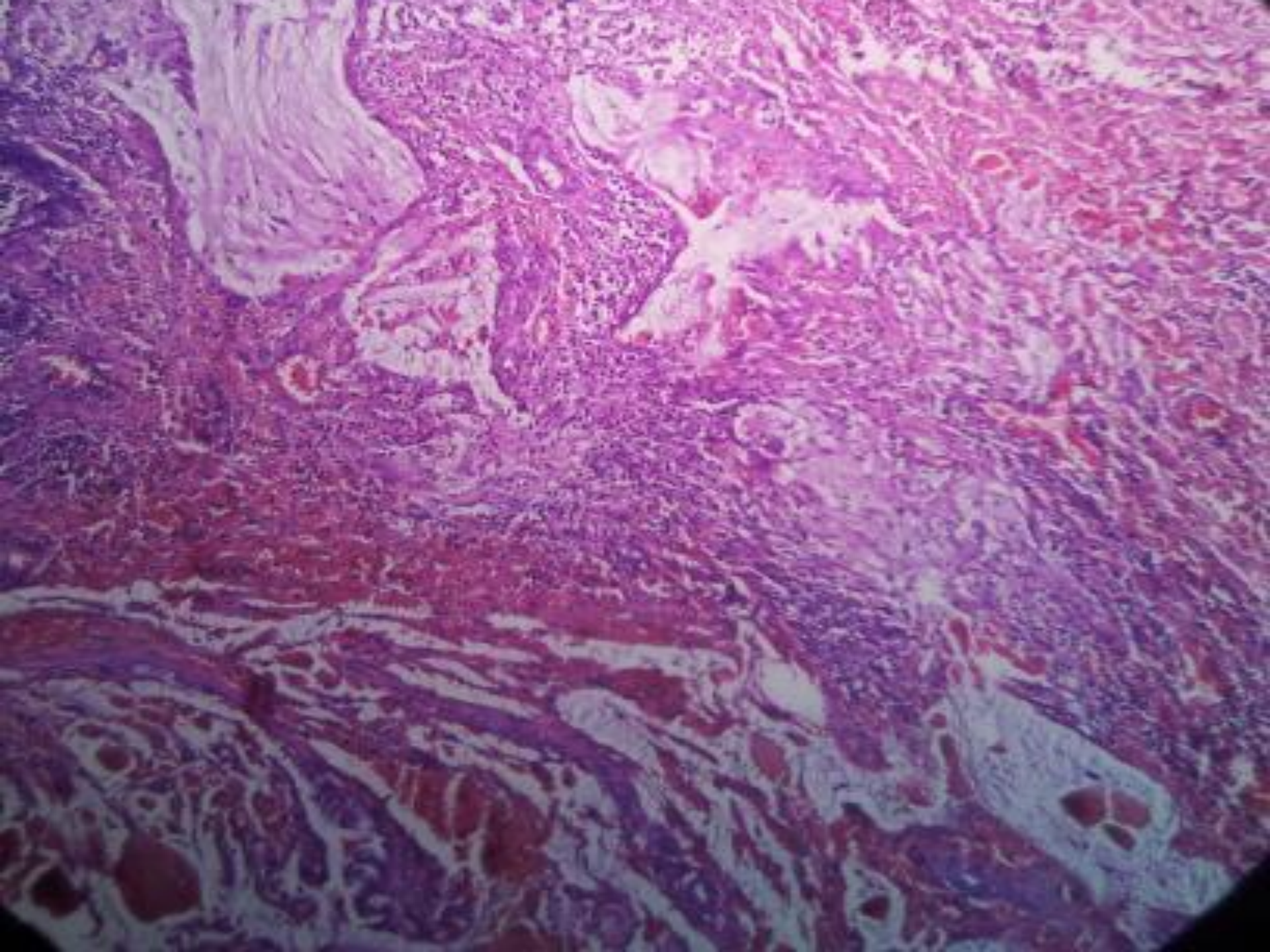


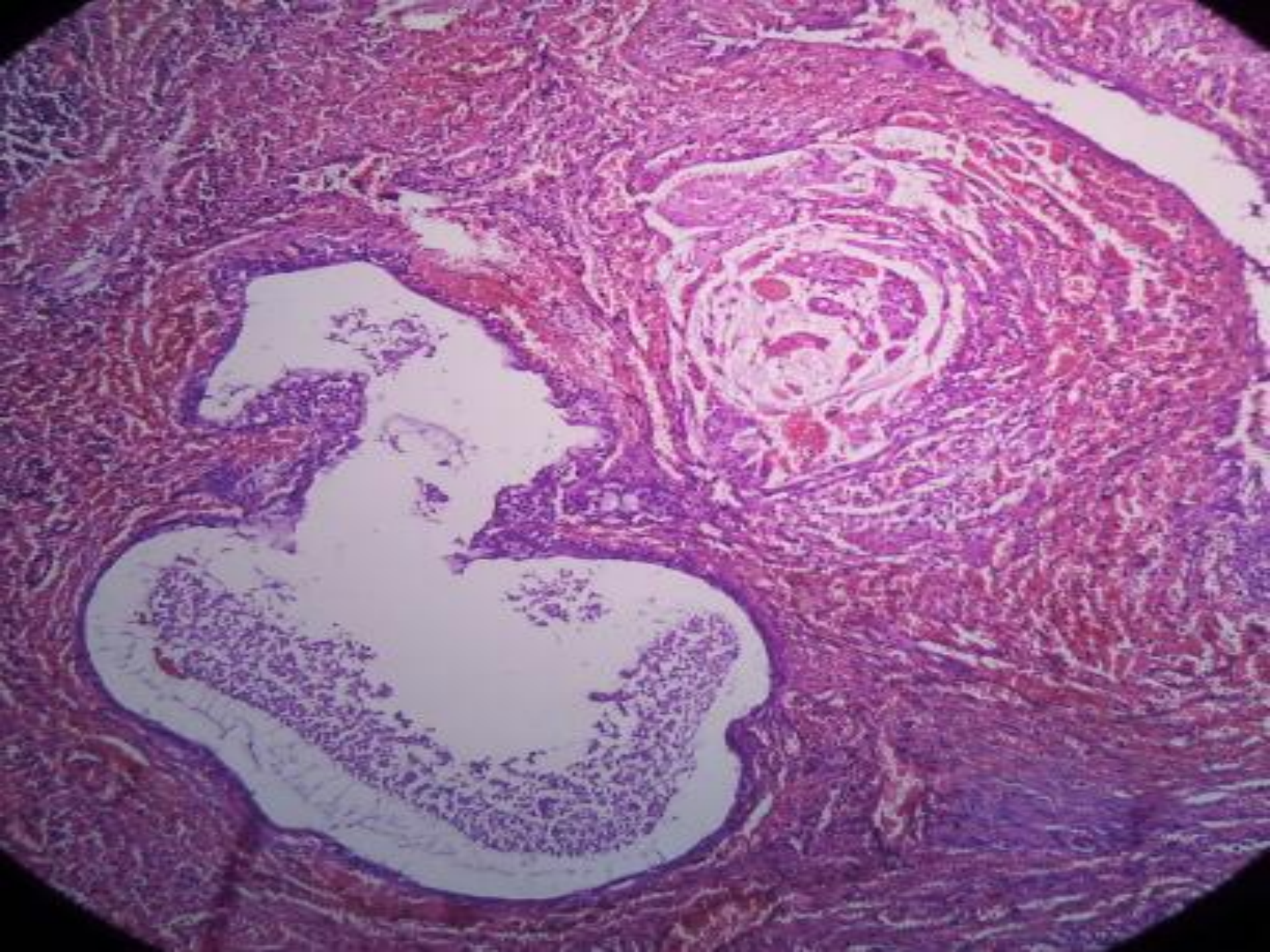


- 45 Y. parotid



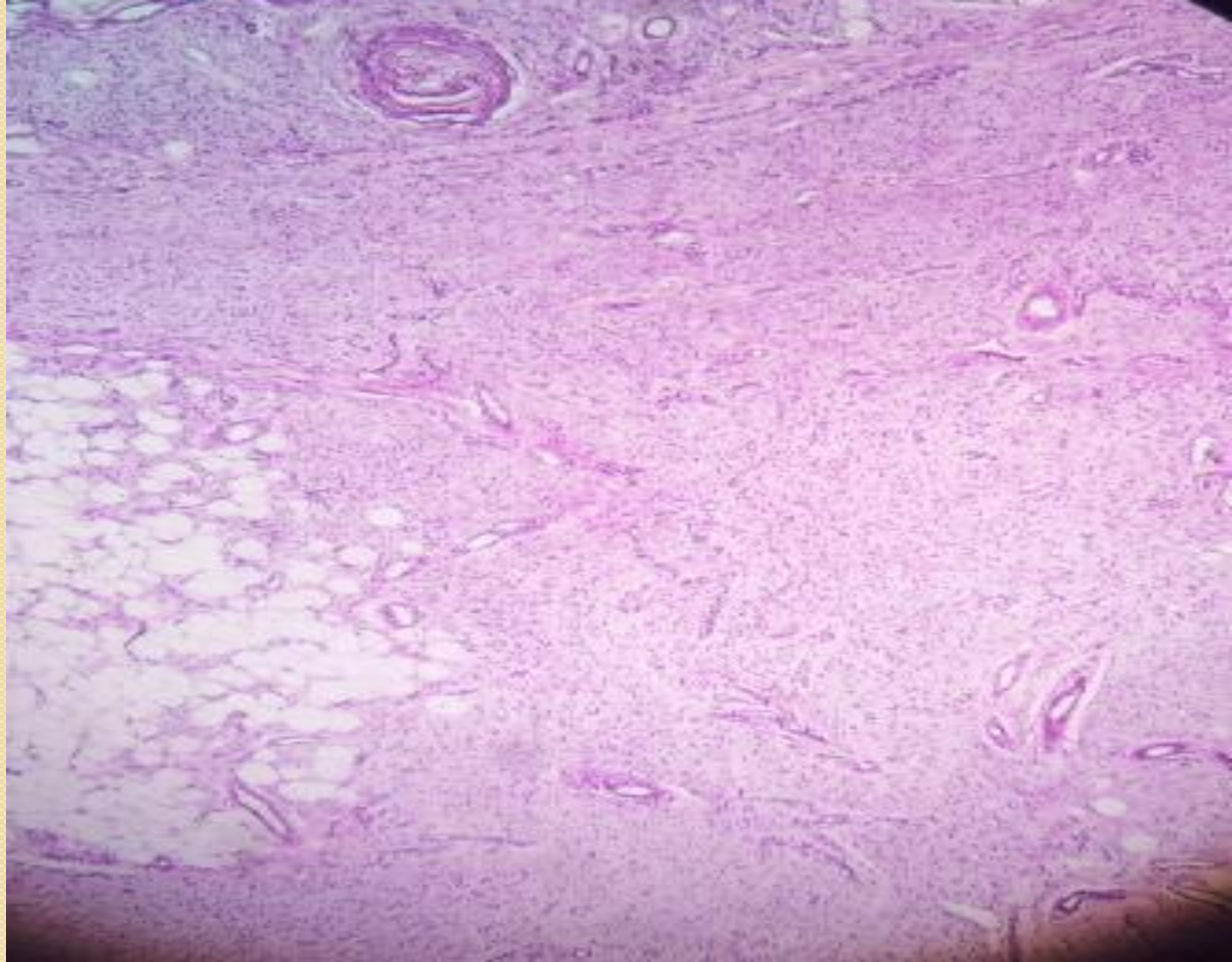


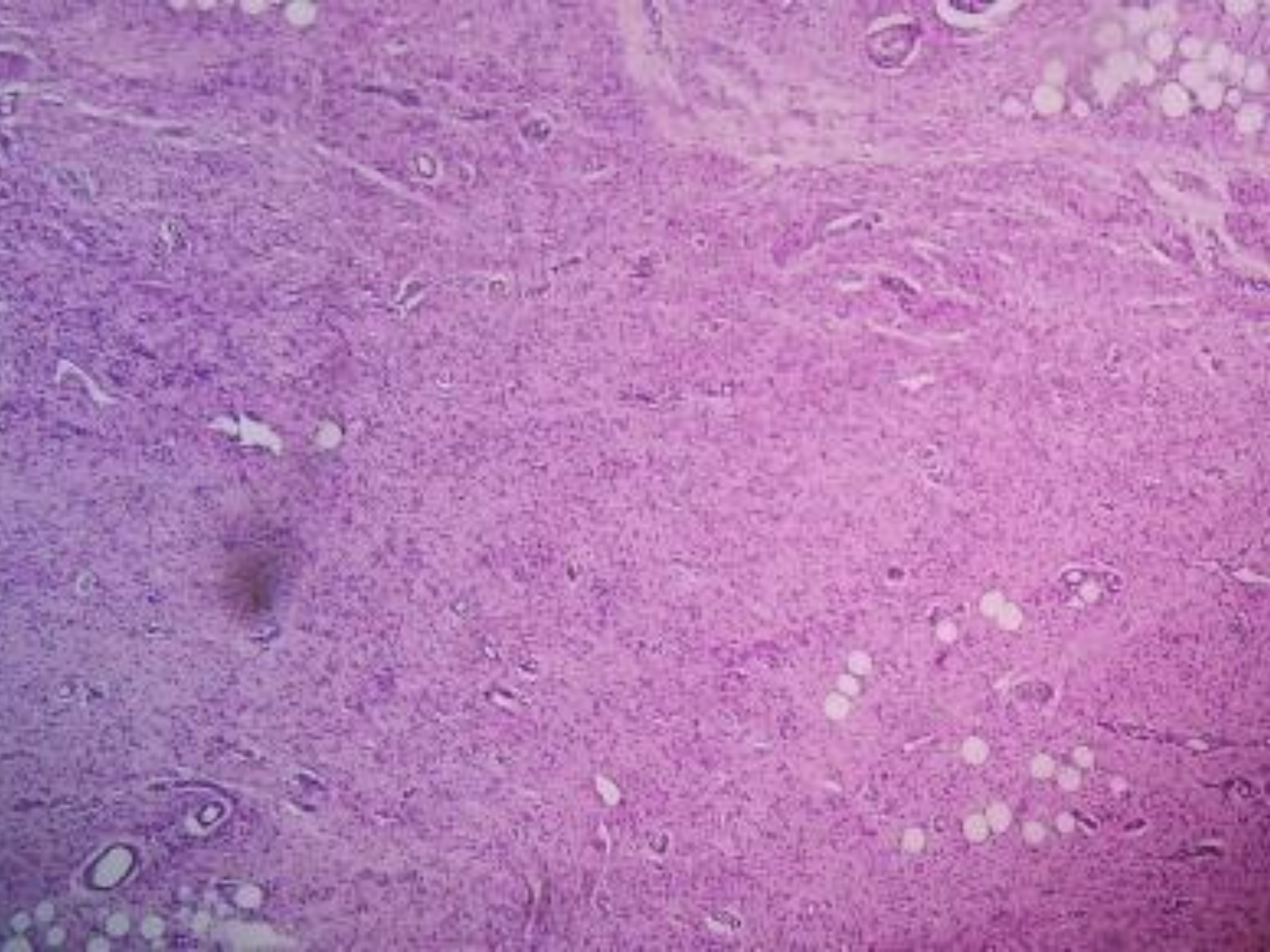


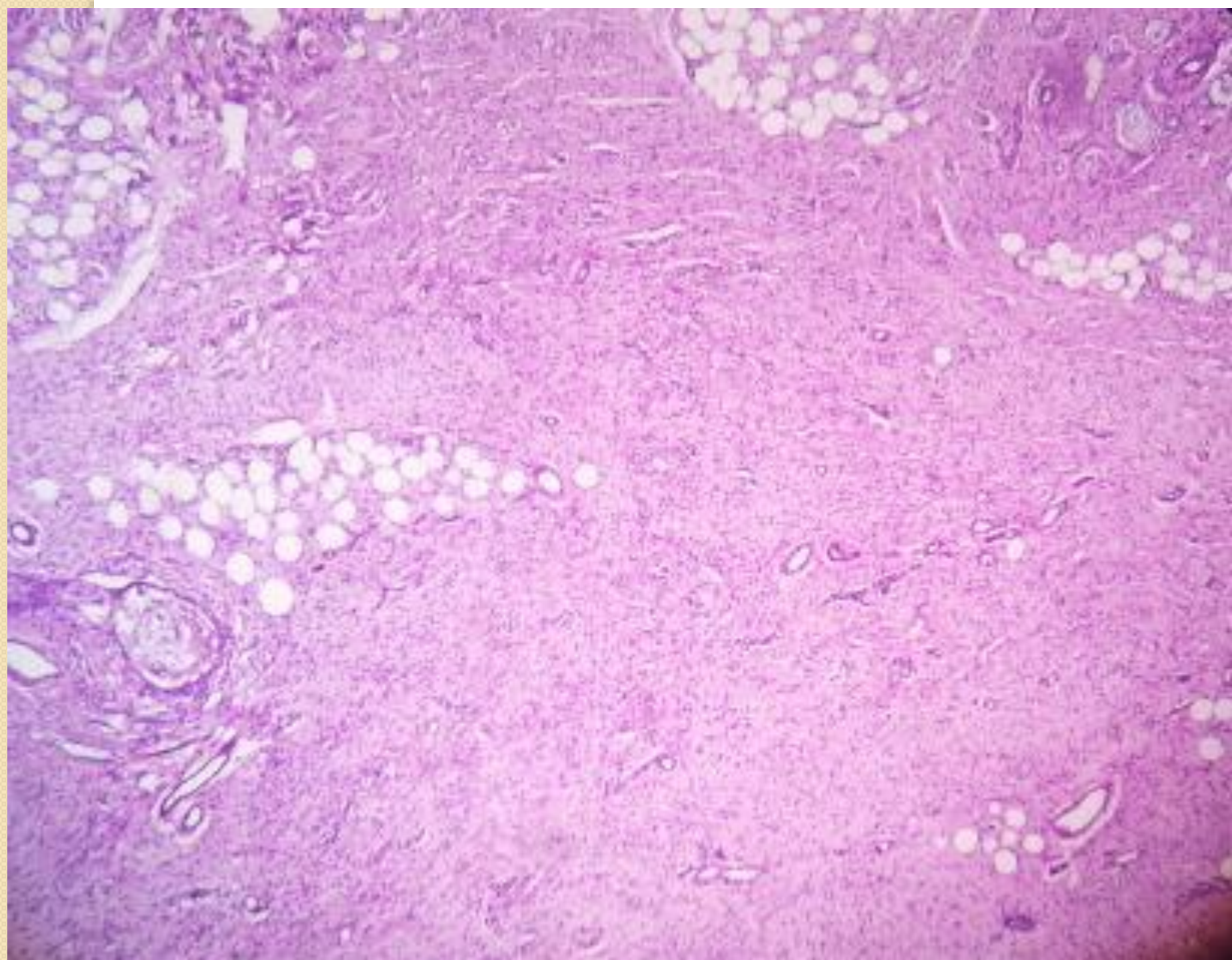


- 
- **8Y. mass at the left ankle joint.**

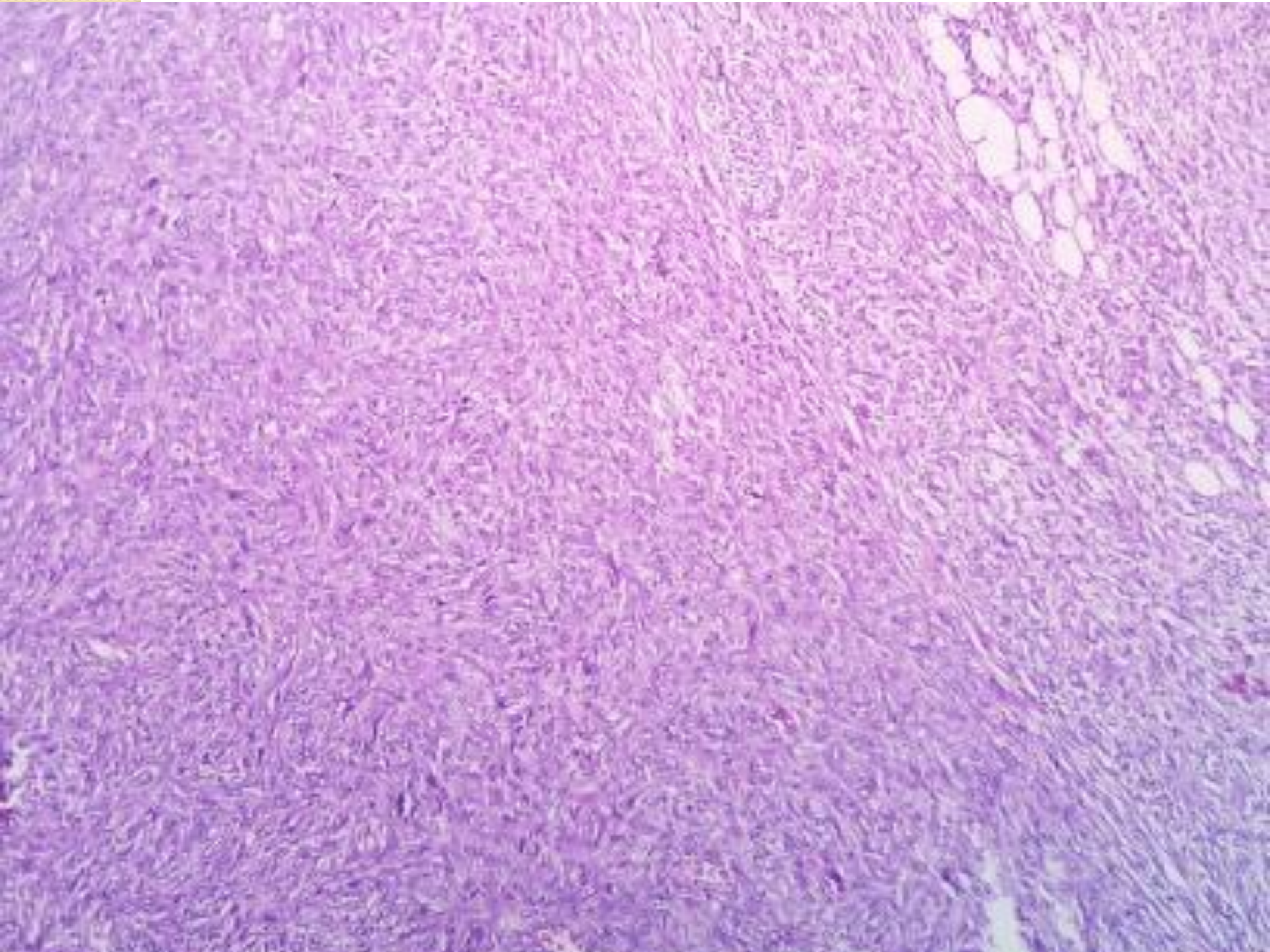


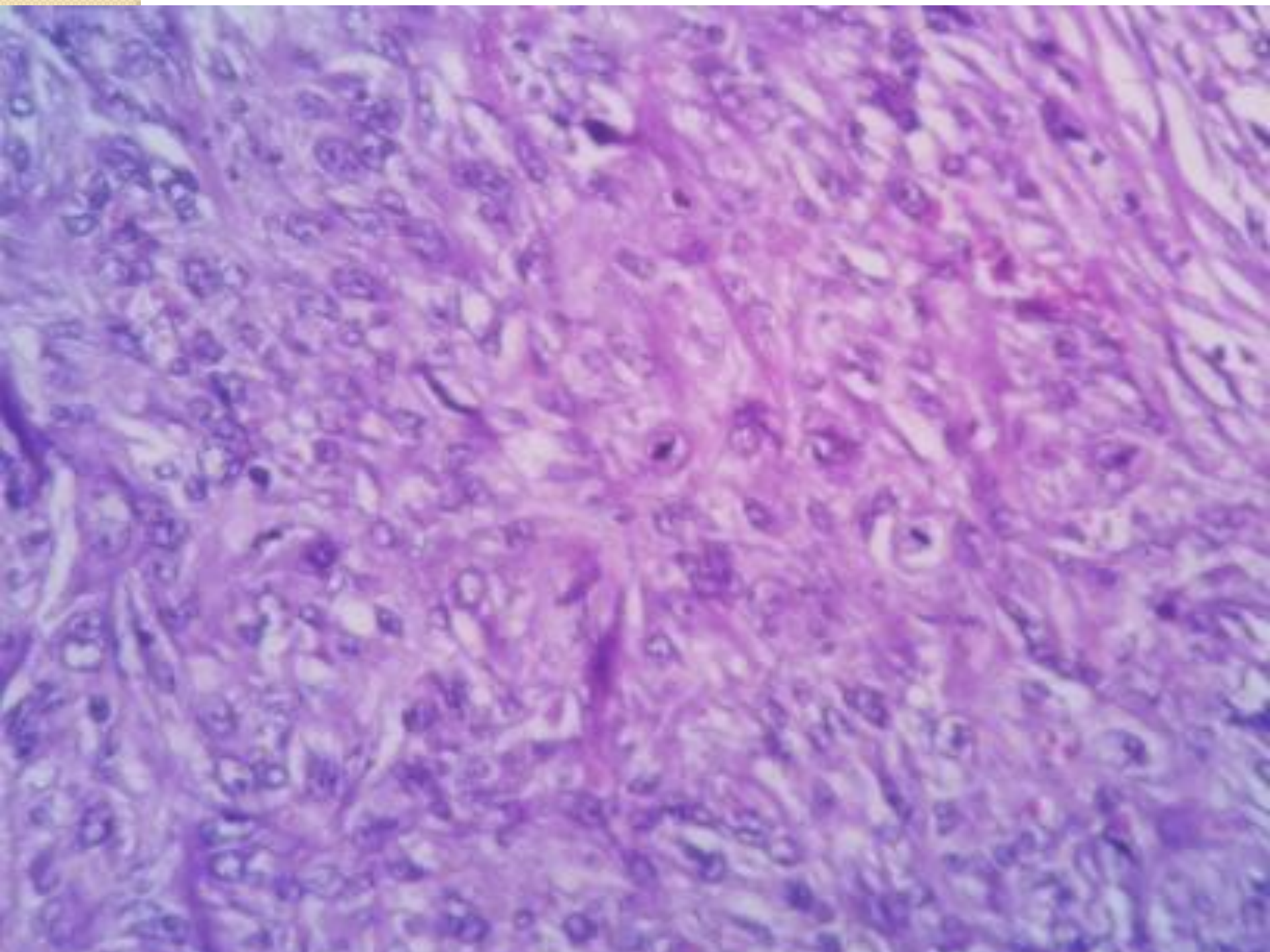


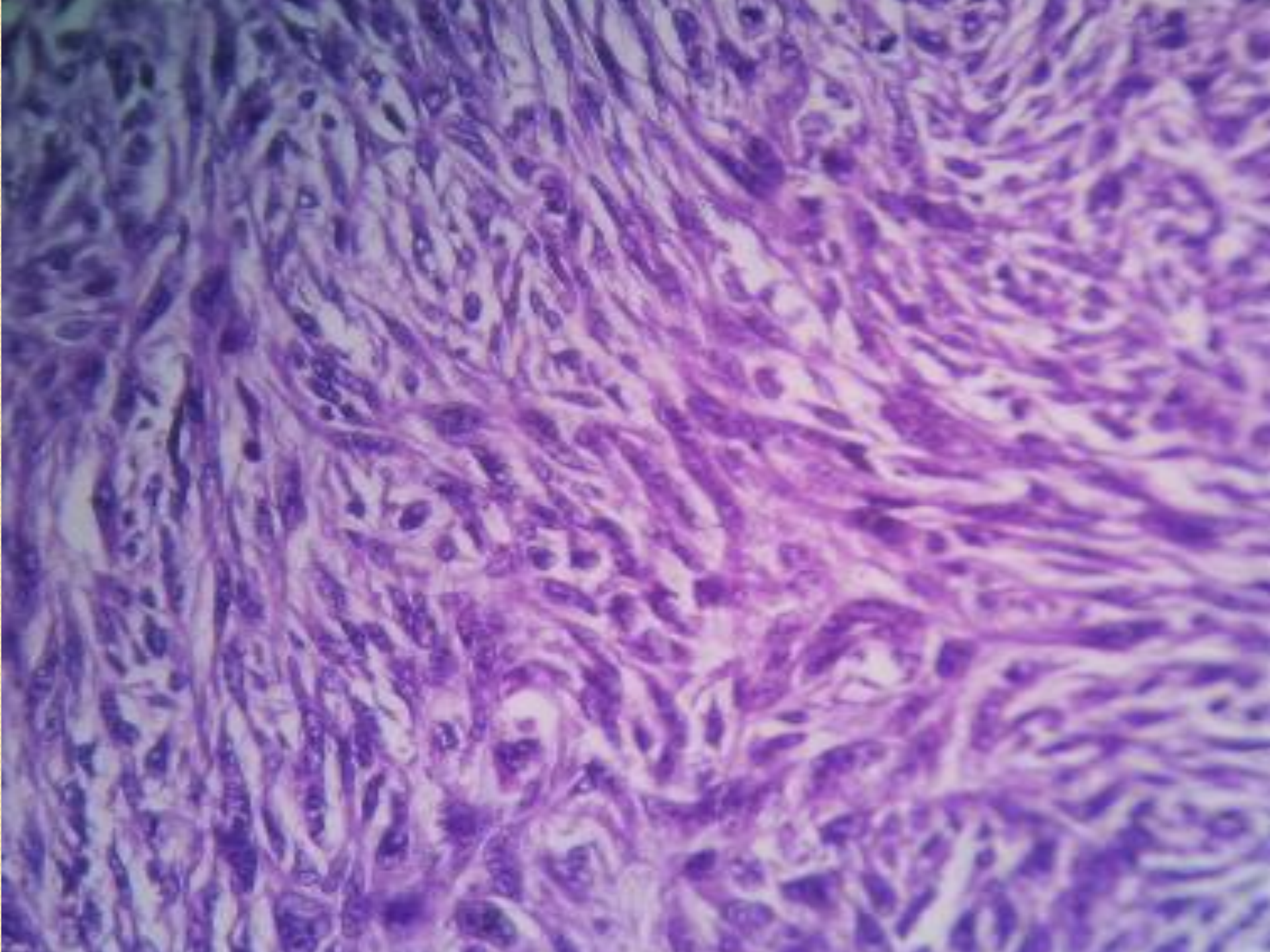


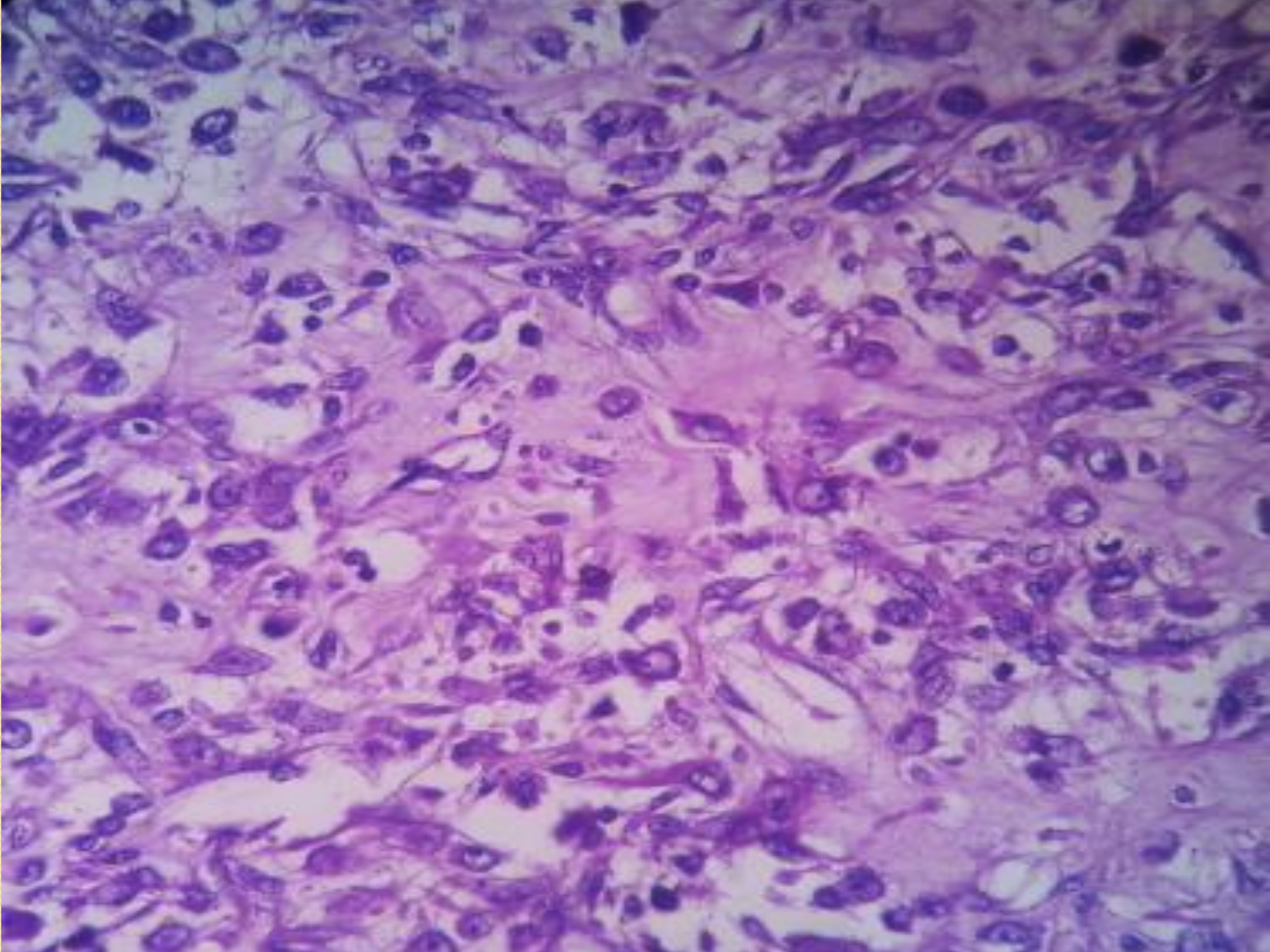


- 
- **50 Y.M renal mass (nephrectomy).**











THANK  
YOU

