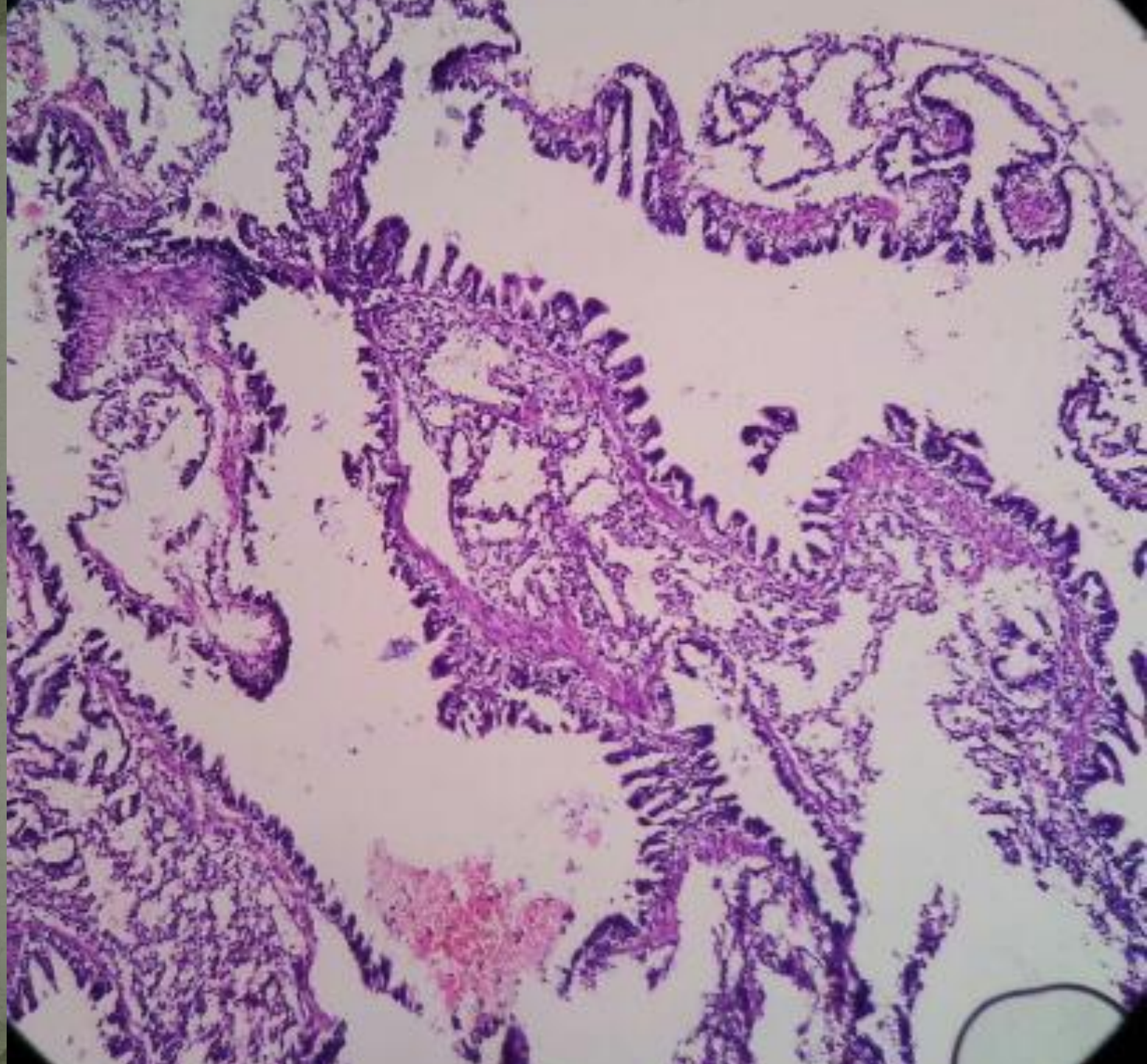
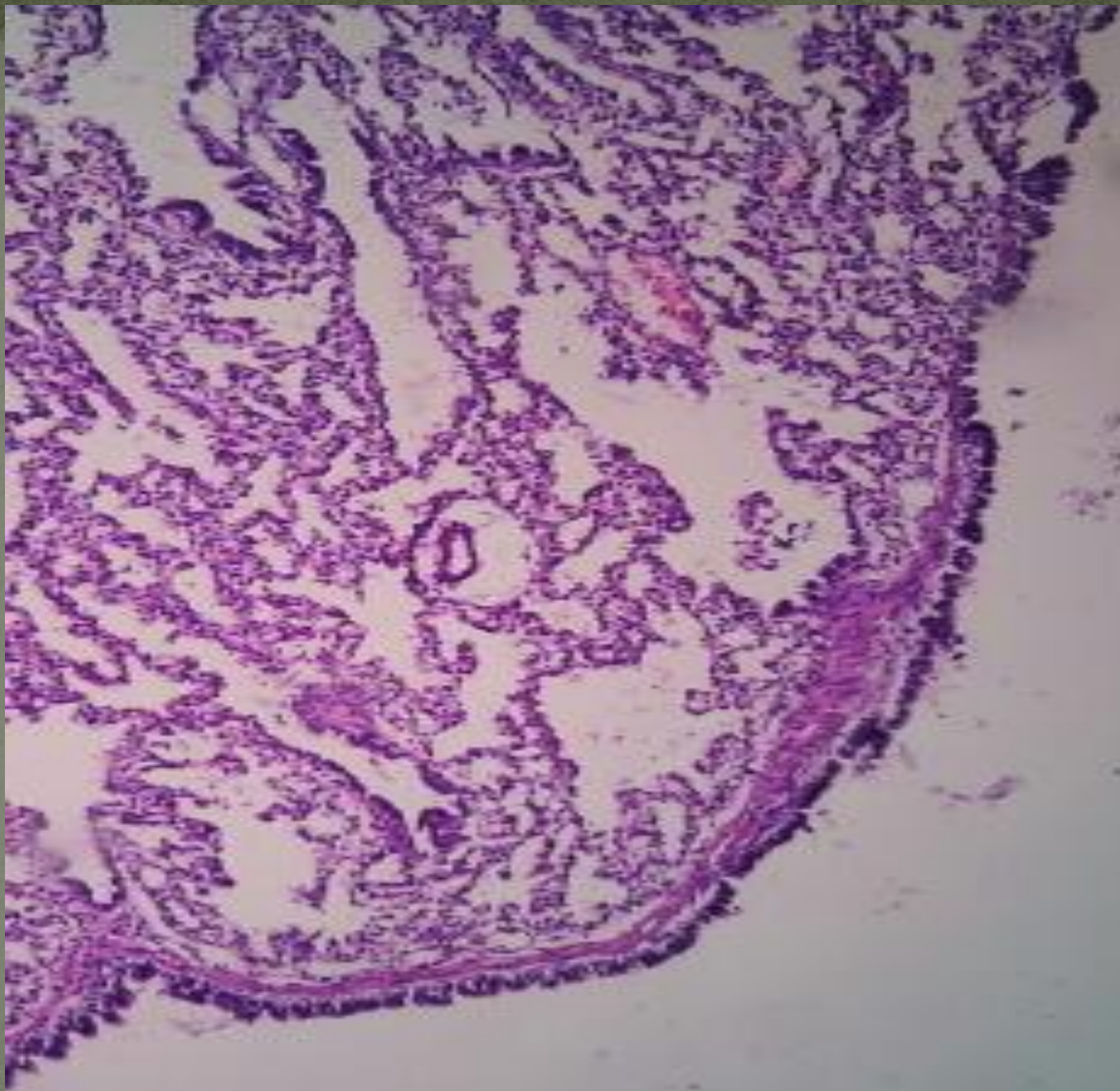


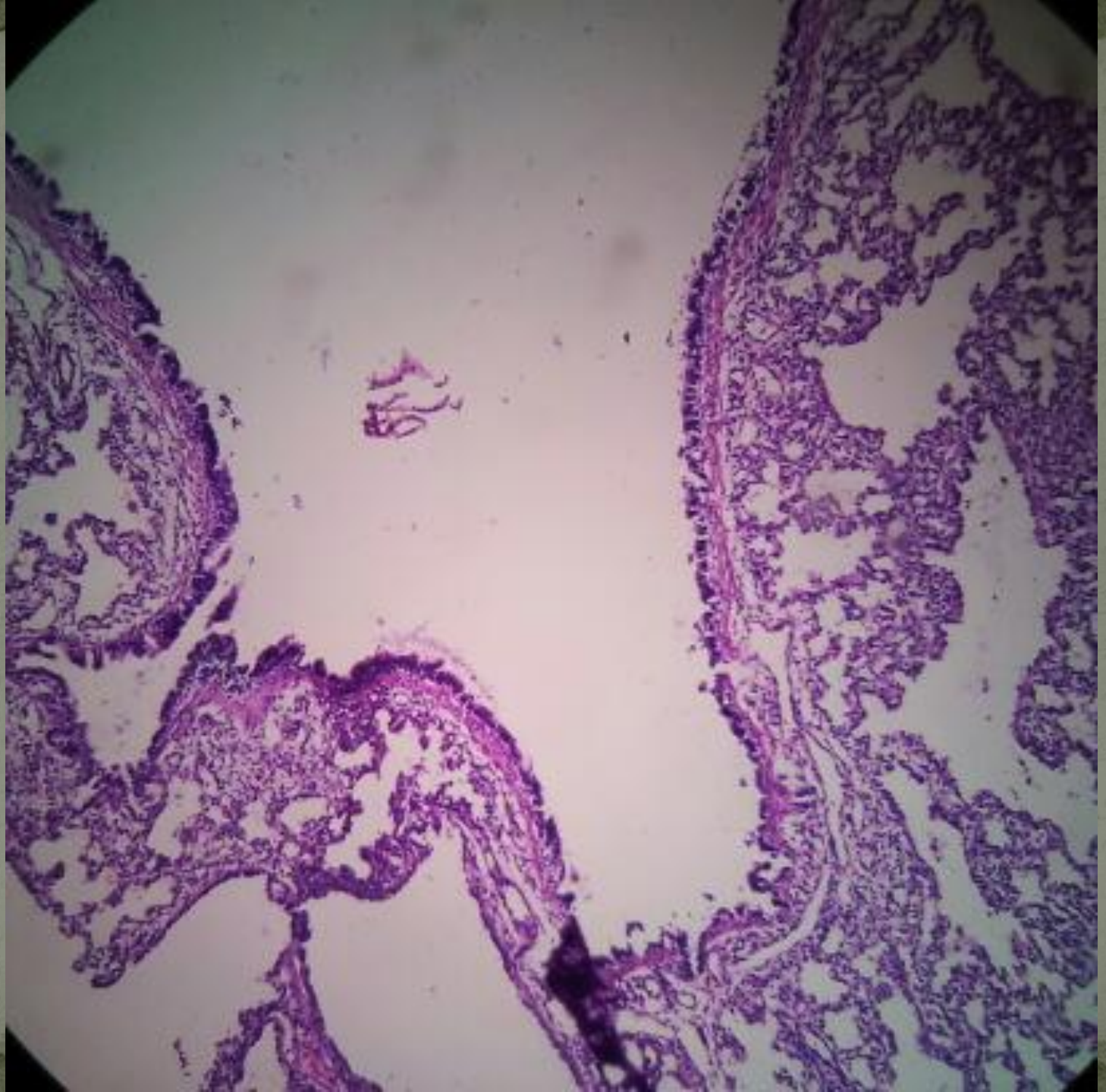
# 4<sup>th</sup> Slide Meeting

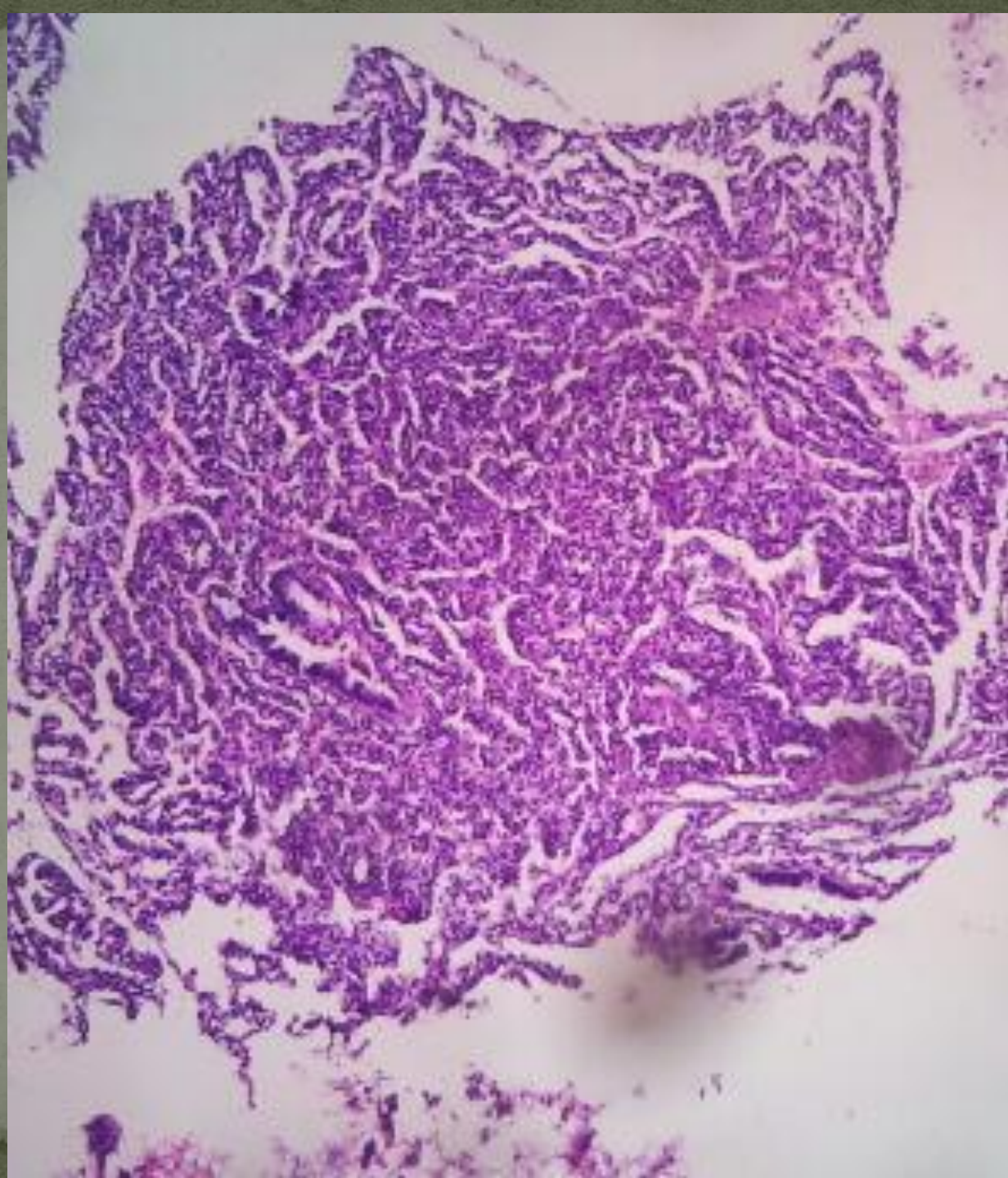
---

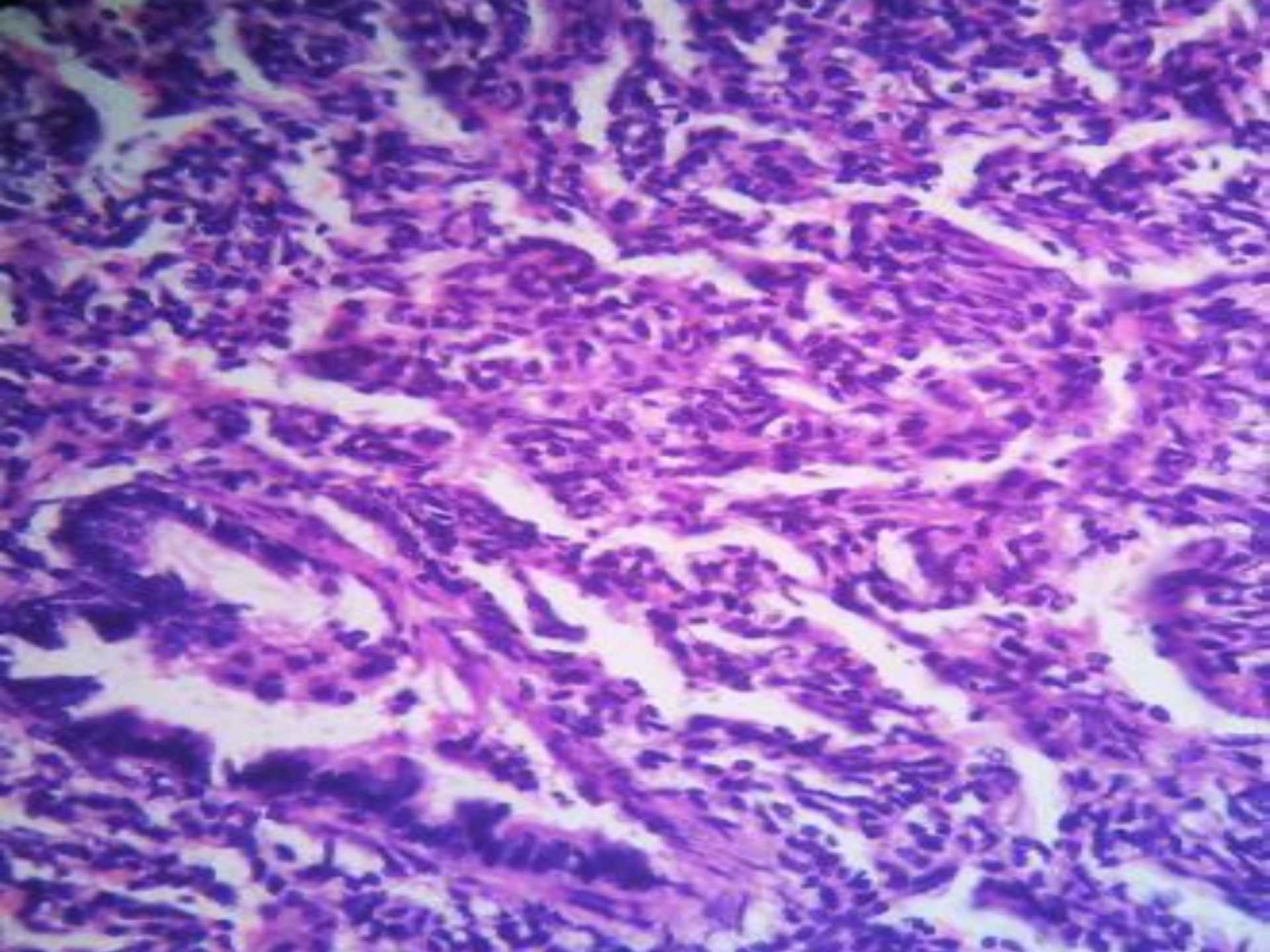
- 20 days Male with emphysematous lower lobe of left ung.

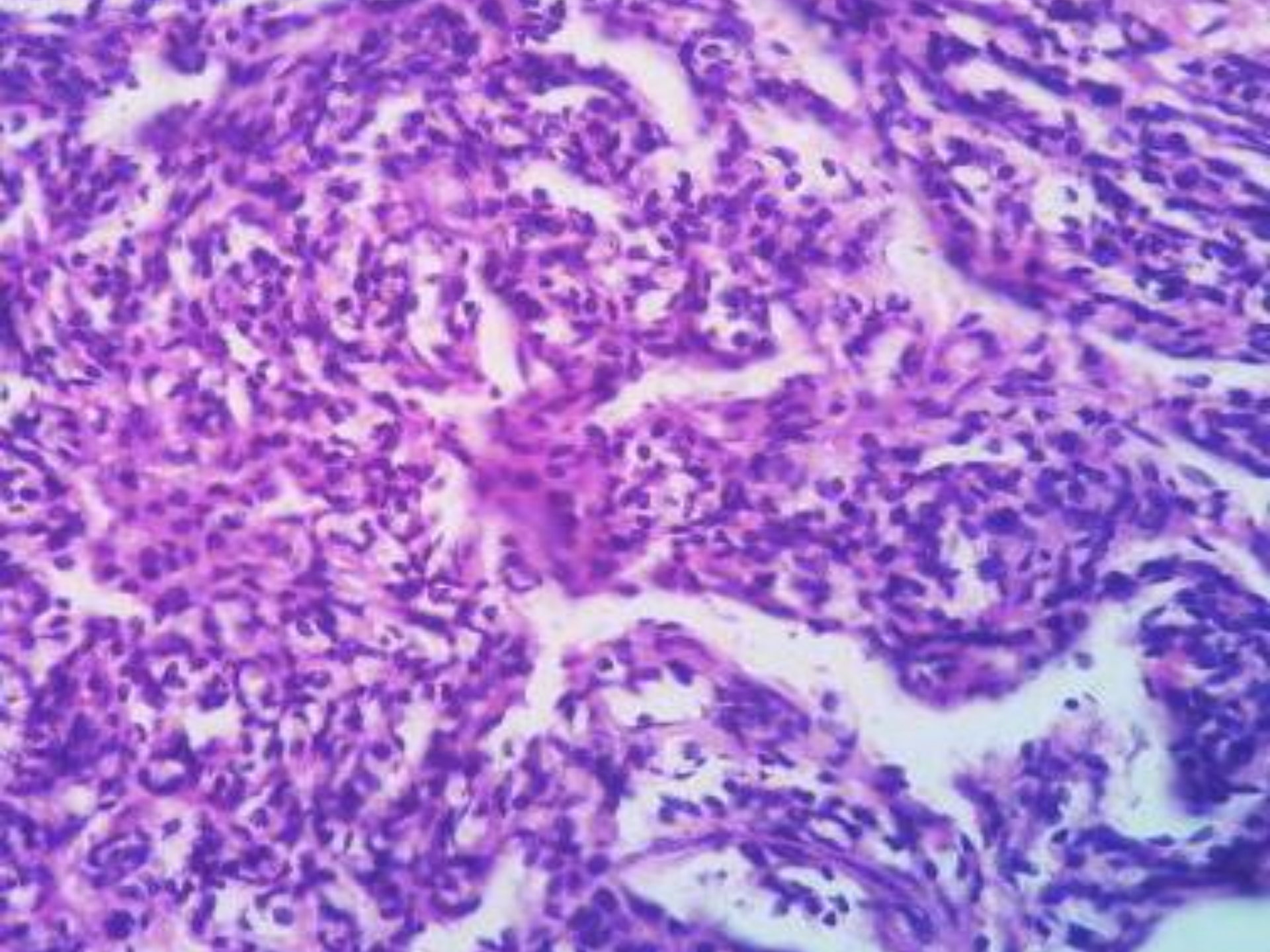






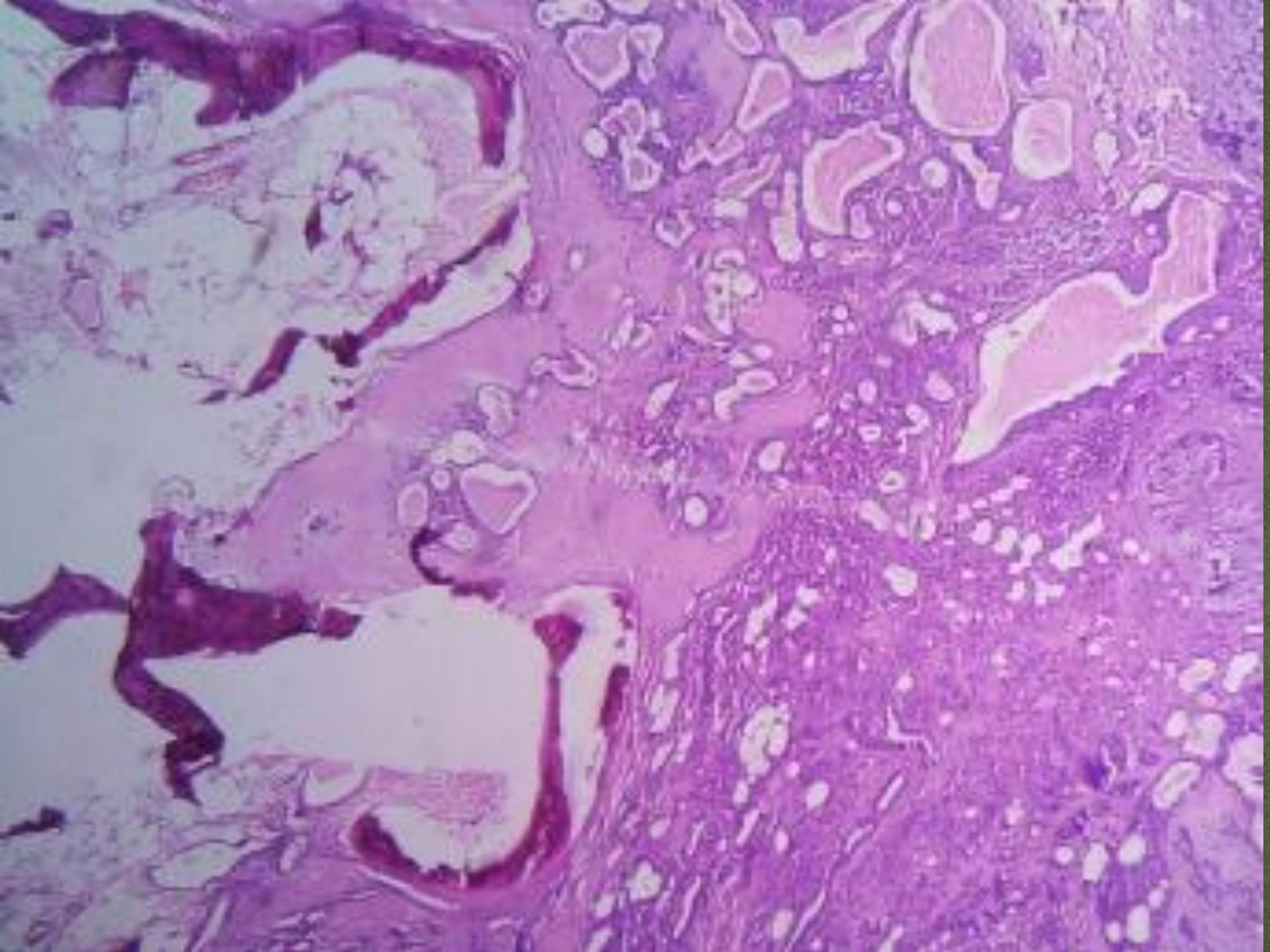


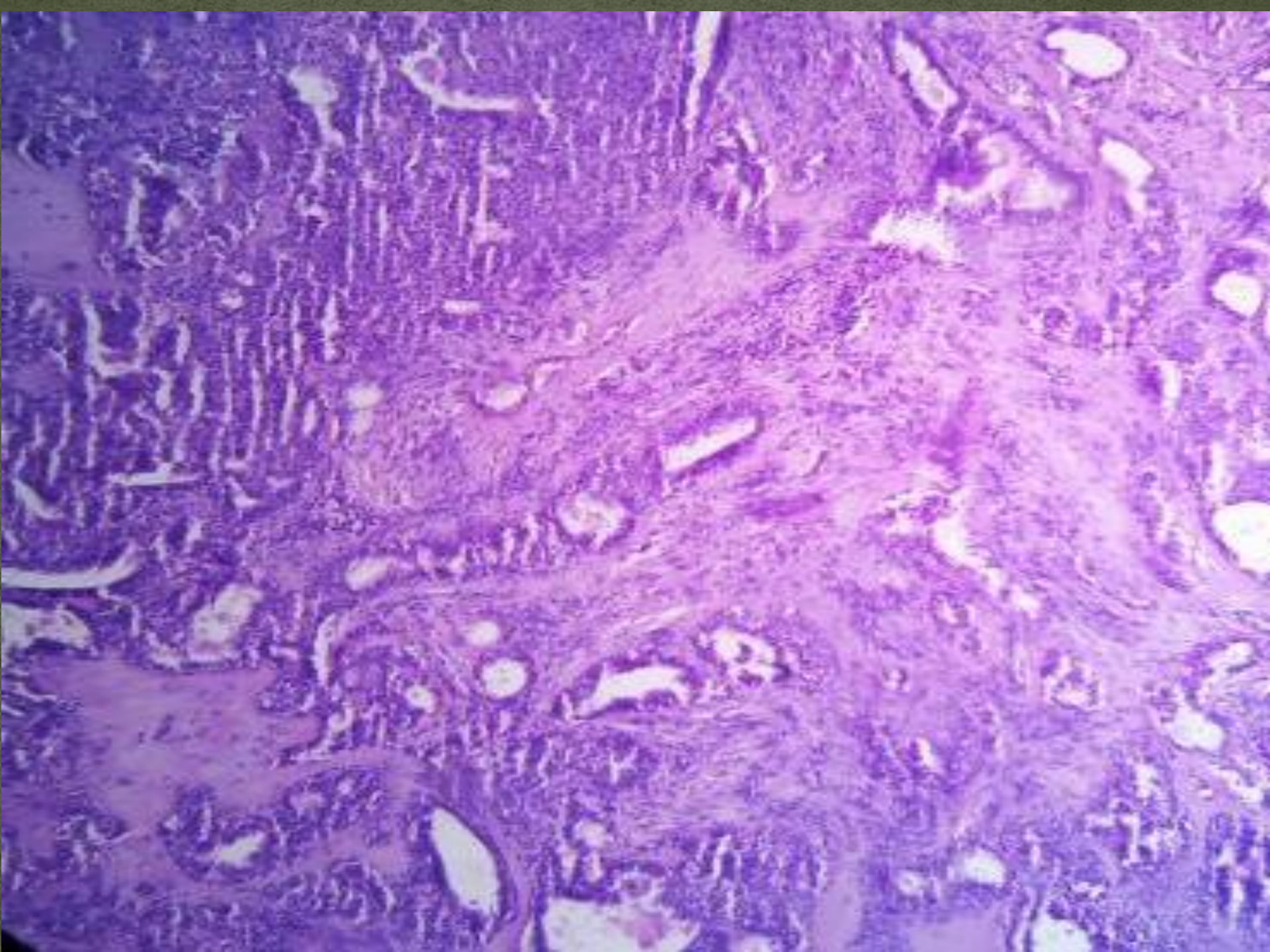


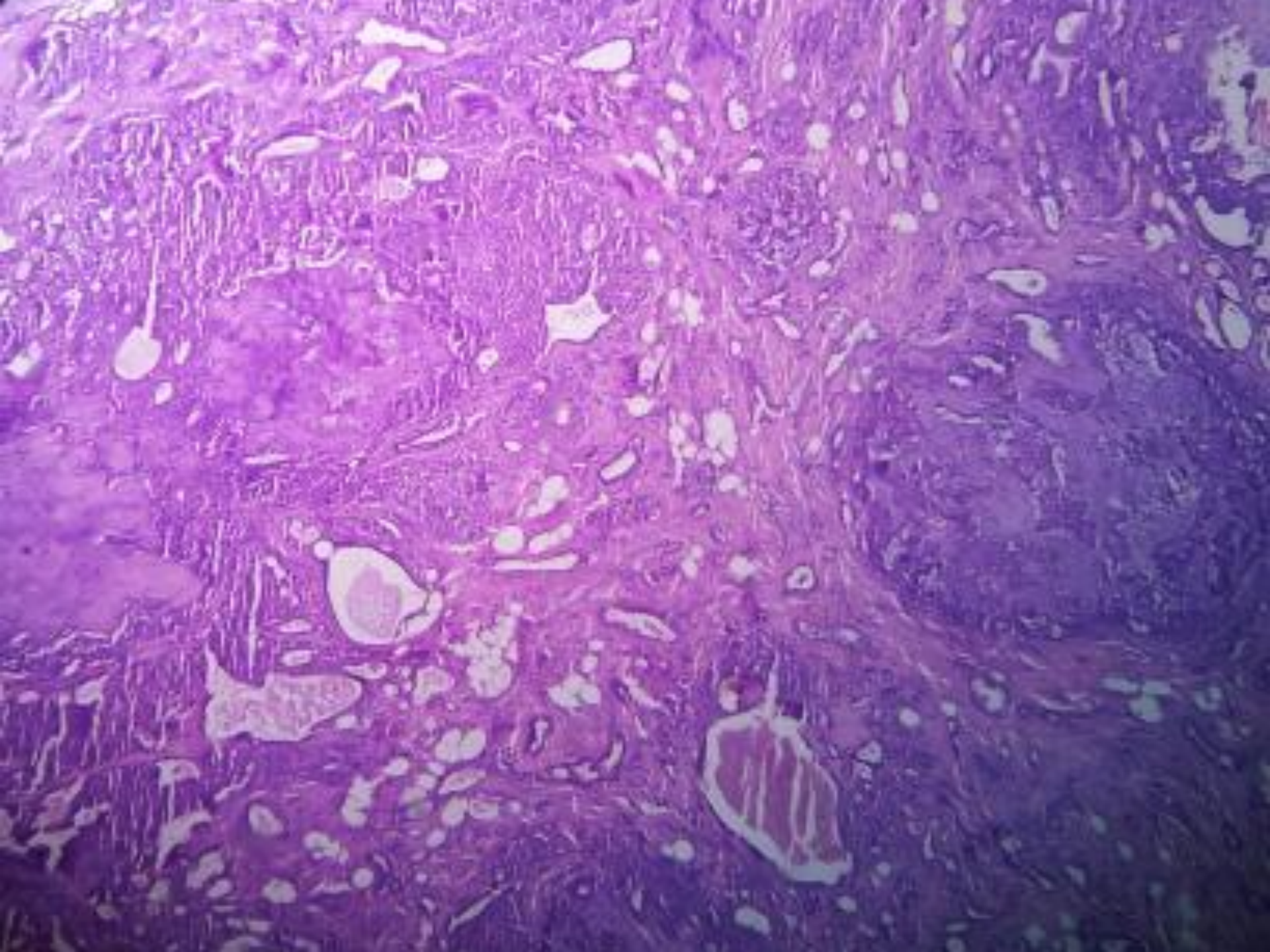


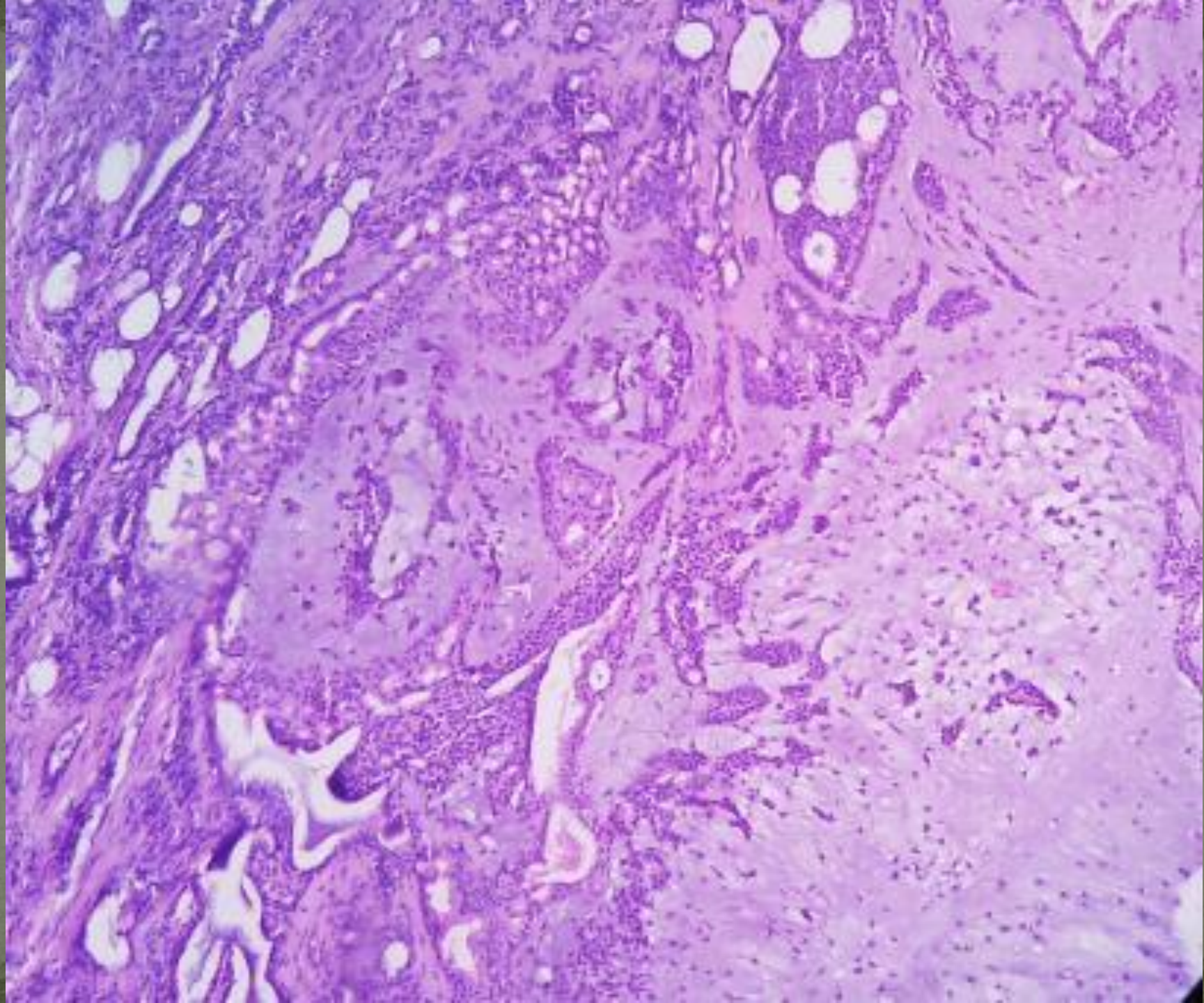


- 55 Y.F. Mass at inner angle of eye.

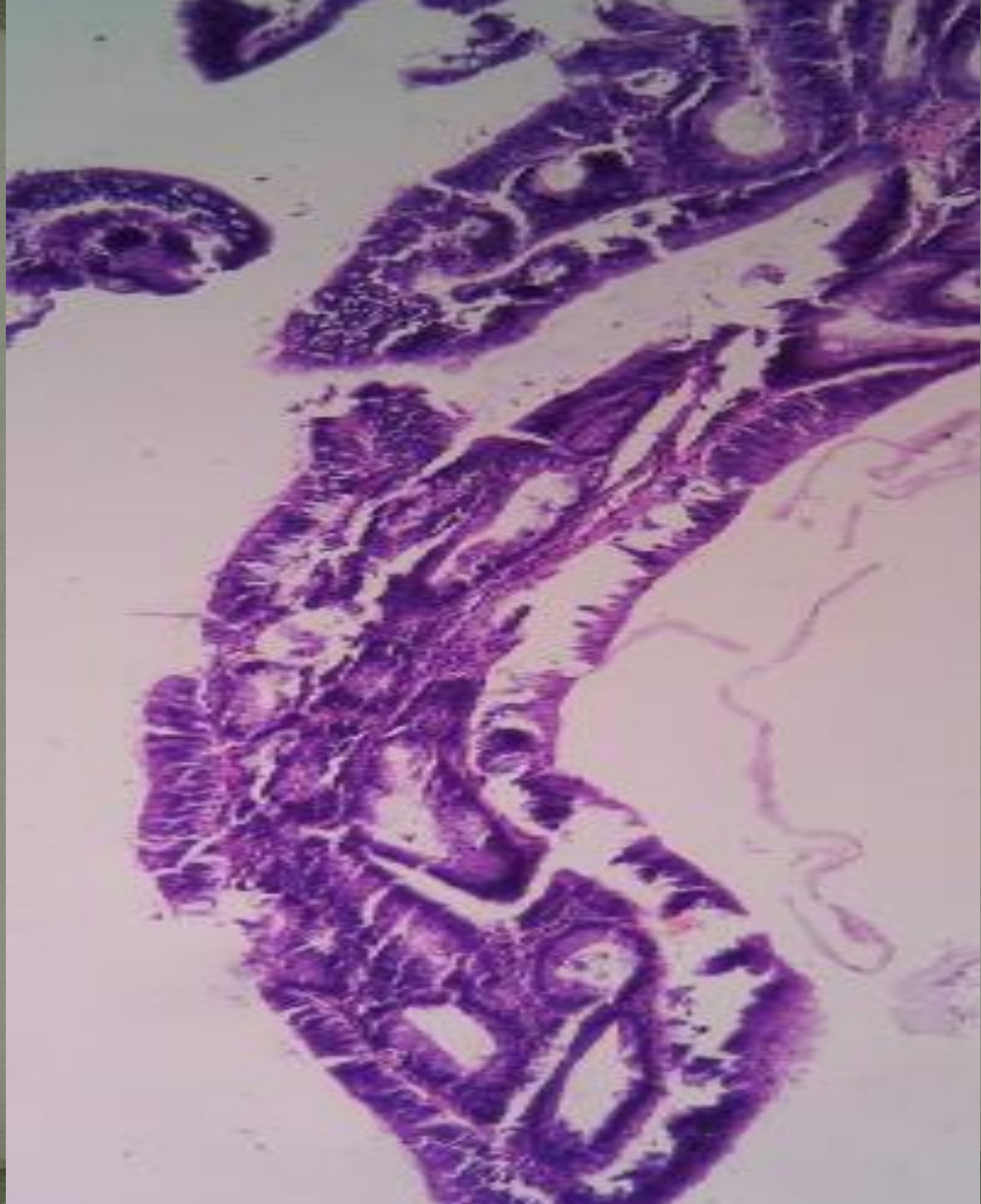


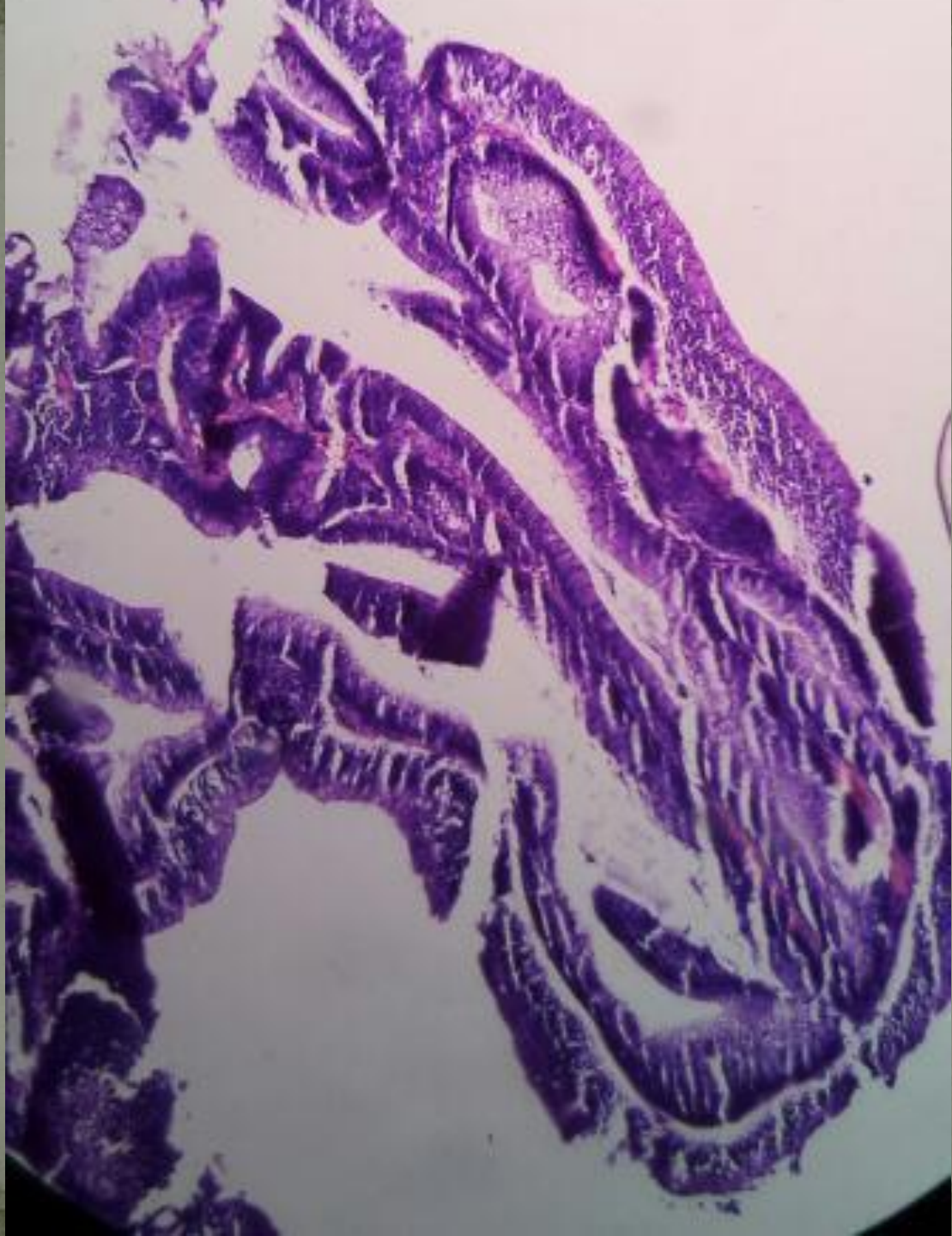




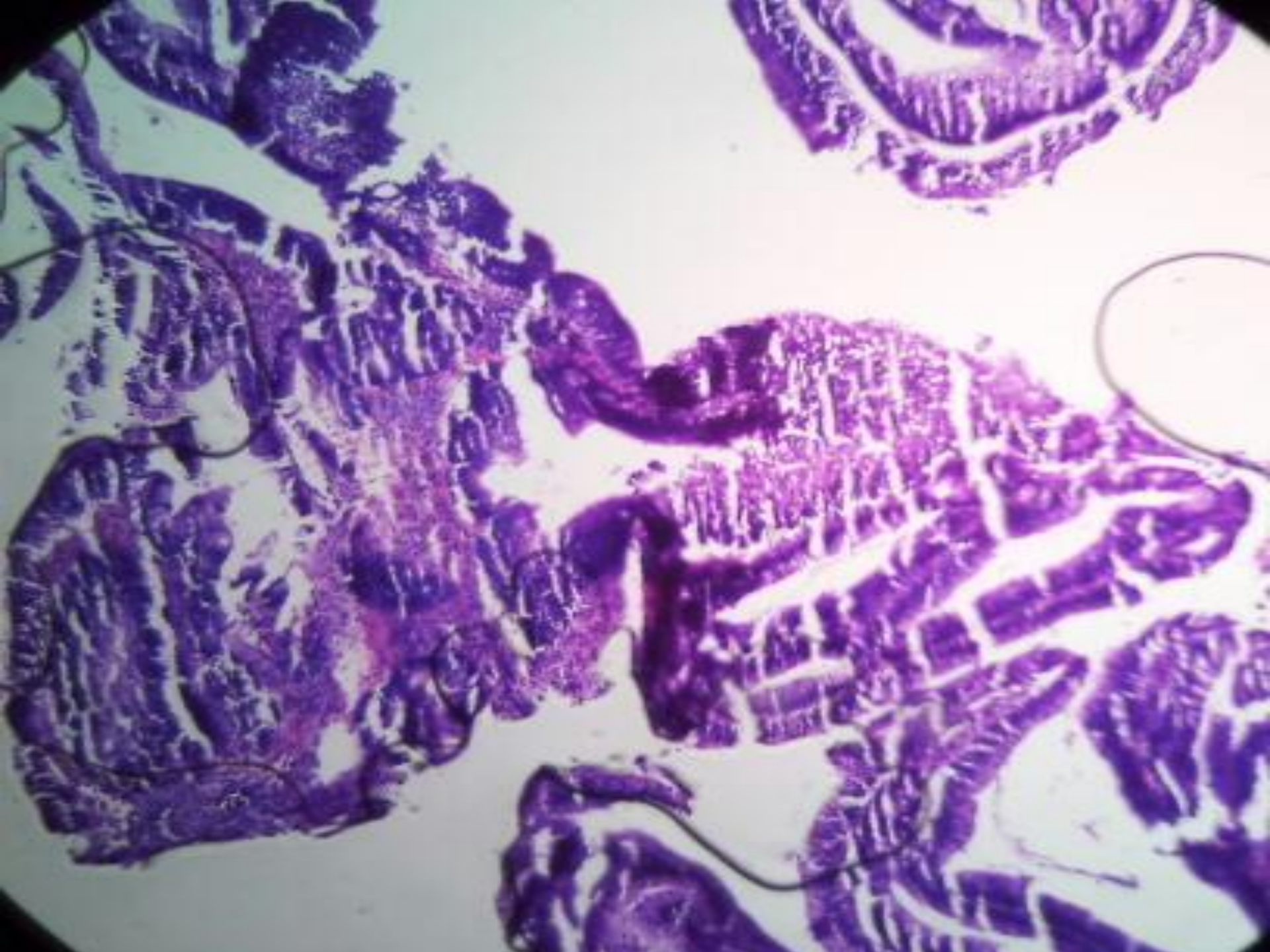


- 67 Y.M. mass at Sigmoid

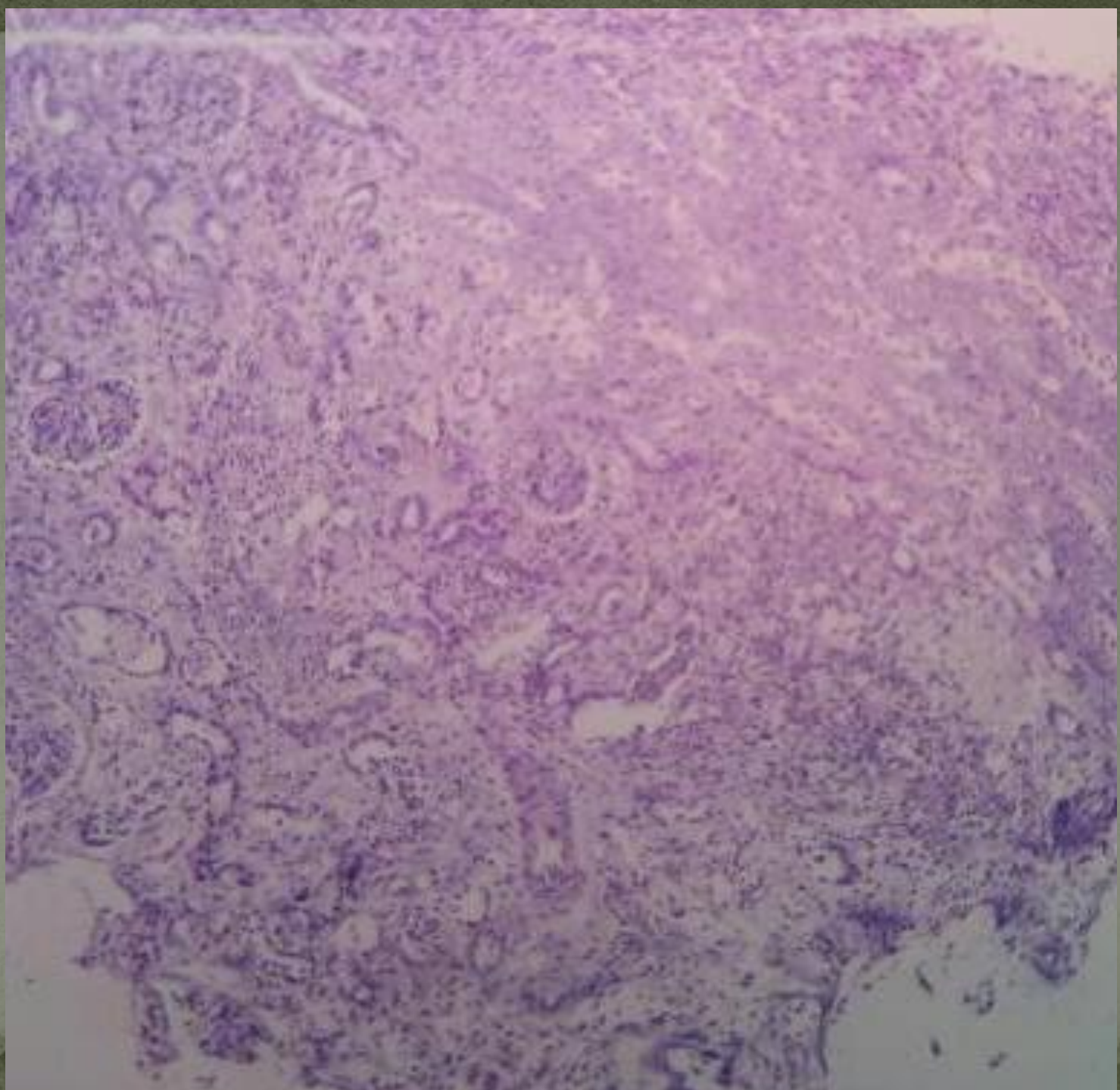


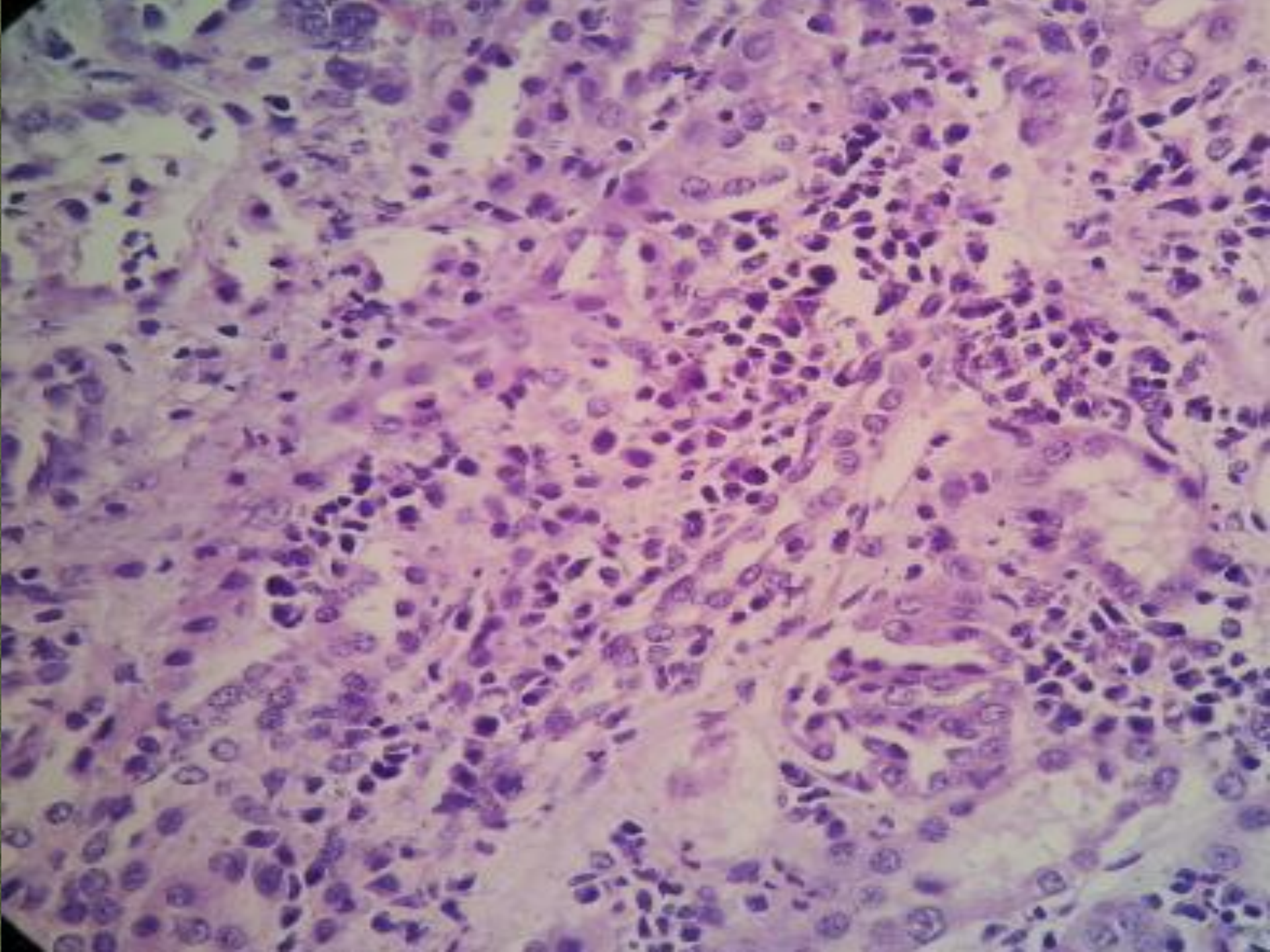


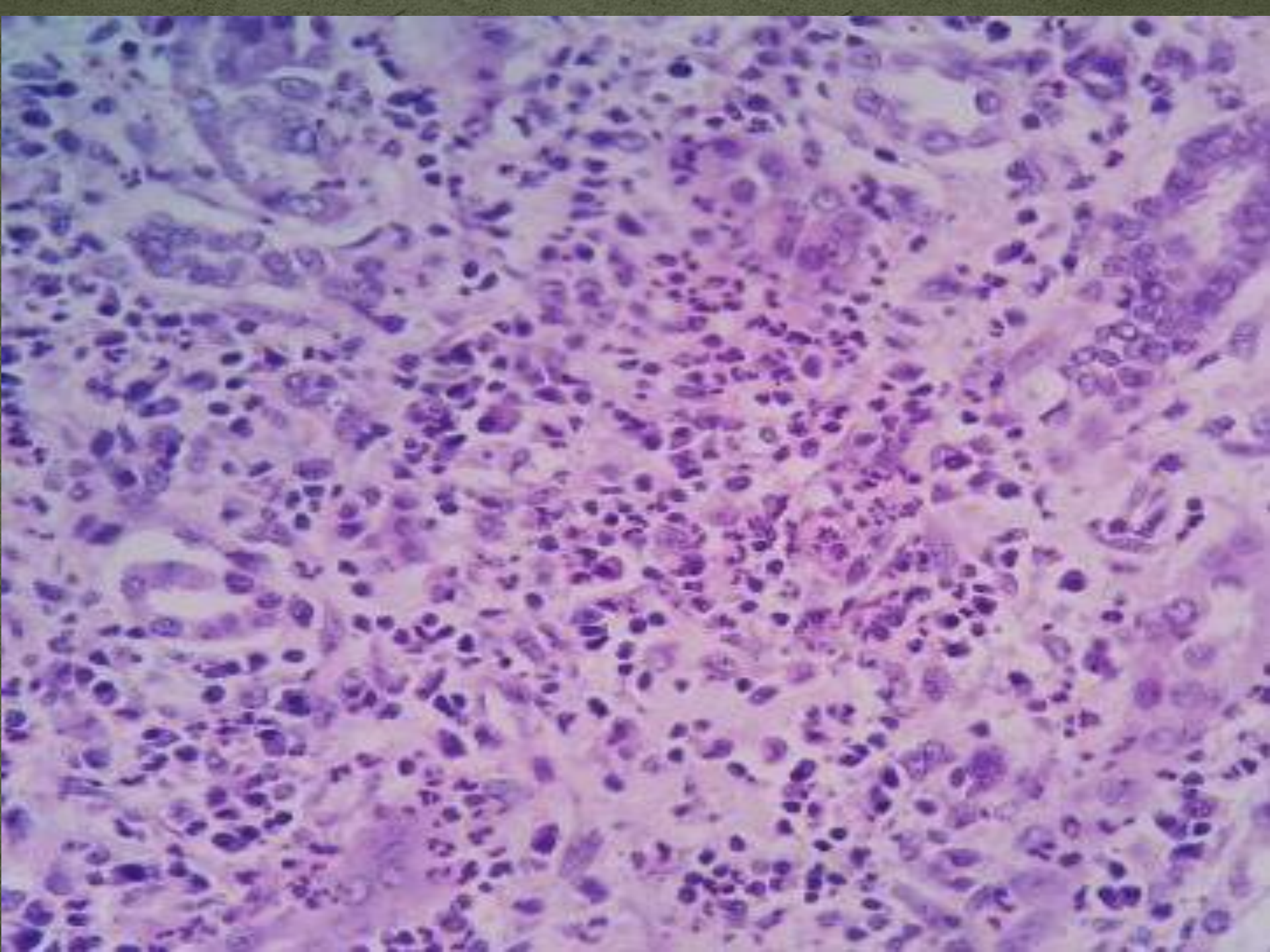


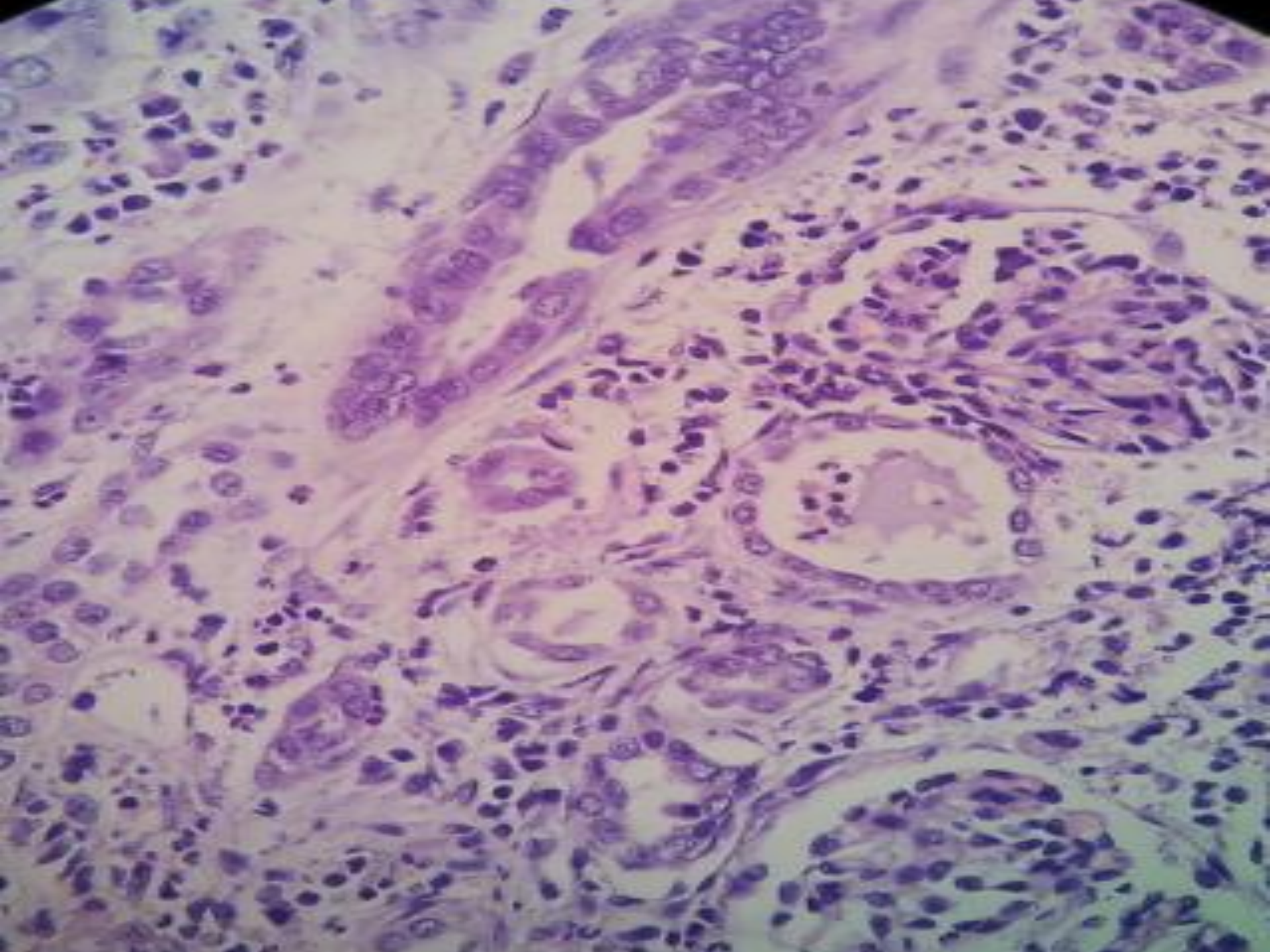


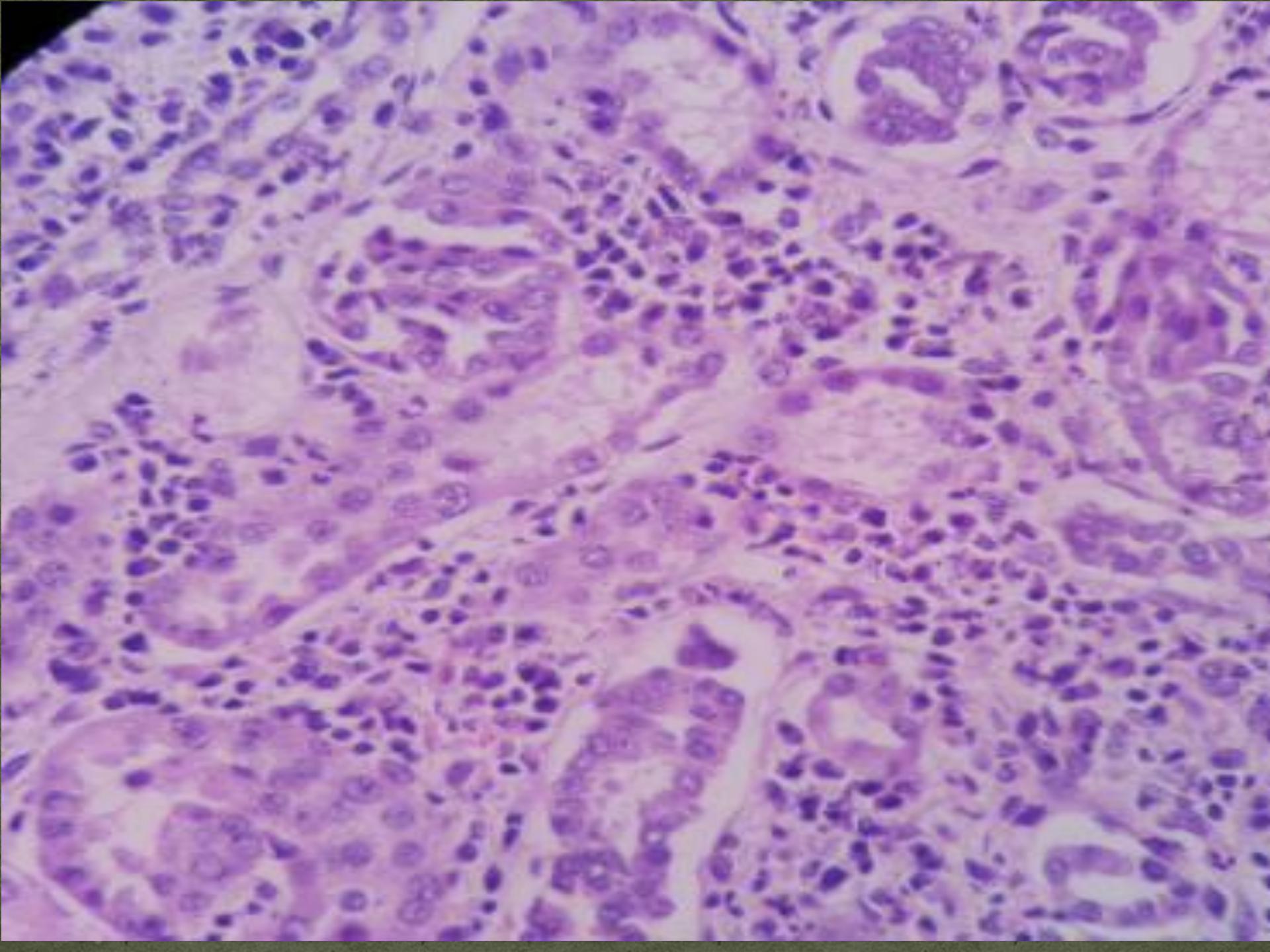
- 3/12 F. with non-functioning kidney.

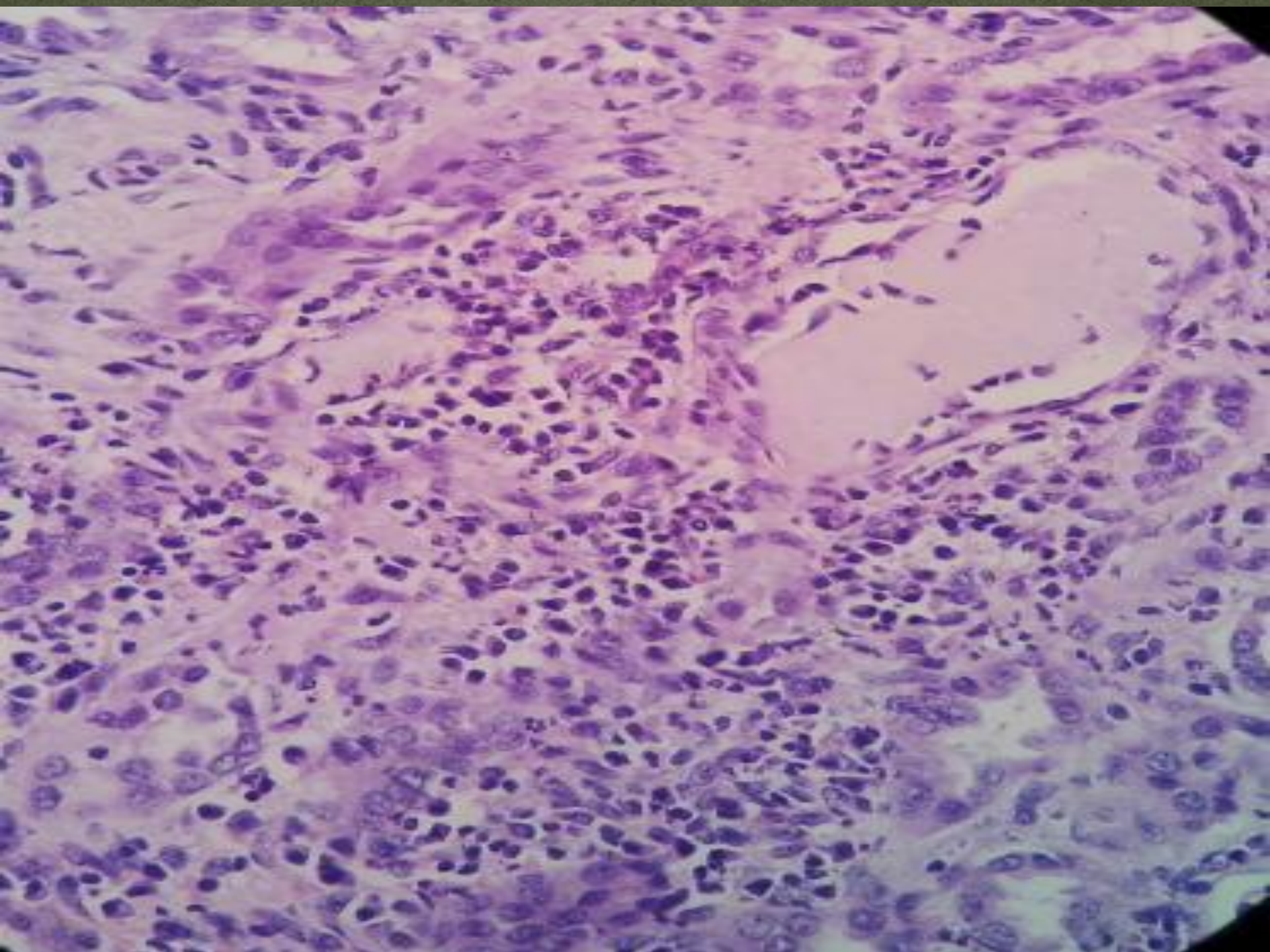






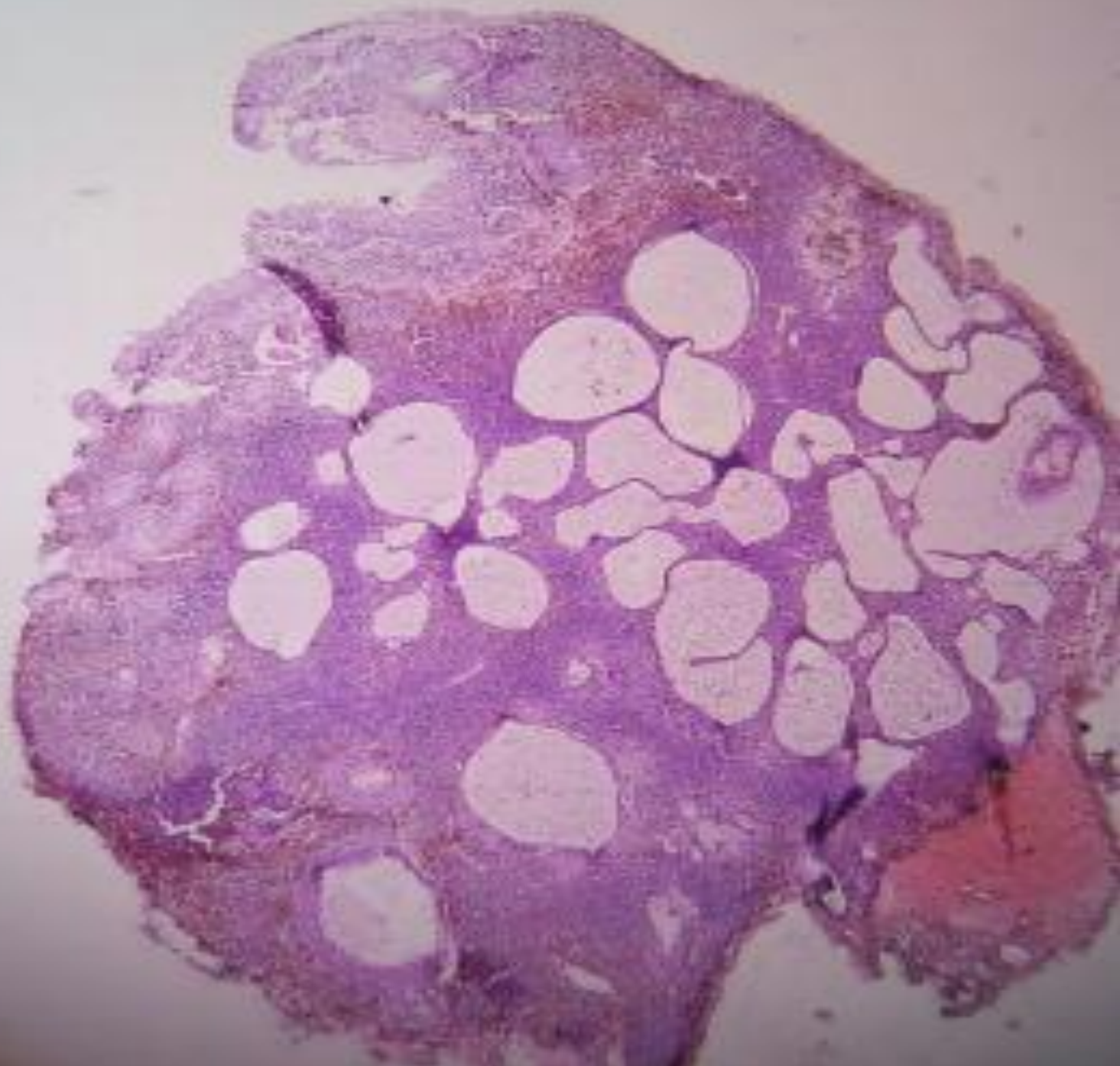


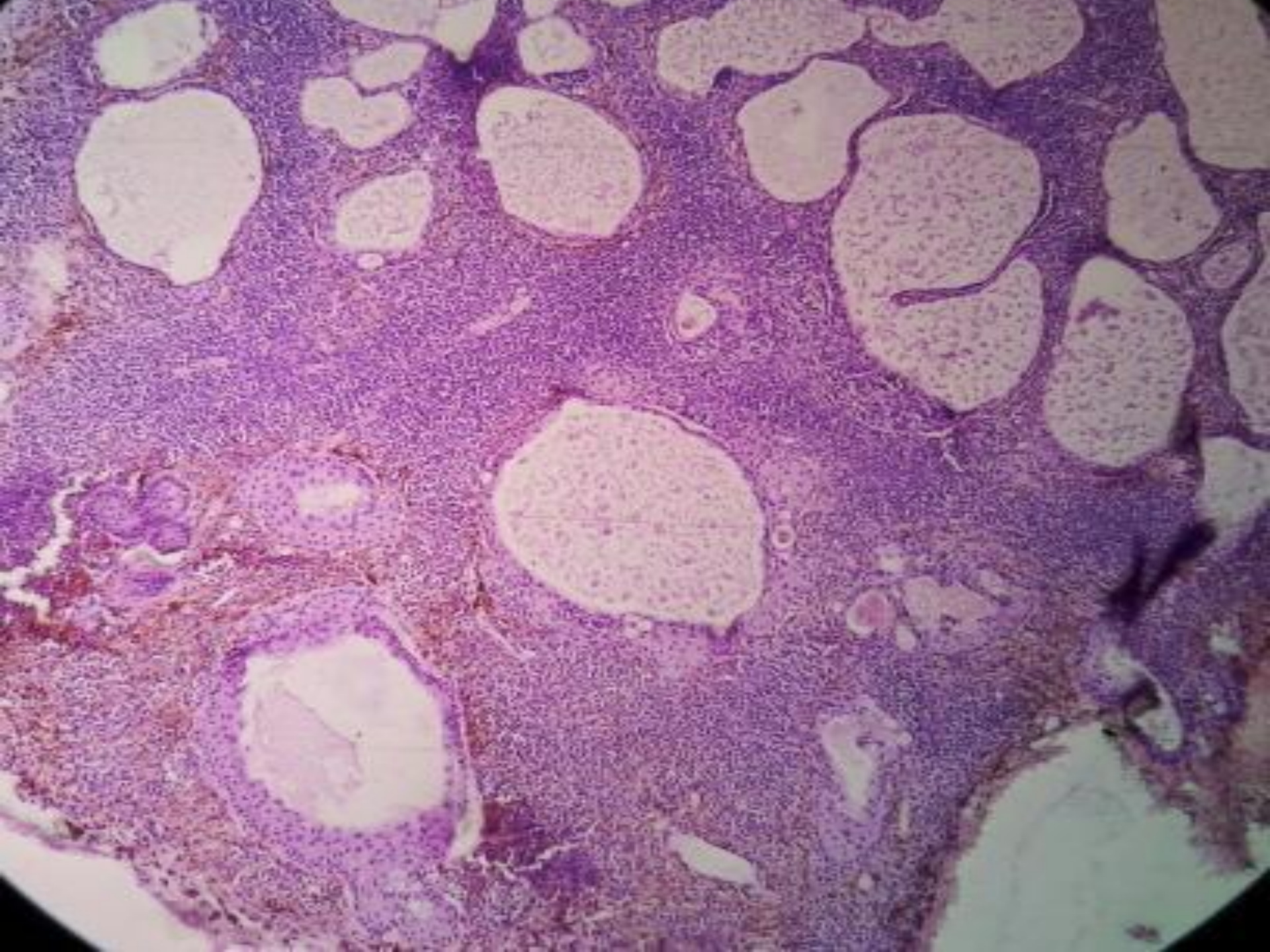


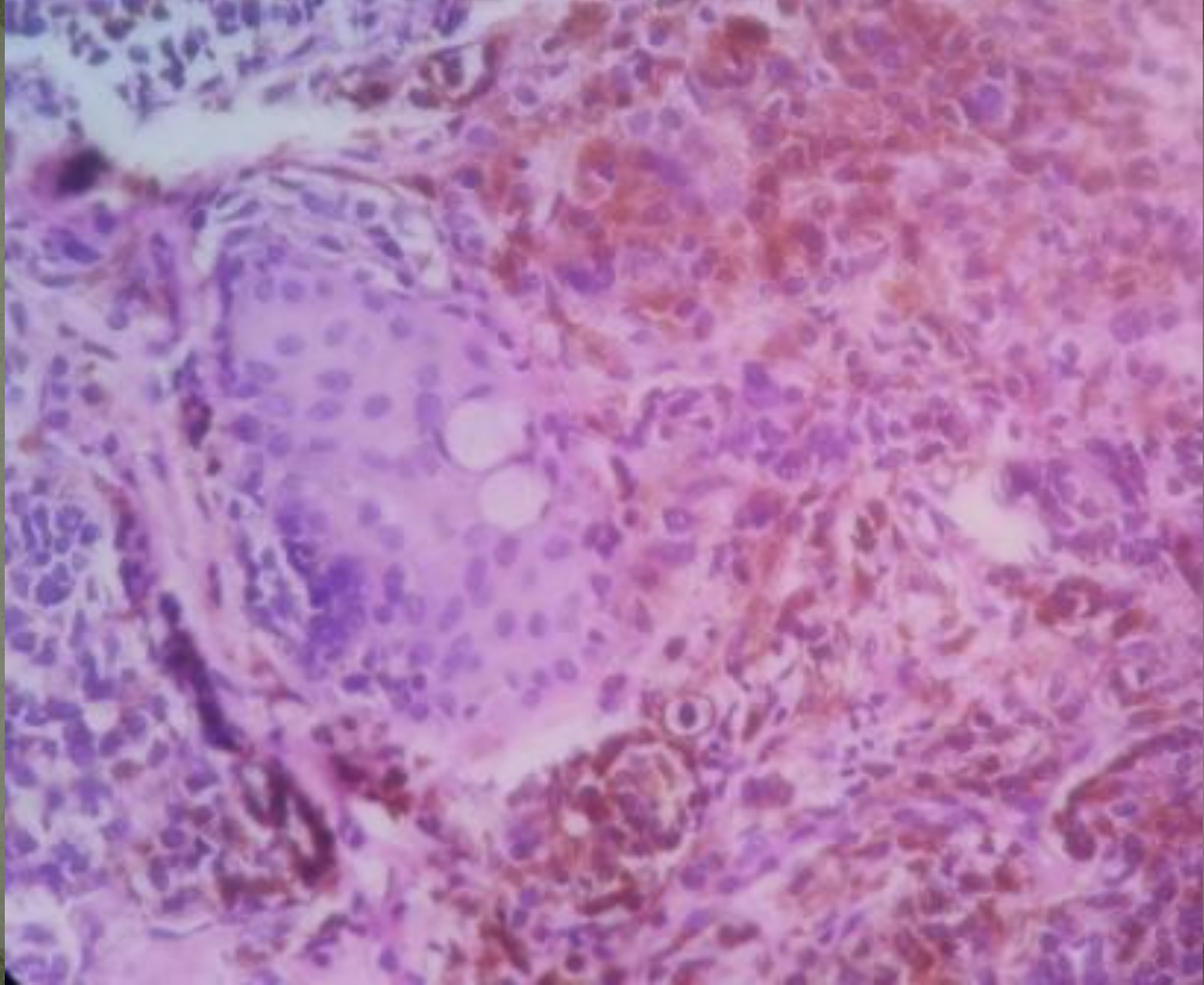


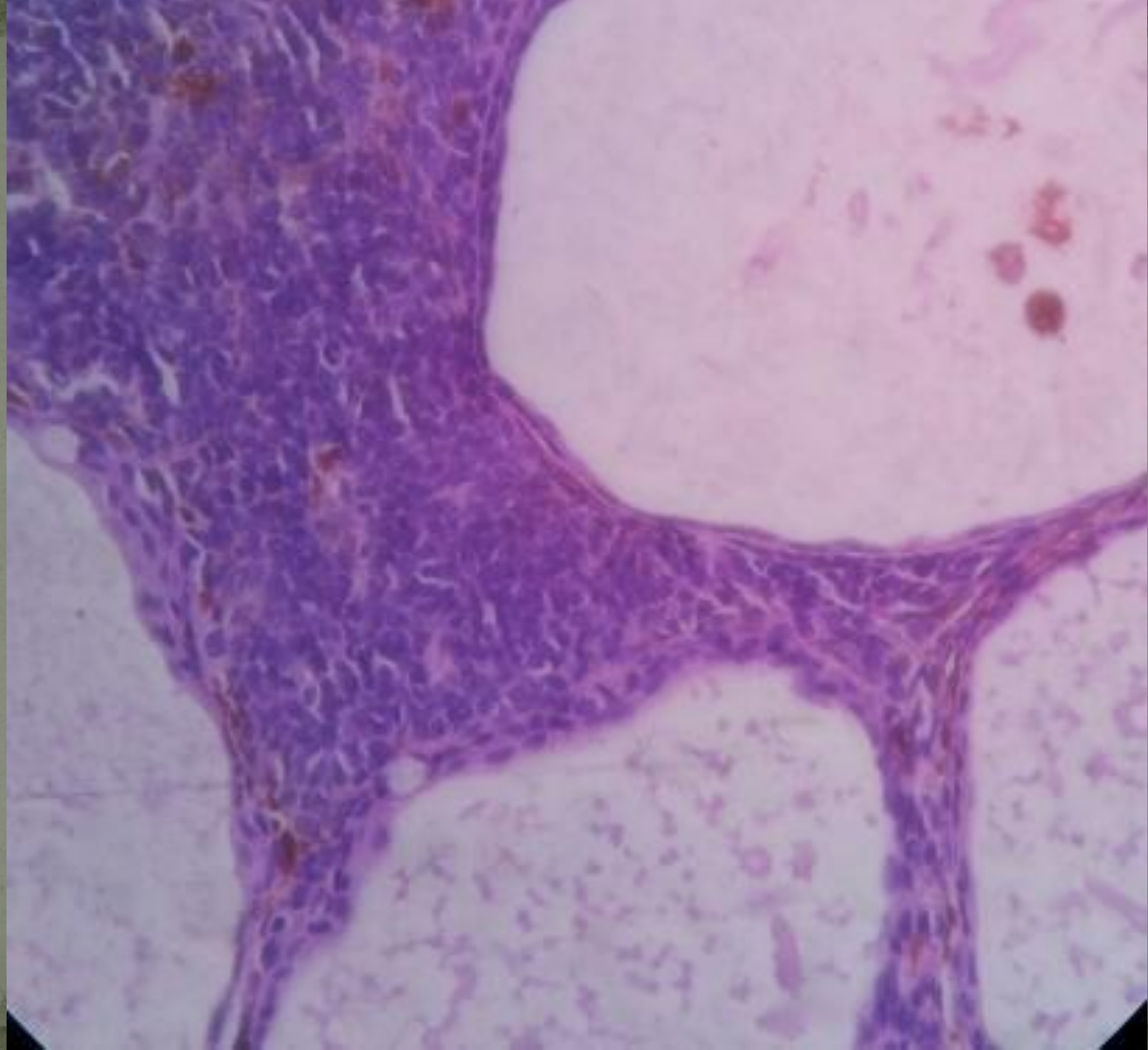


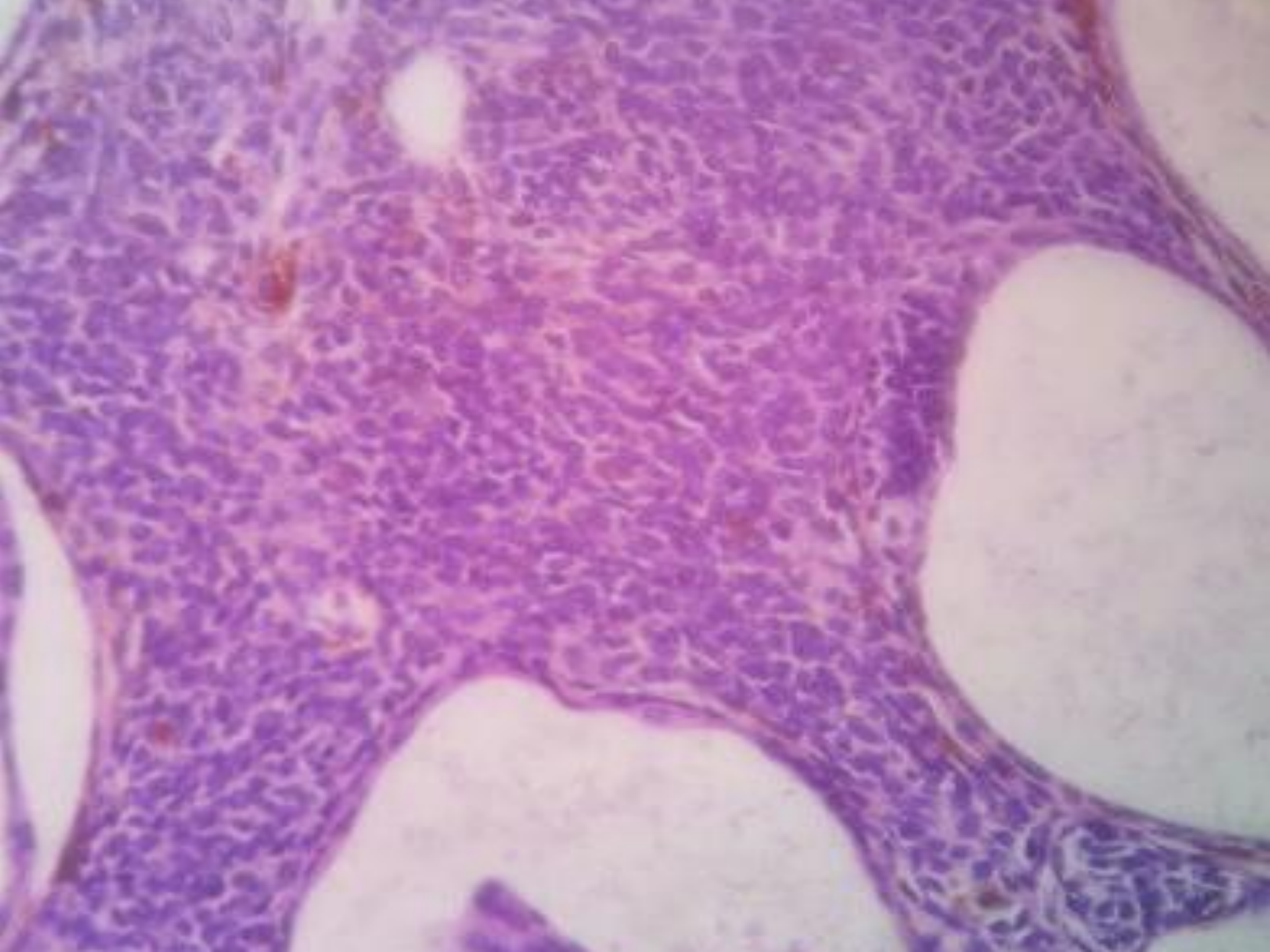
- 24 Y.M. Conjunctival nevus











**THANK YOU**

**THANK**

