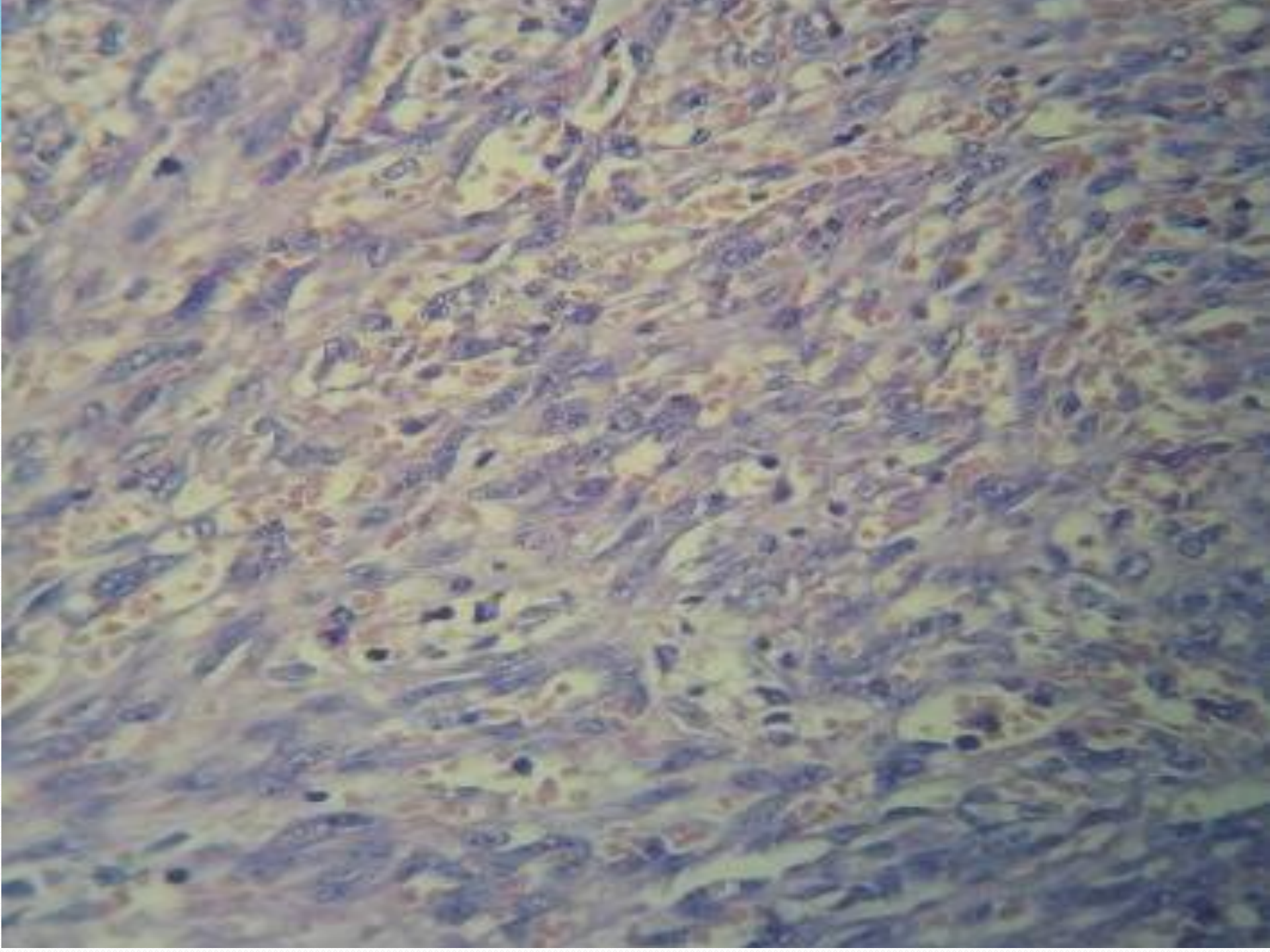
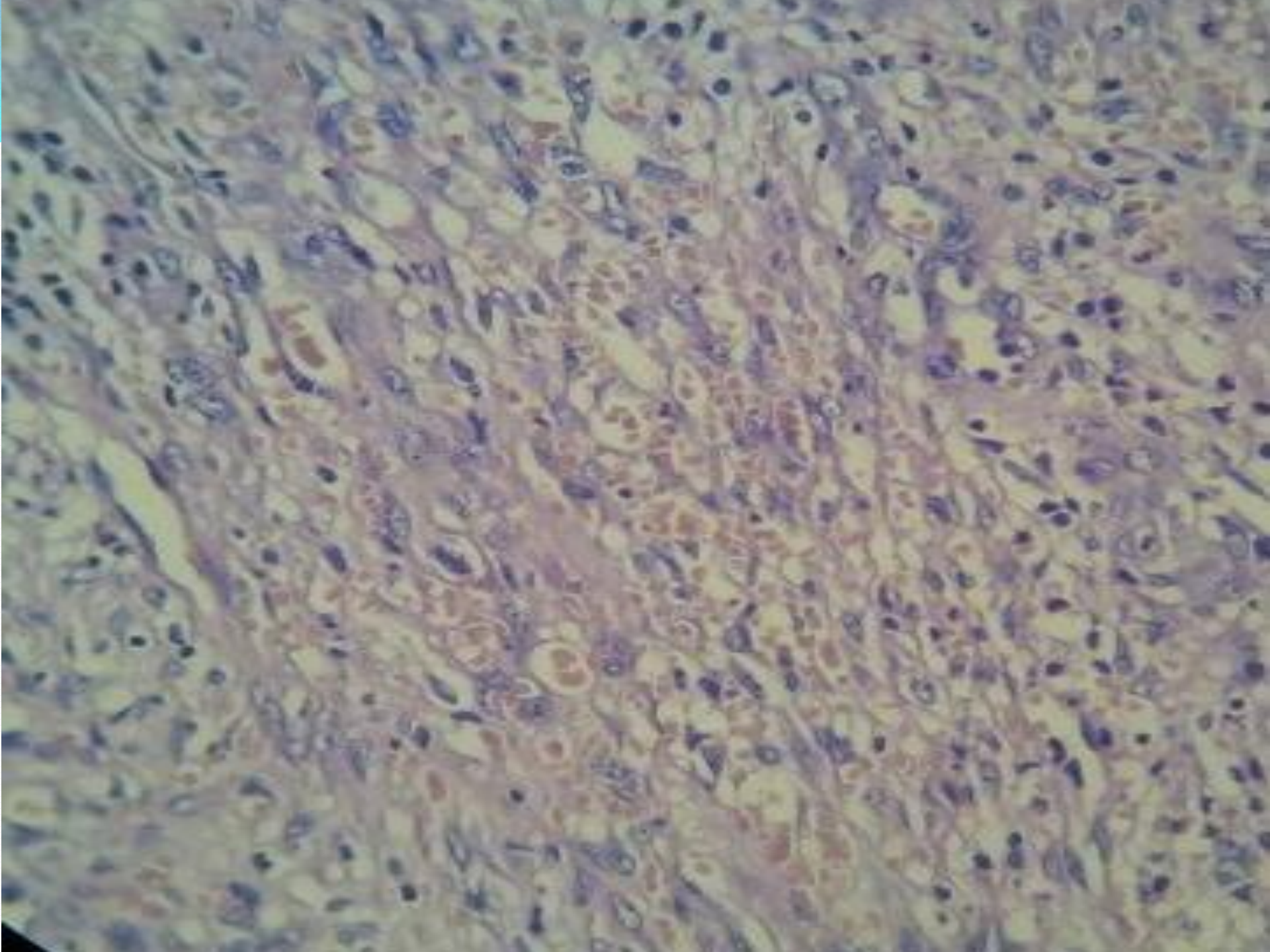
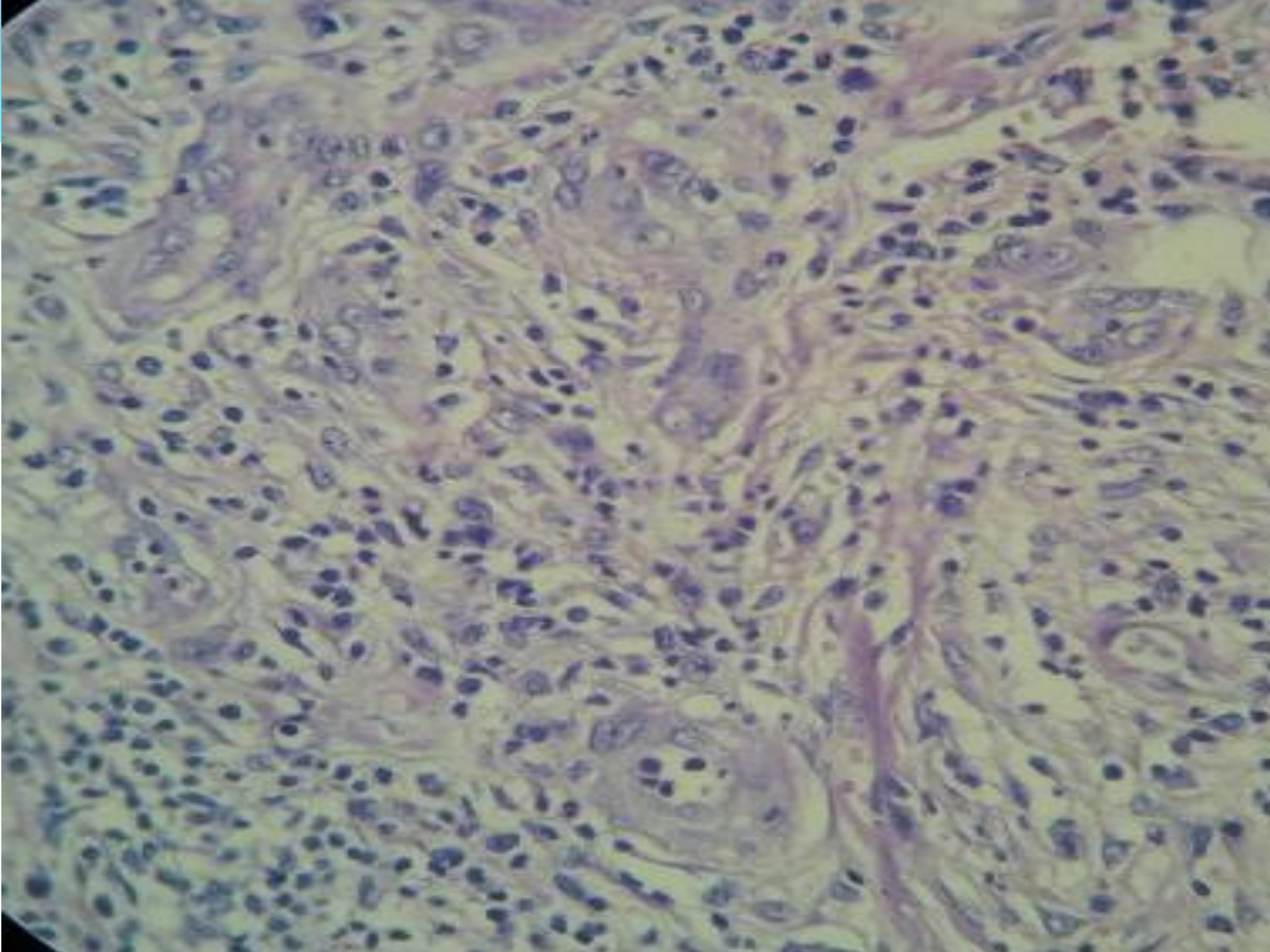


# **1<sup>st</sup> Slide Meeting**

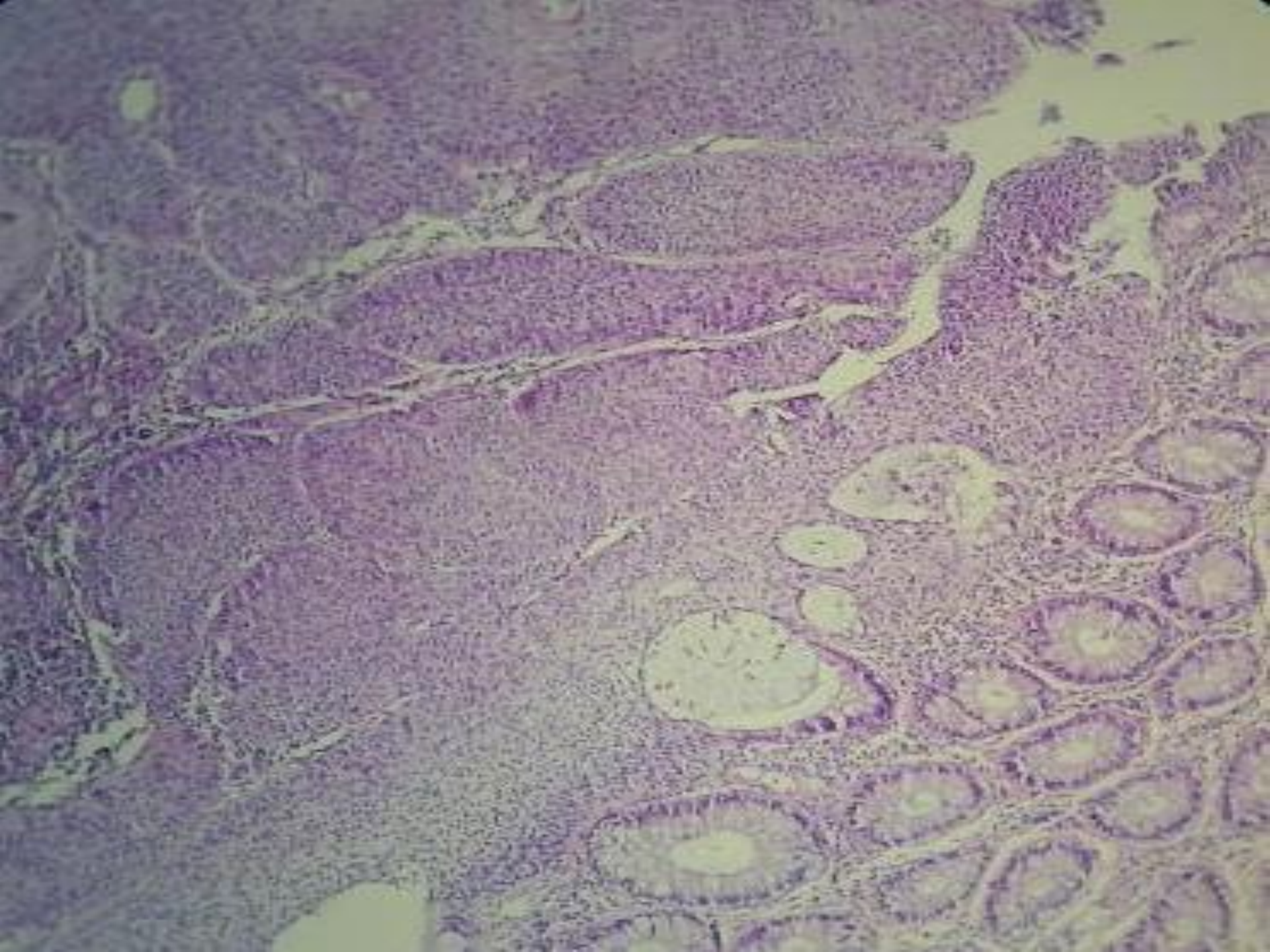
- 60Y.F. mass at the dorsum of the hand

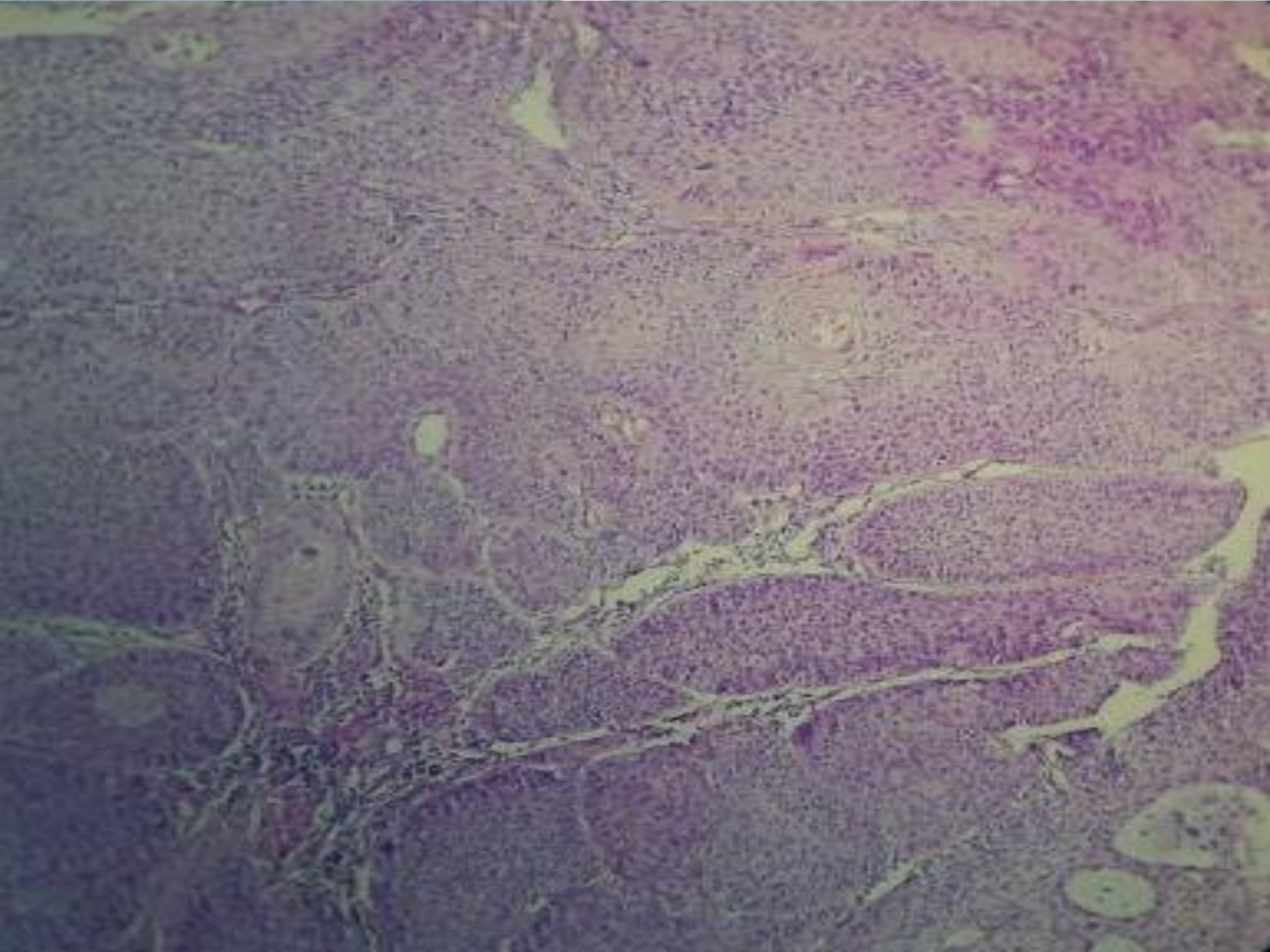




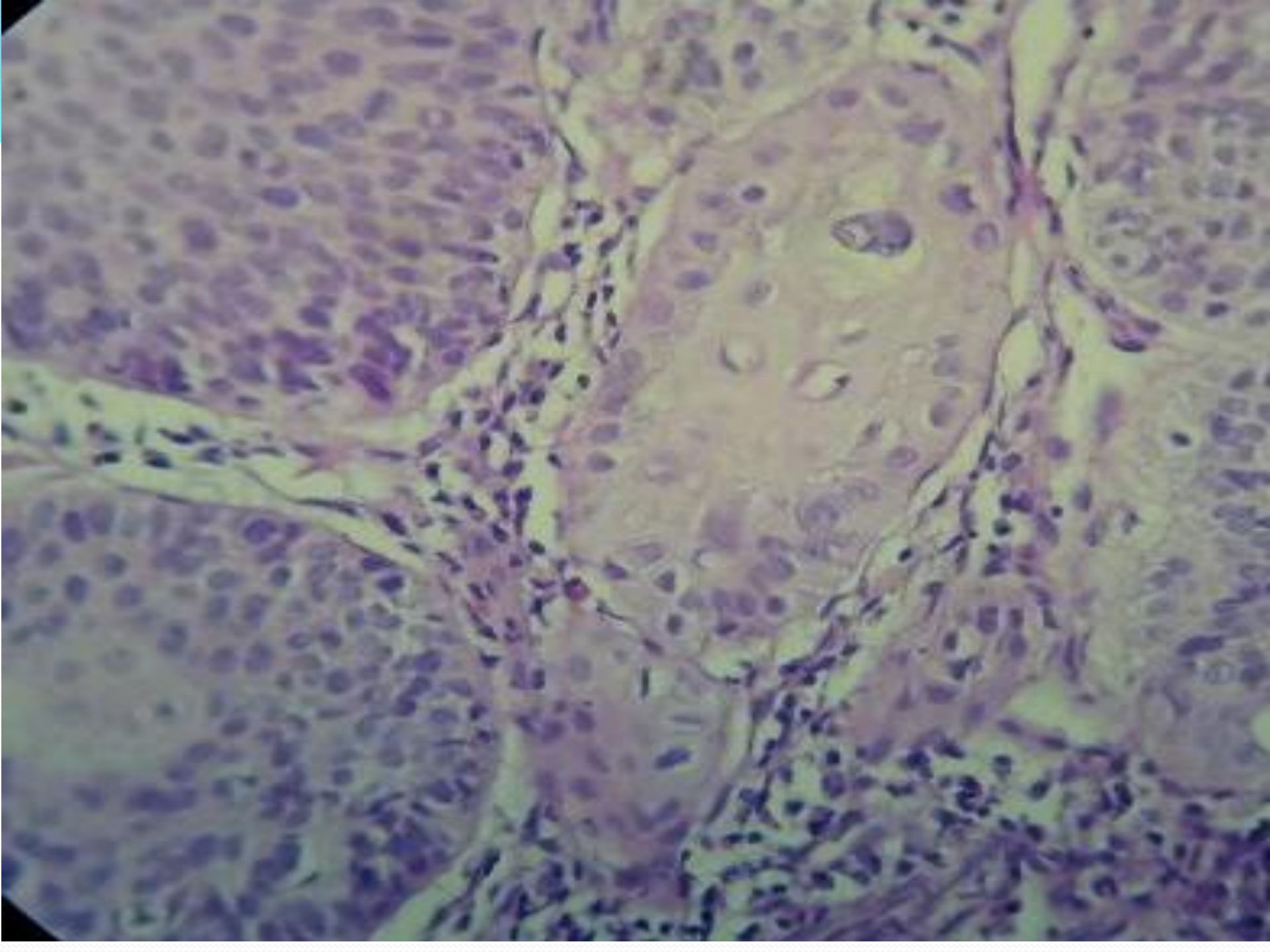


- 50 Y .M. anal mass

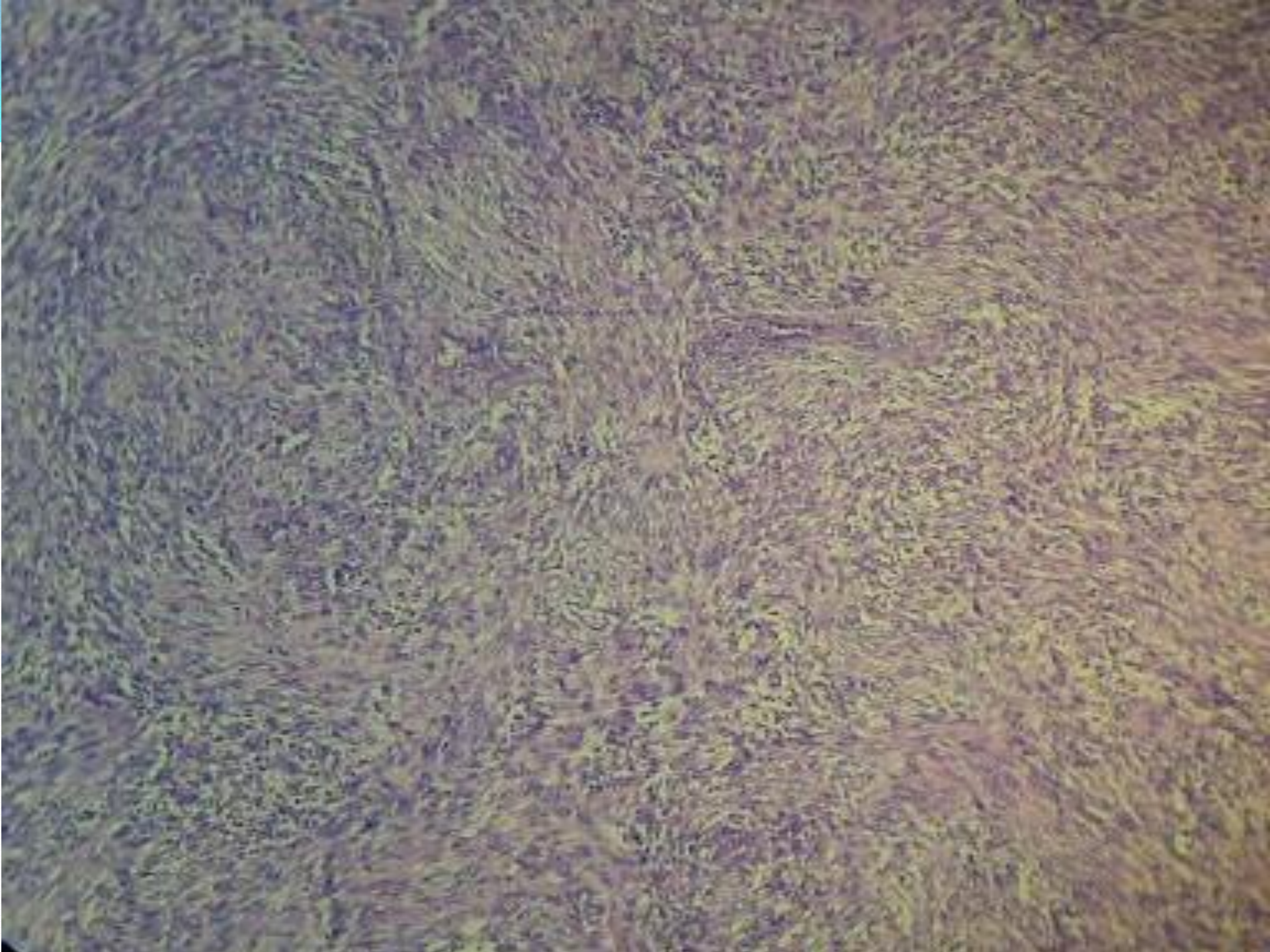


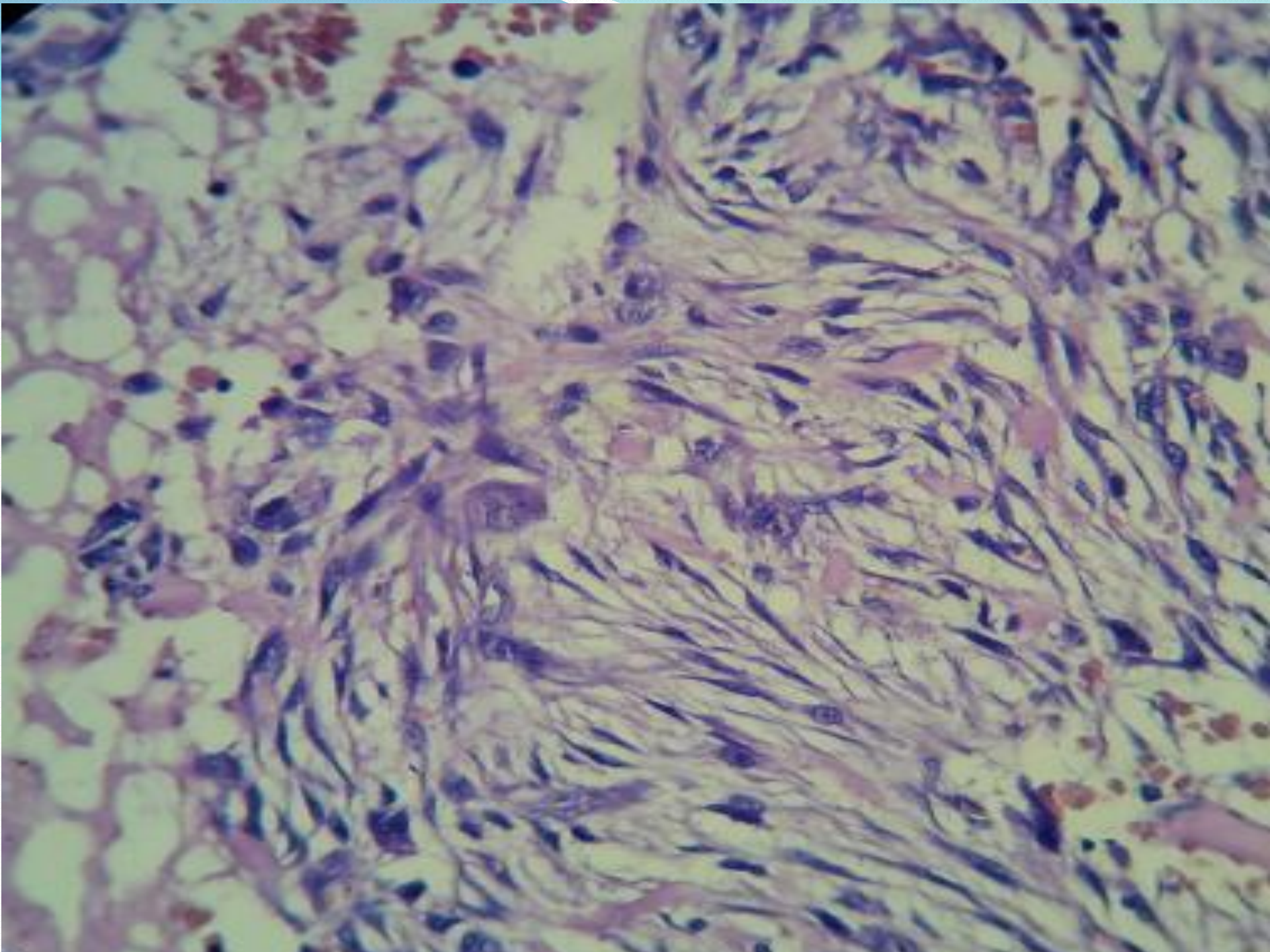


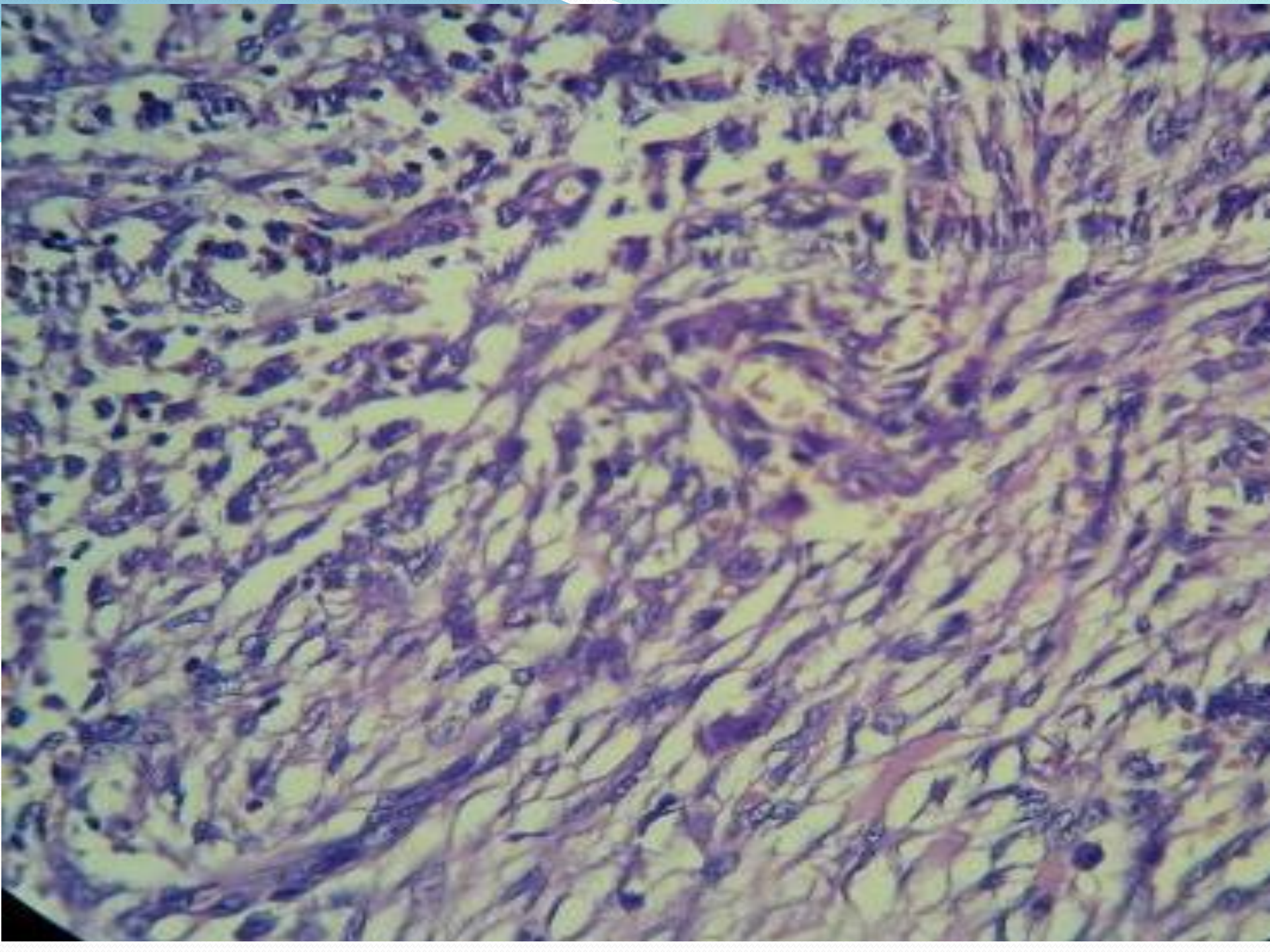




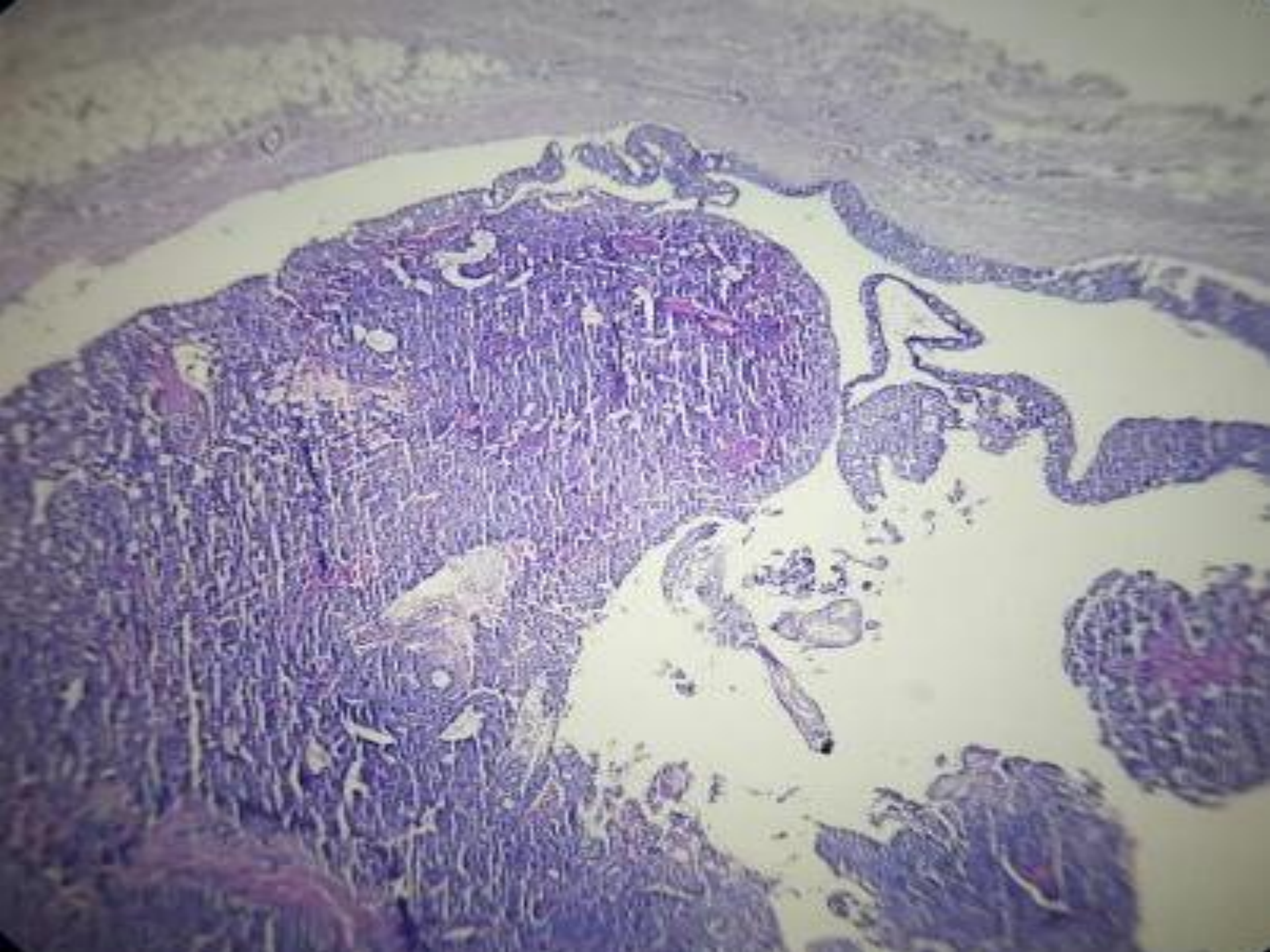
- 33 Y.M mass at buccal area

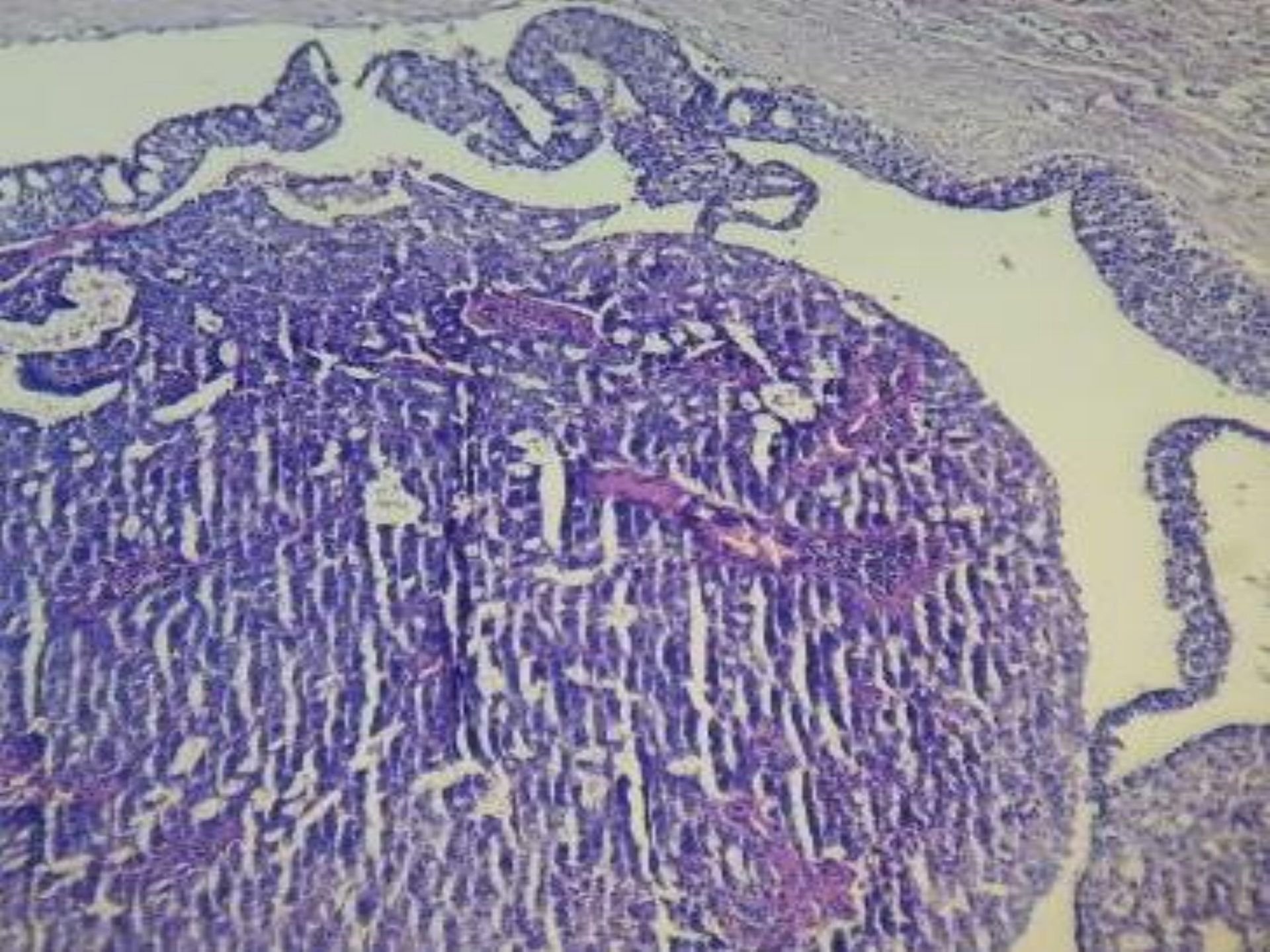




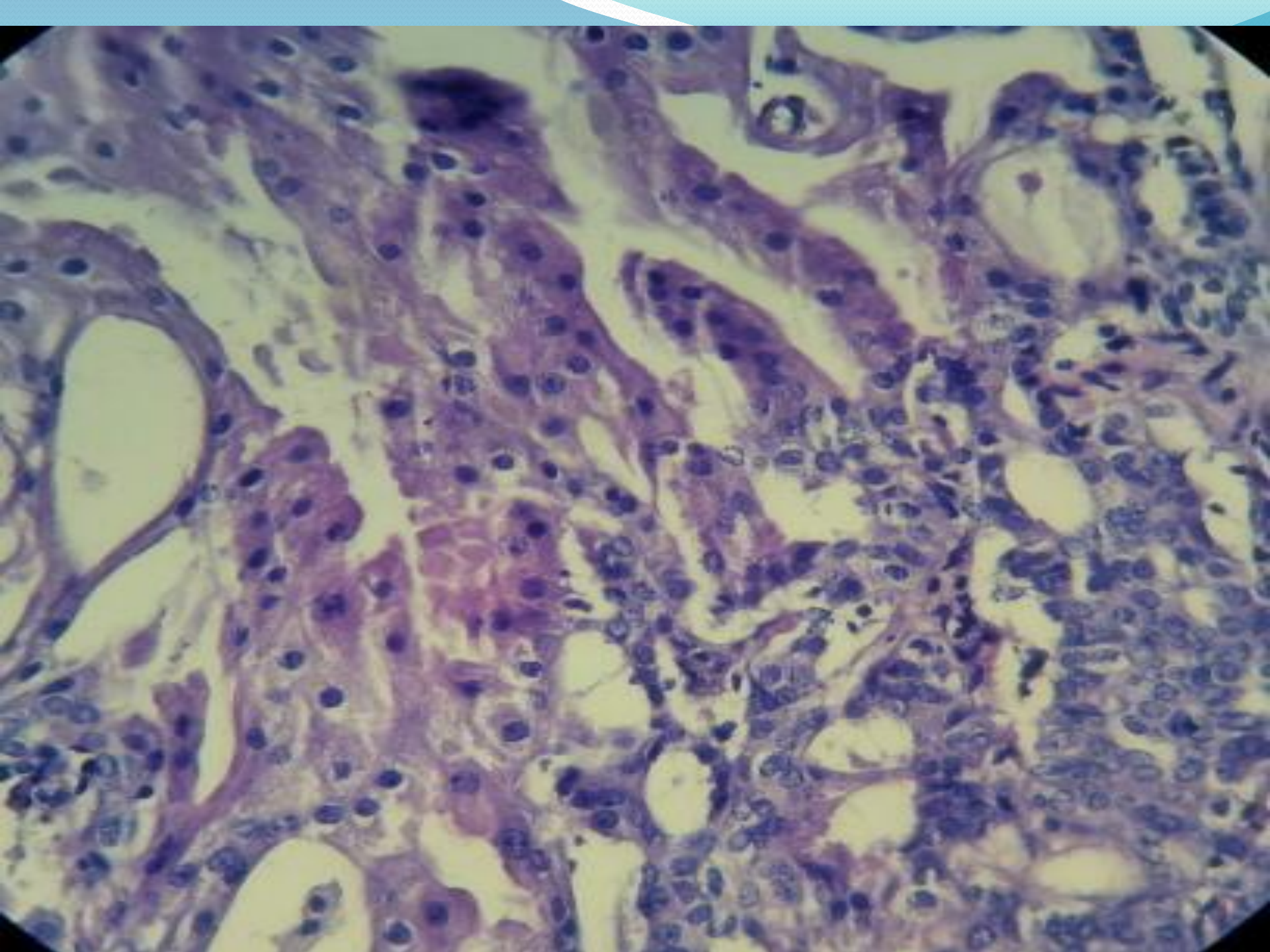


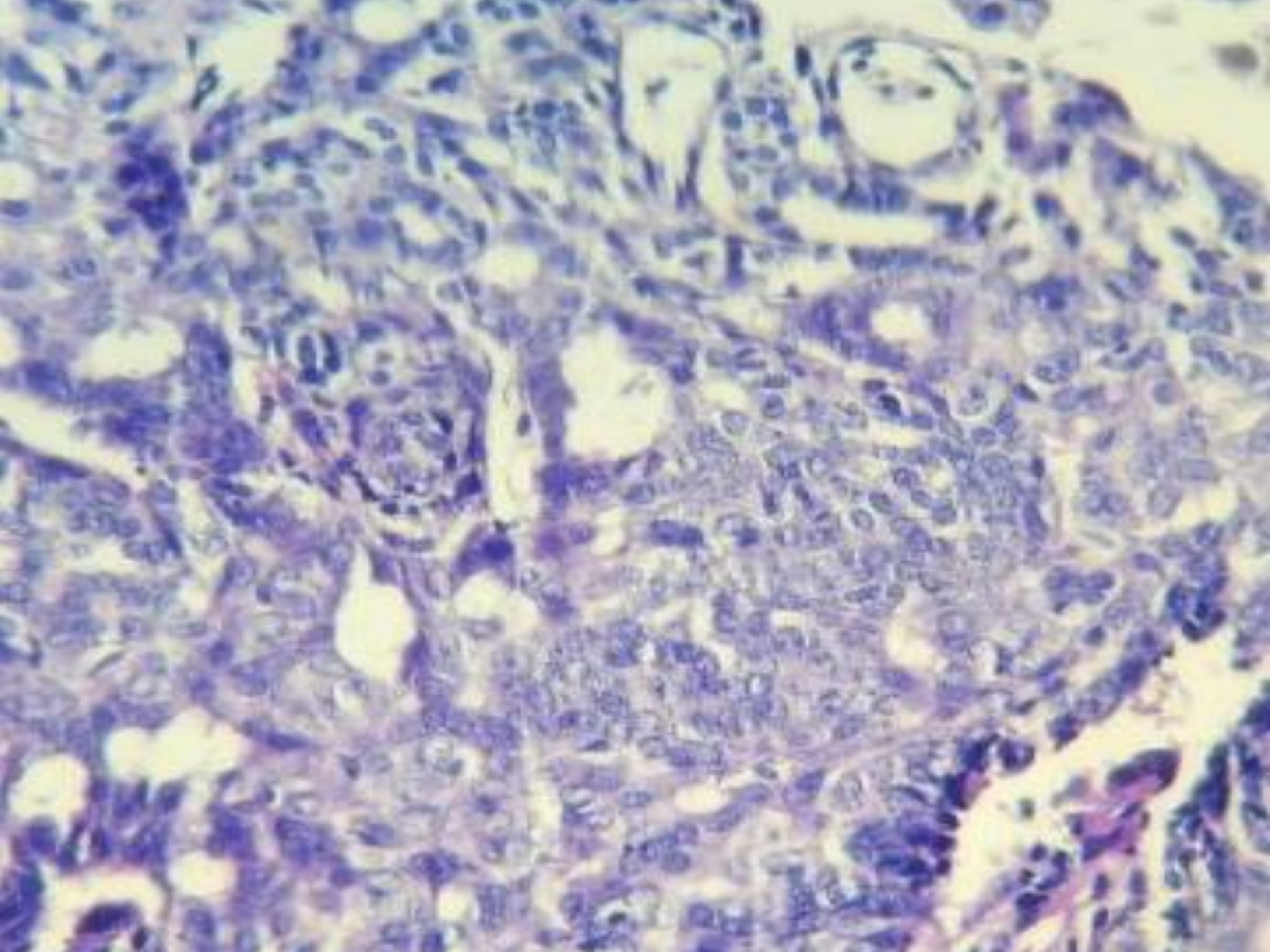
- **35 Y.F. breast mass**



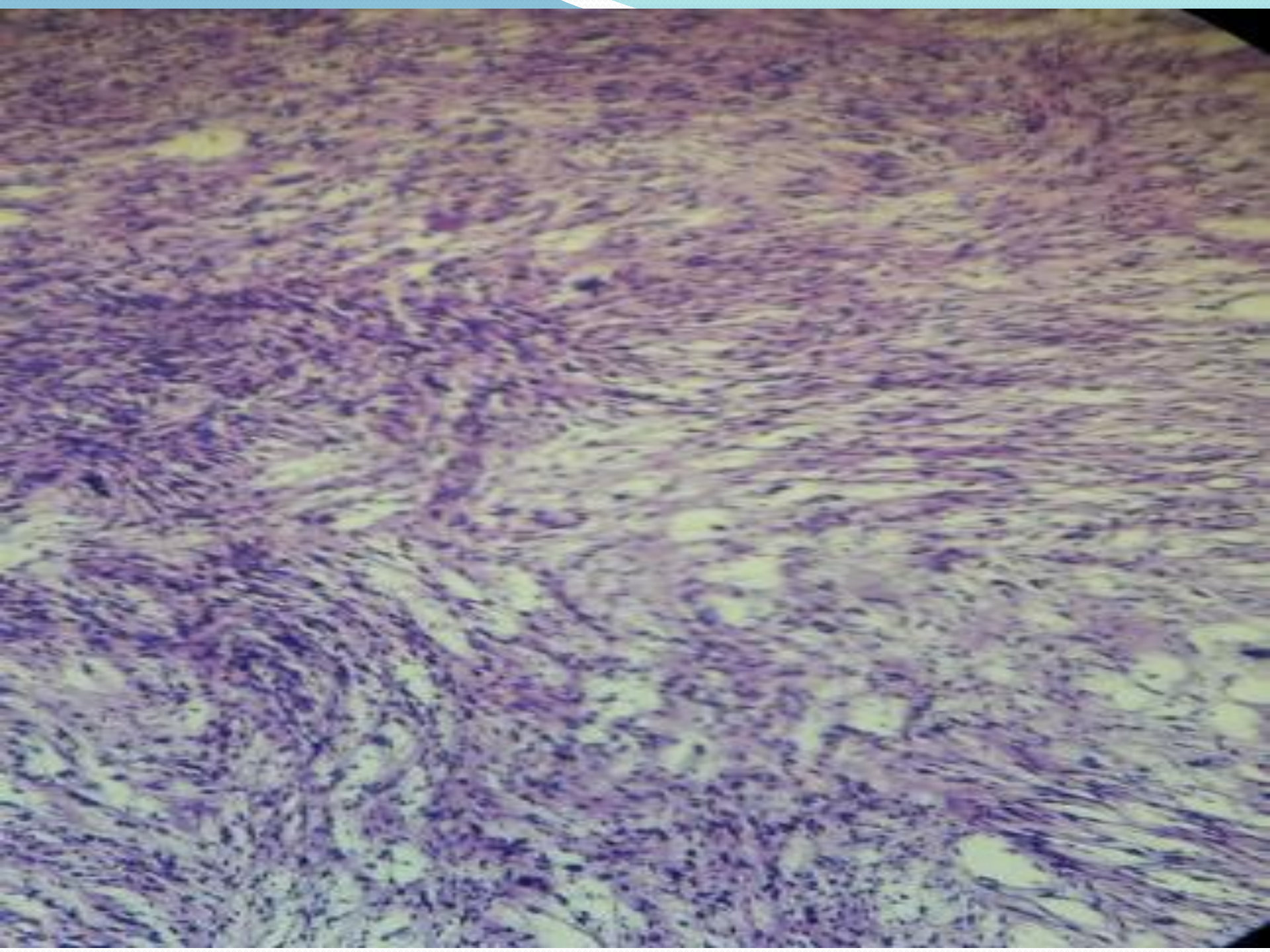


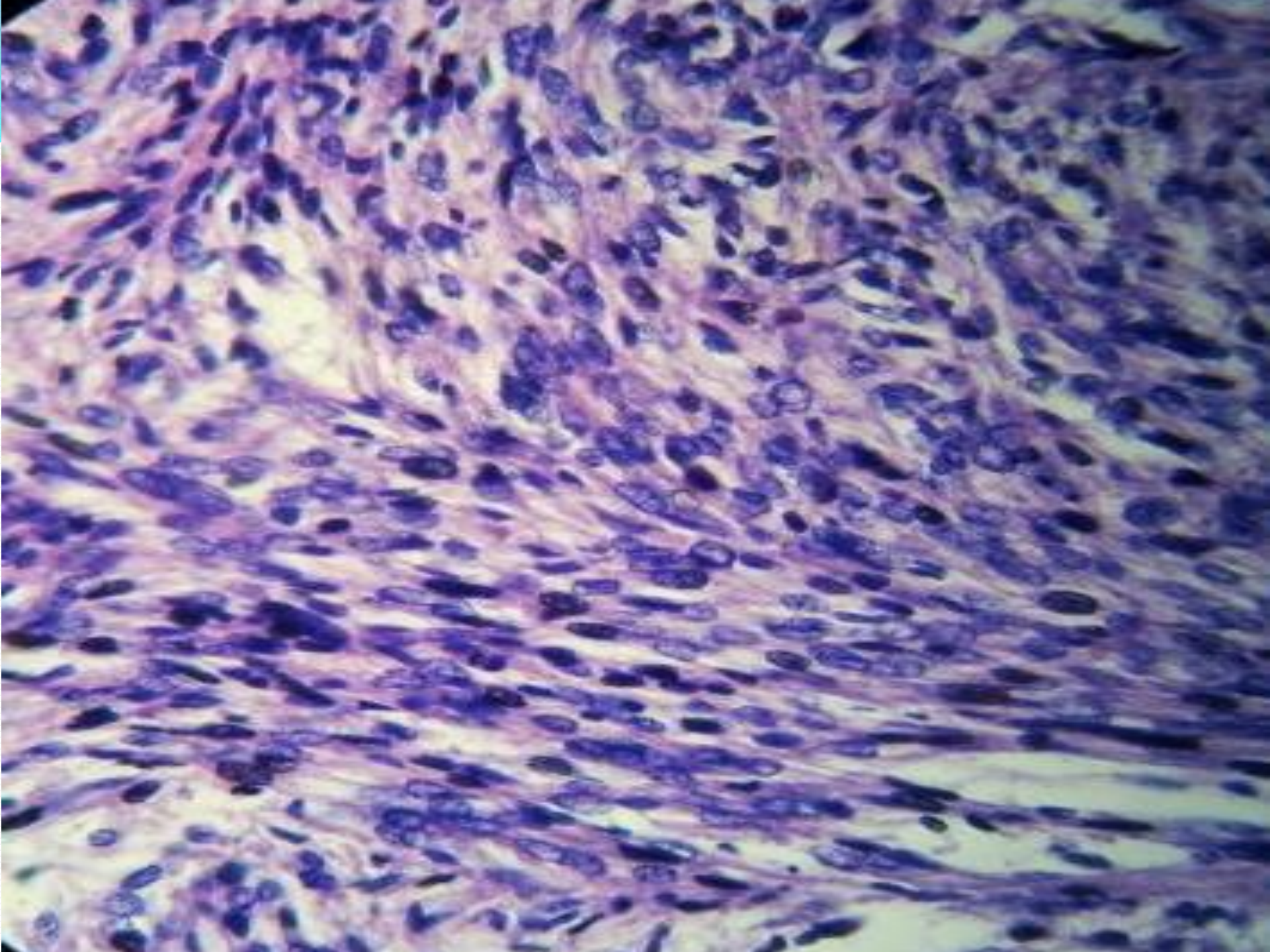


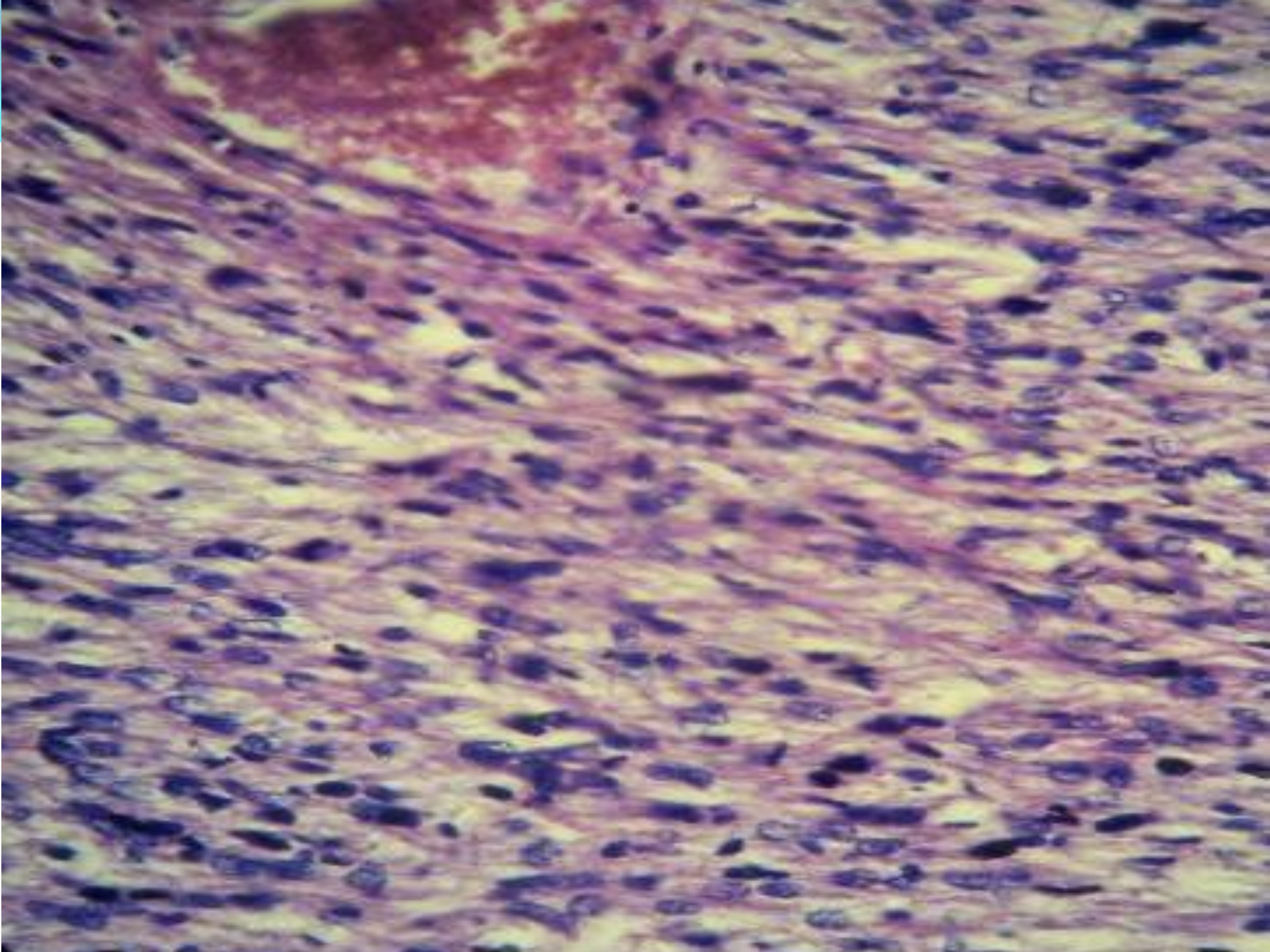


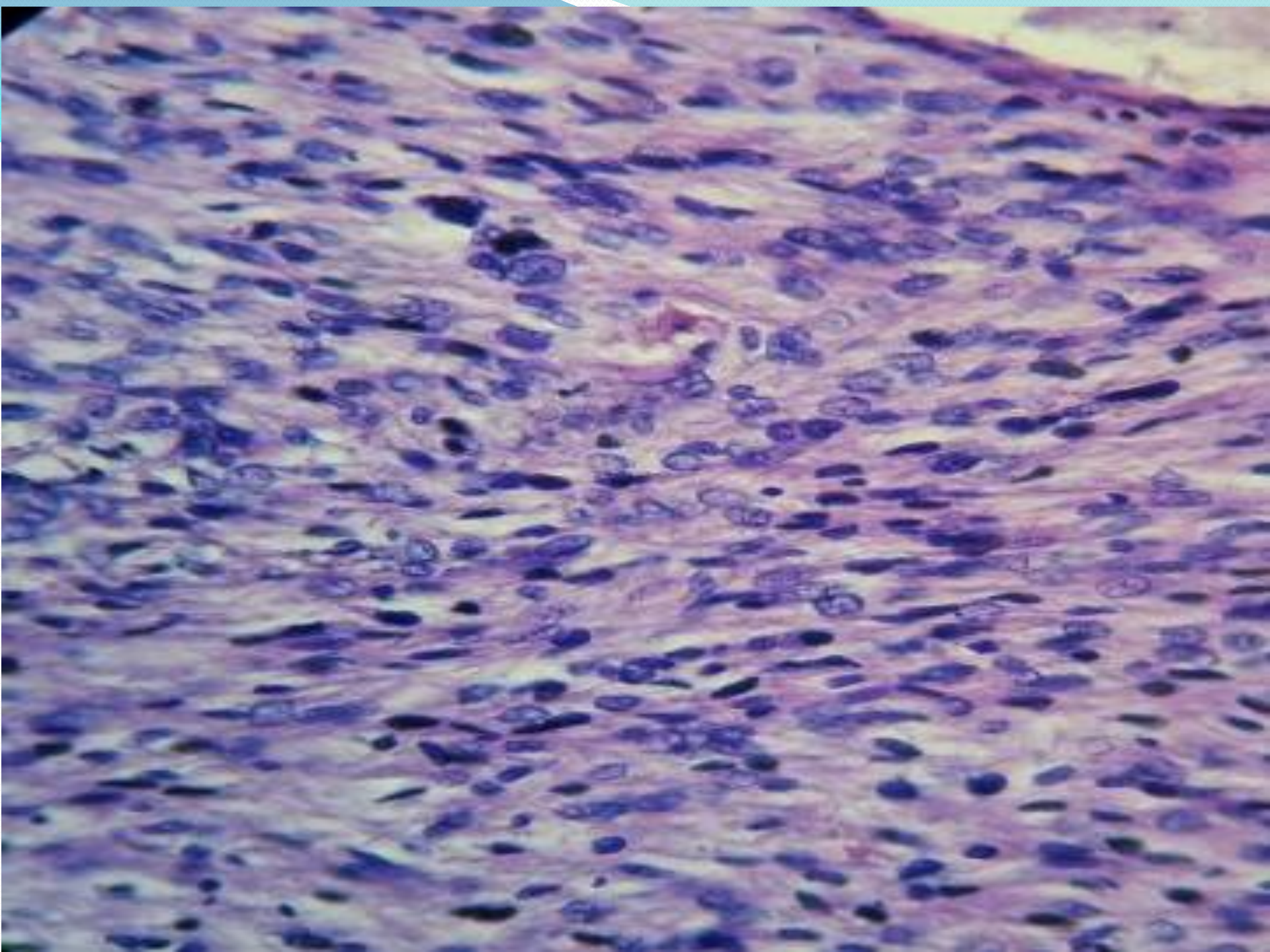


- **50 Y.F. recurrent retroperitoneal mass**











THANK  
YOU