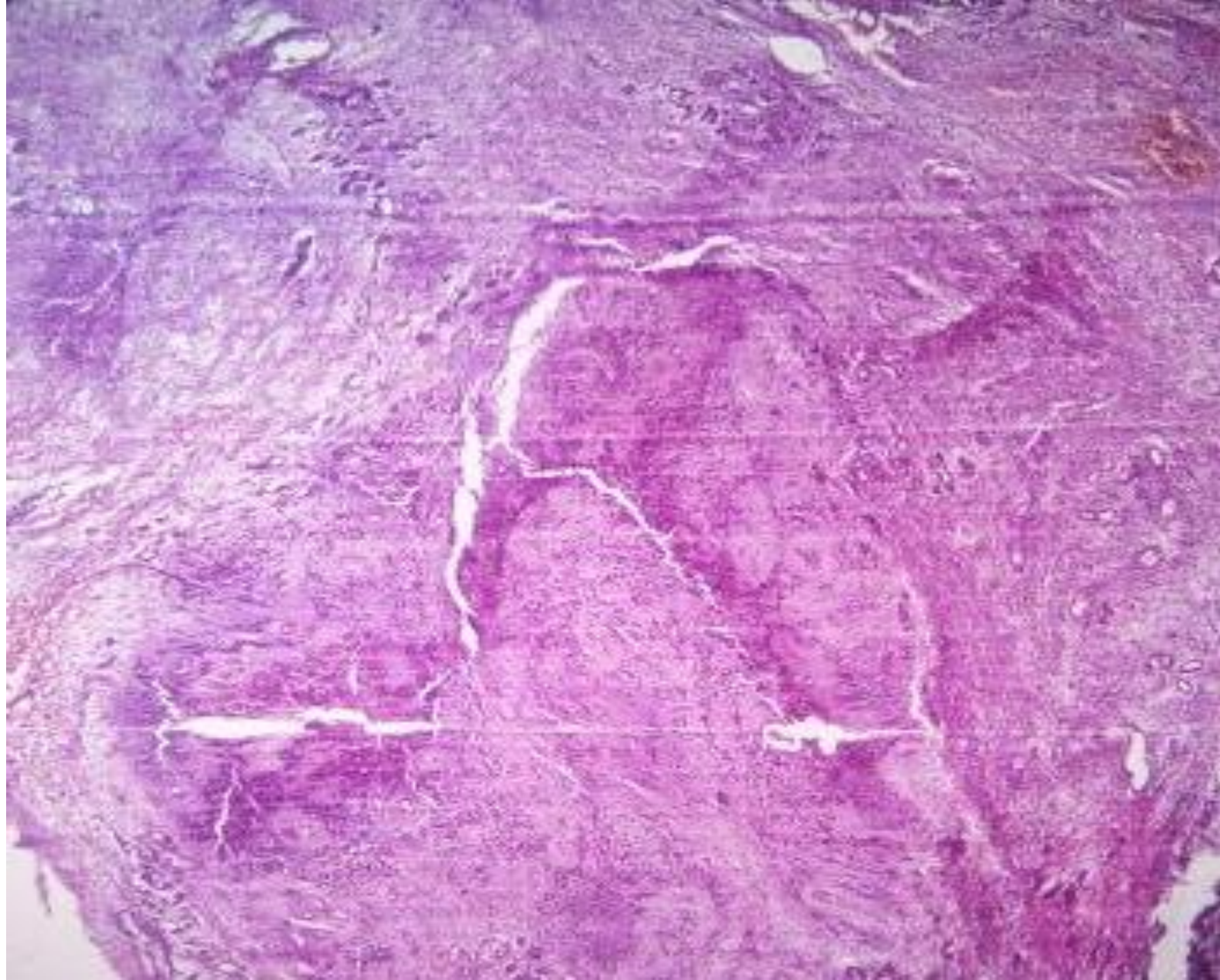
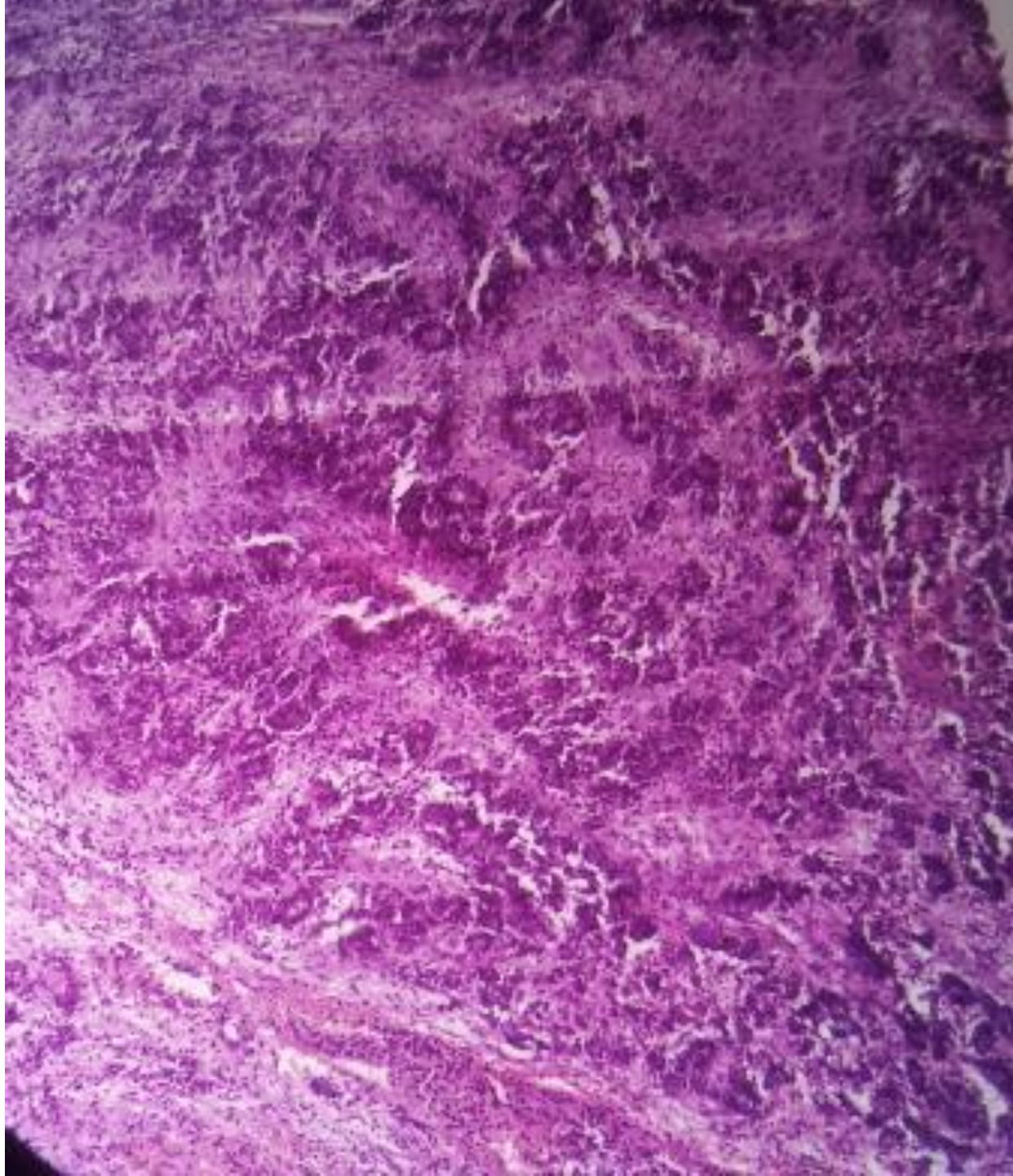


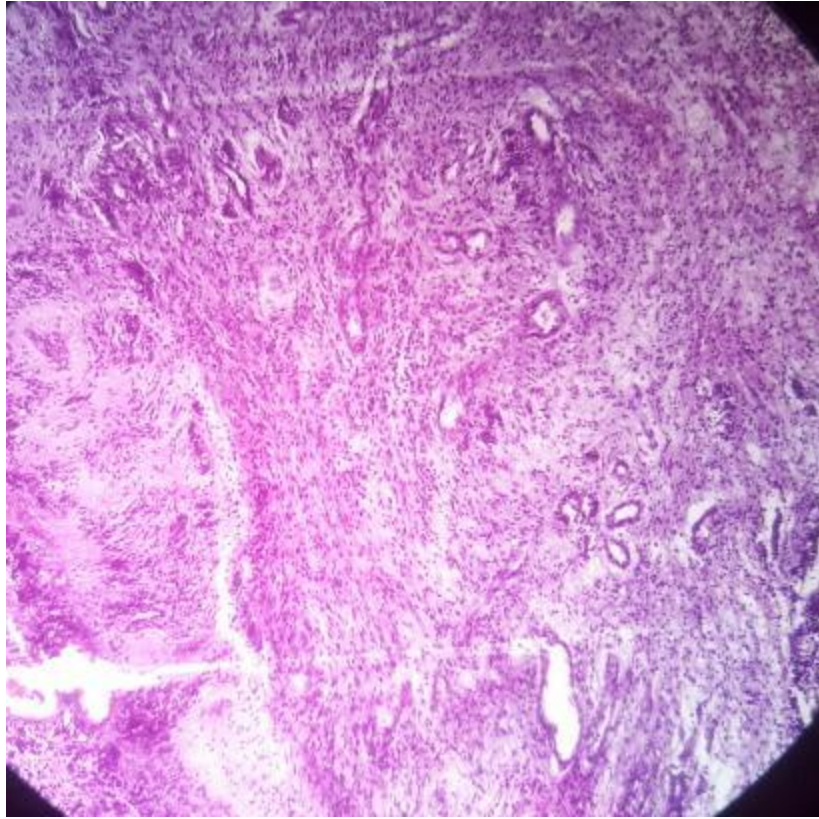
7TH SLIDE MEETING

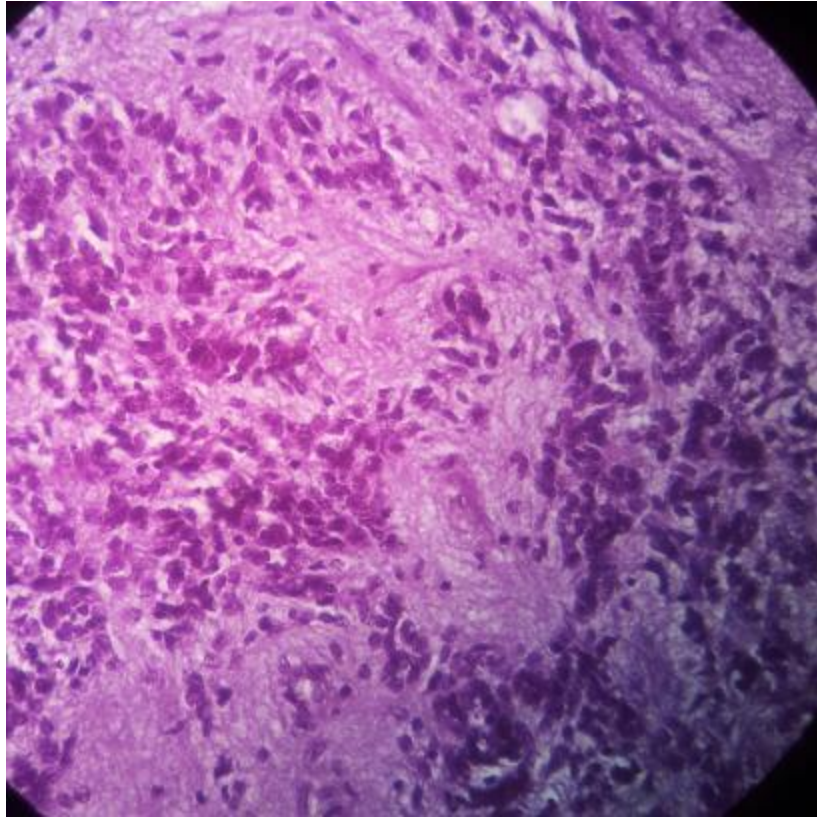


□ 1.5 Y.M. Post fassa tumor



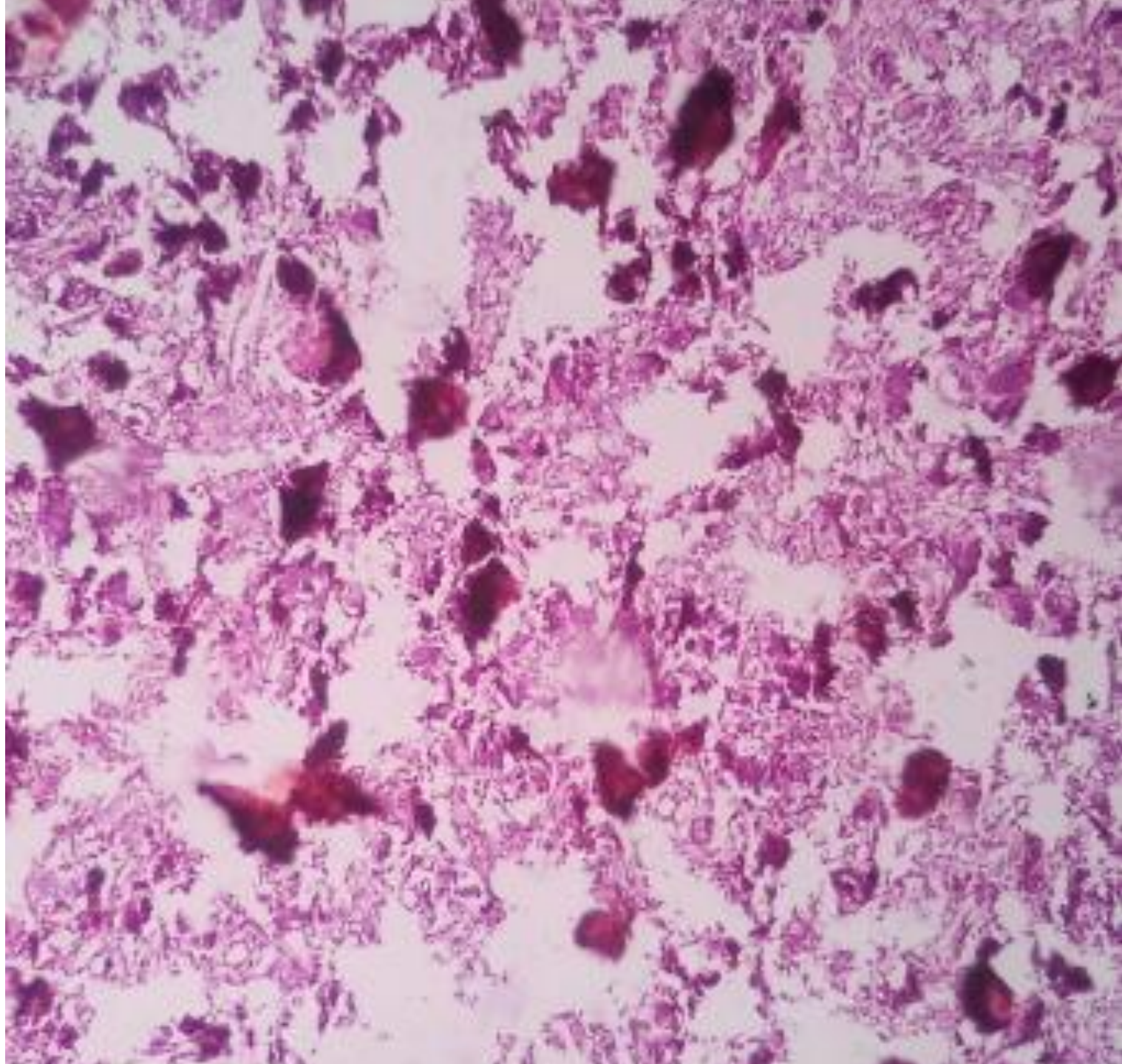


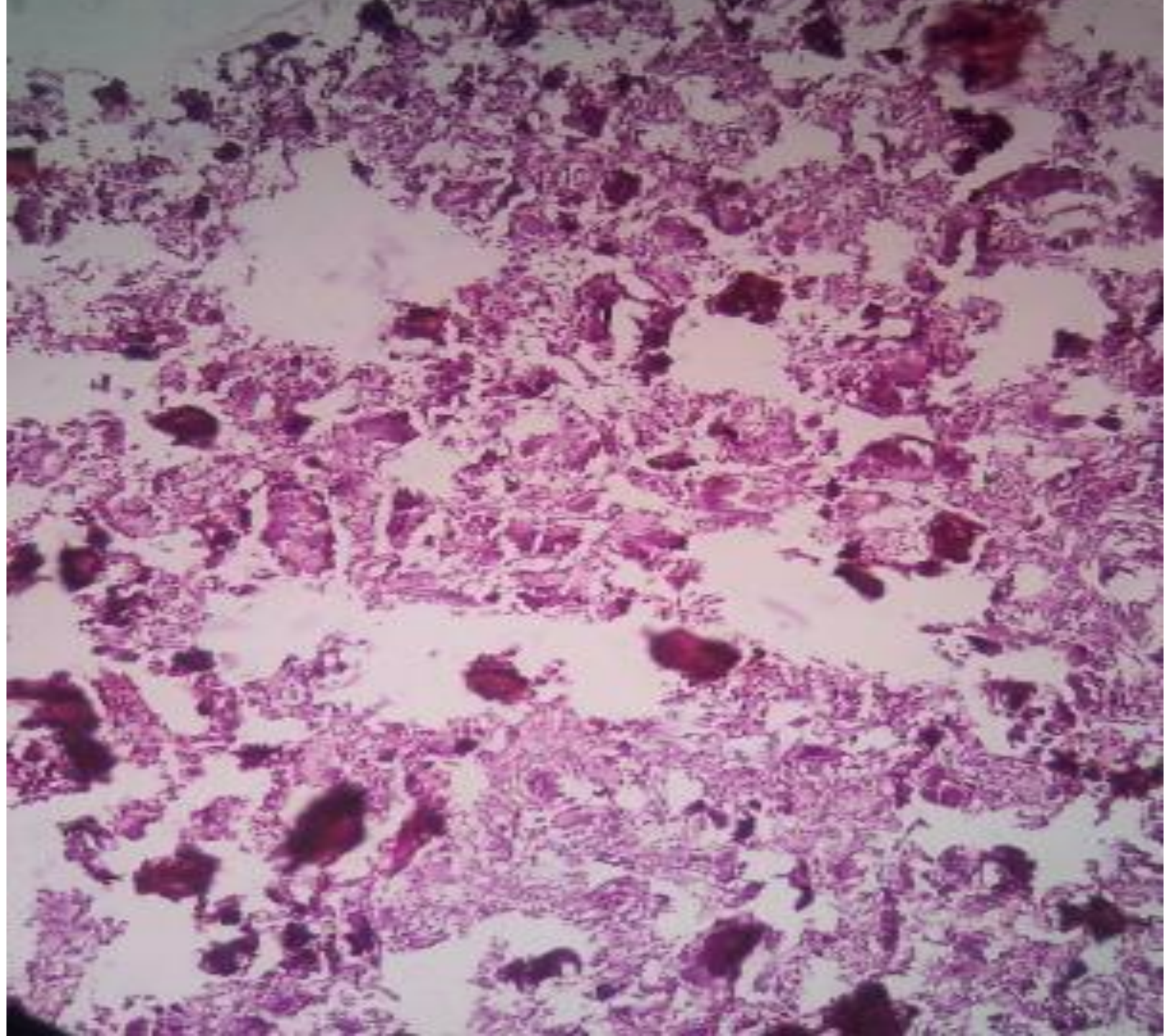


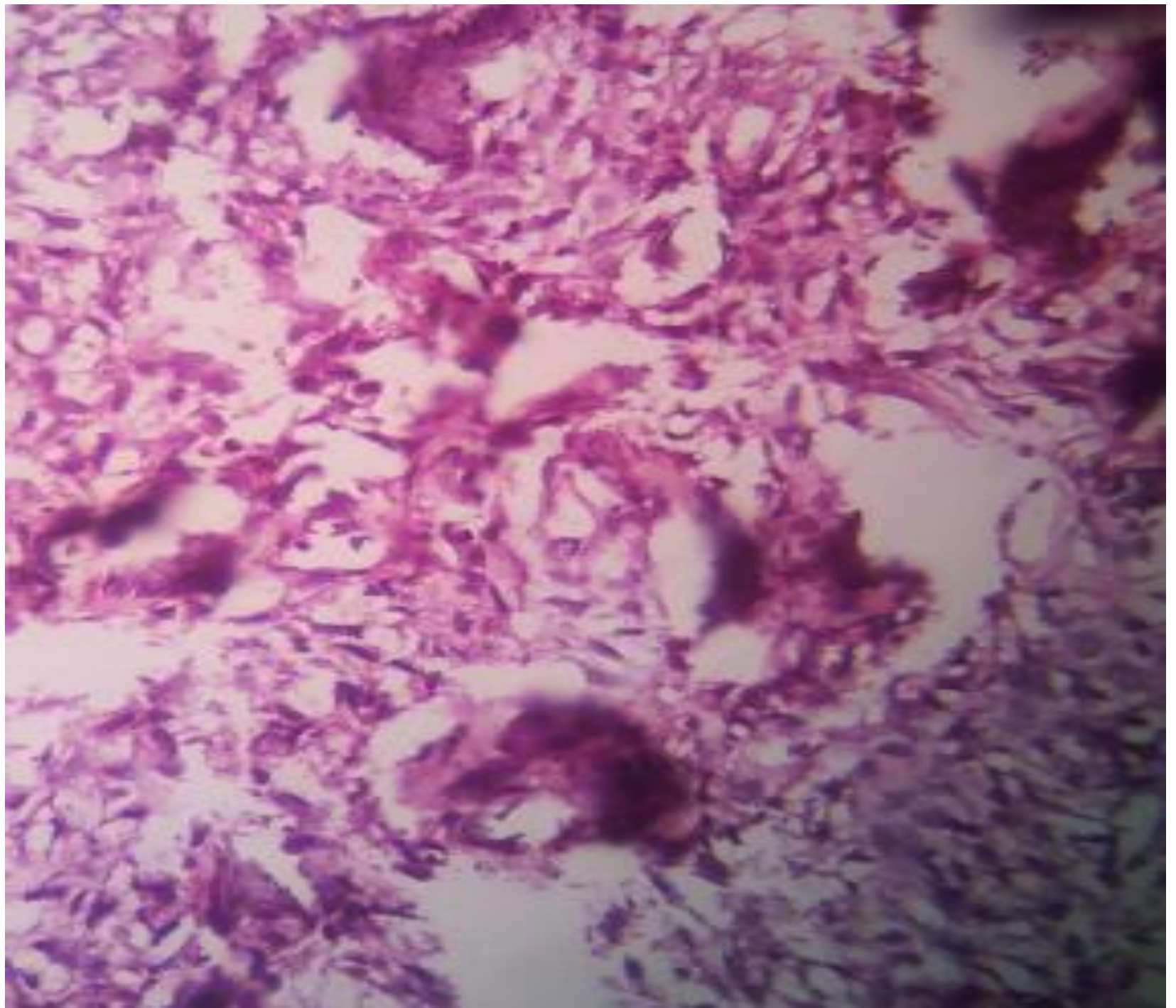


□ **17 Y.M. left orbital tumor.**

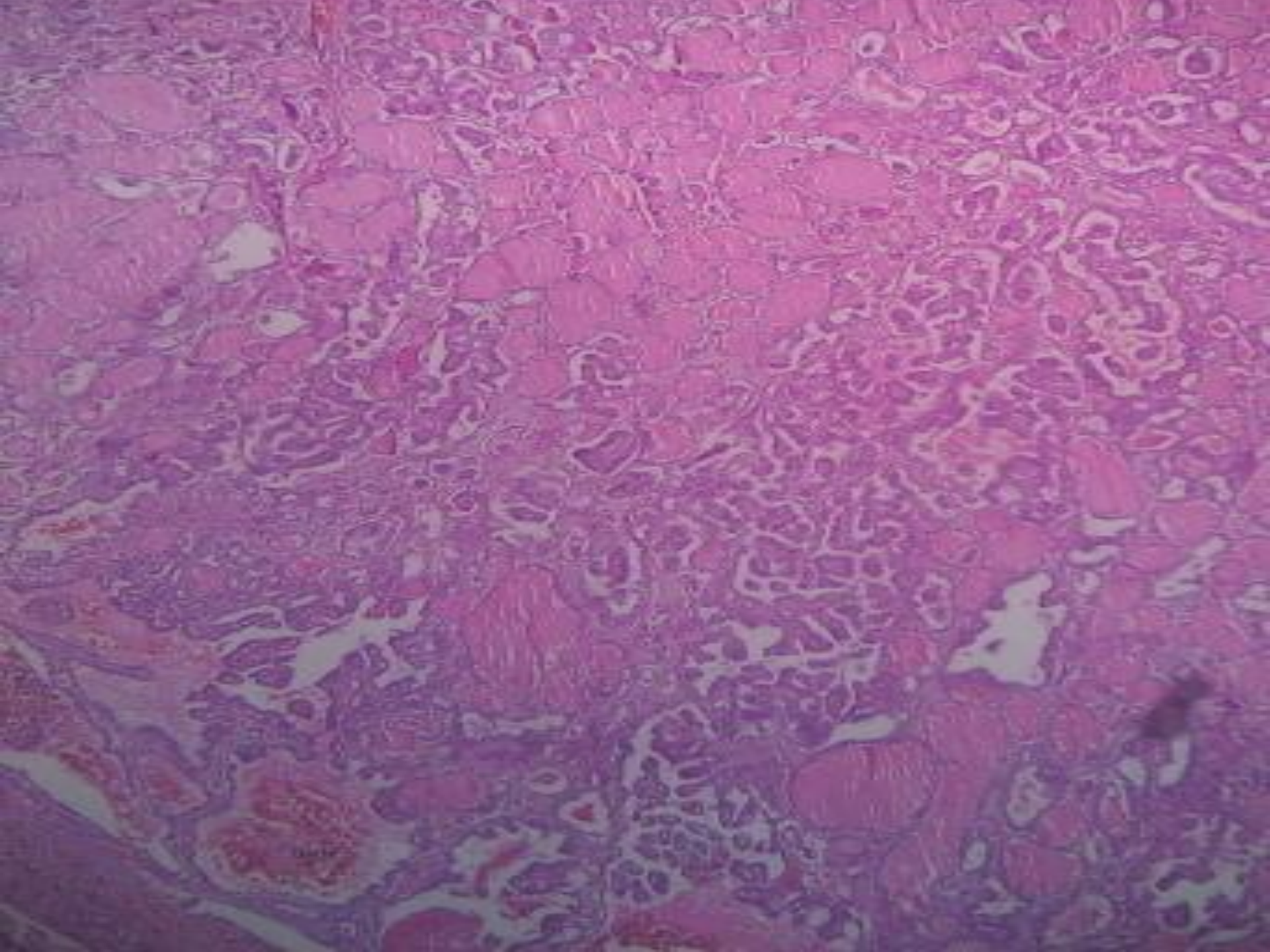


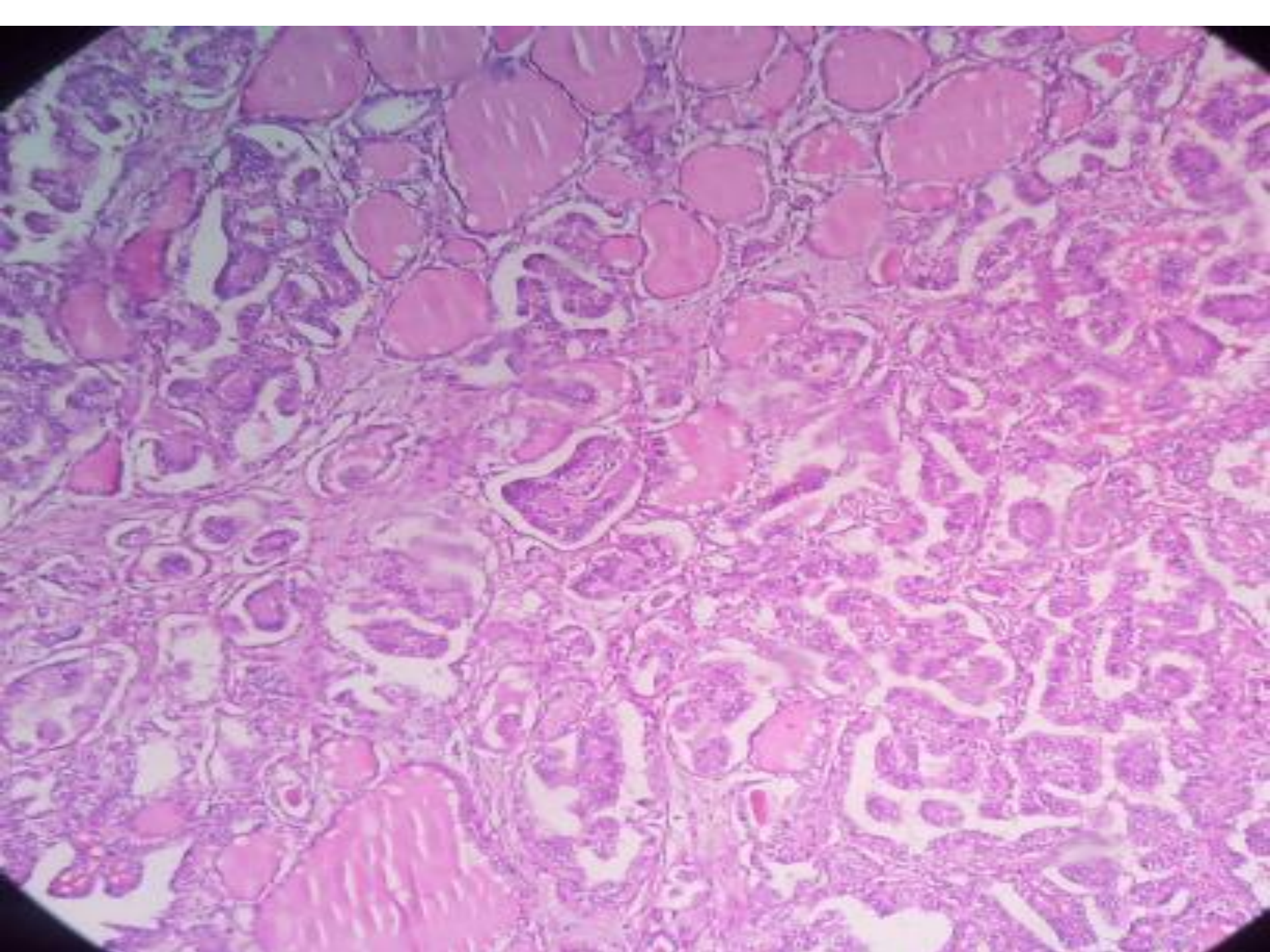


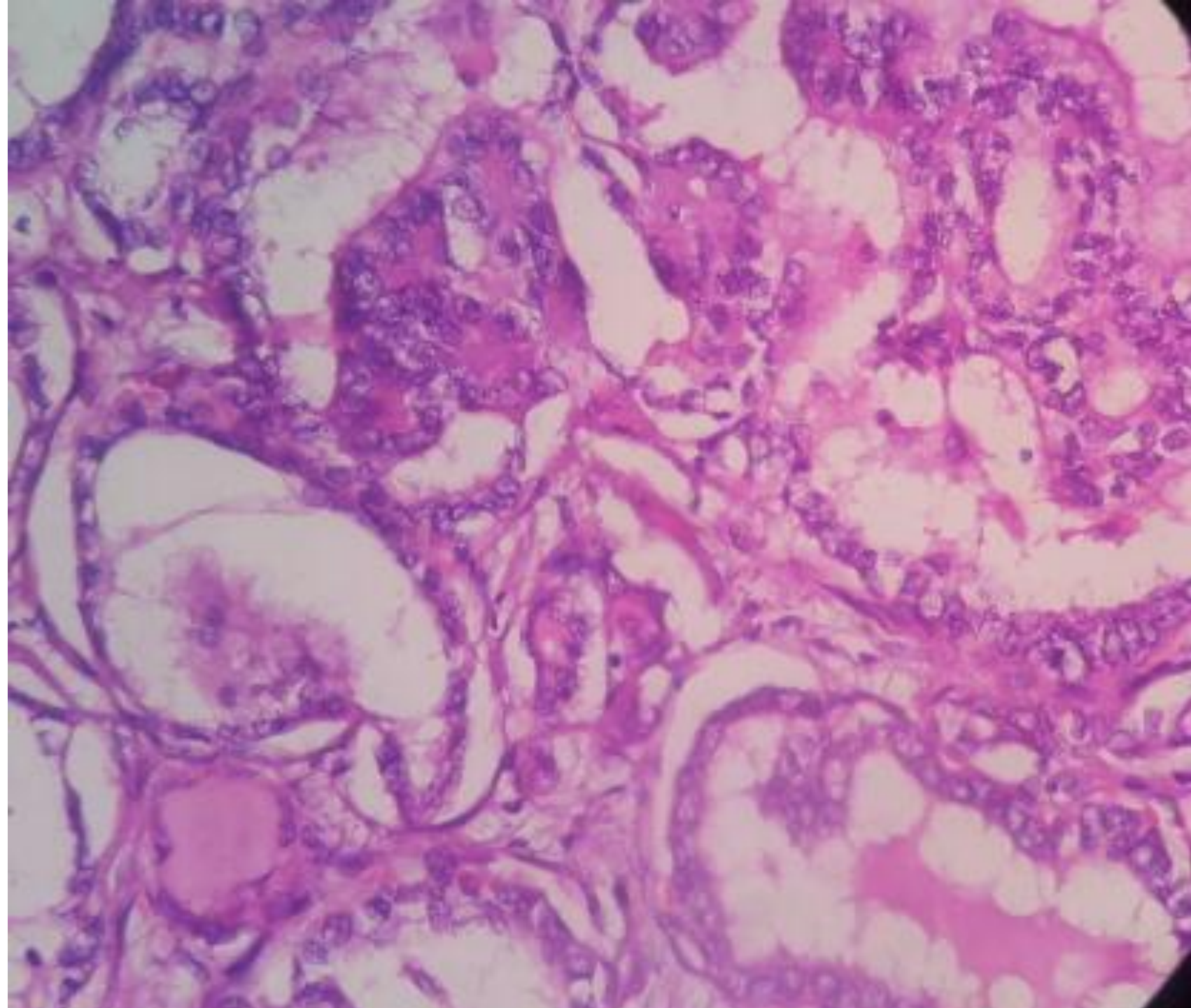


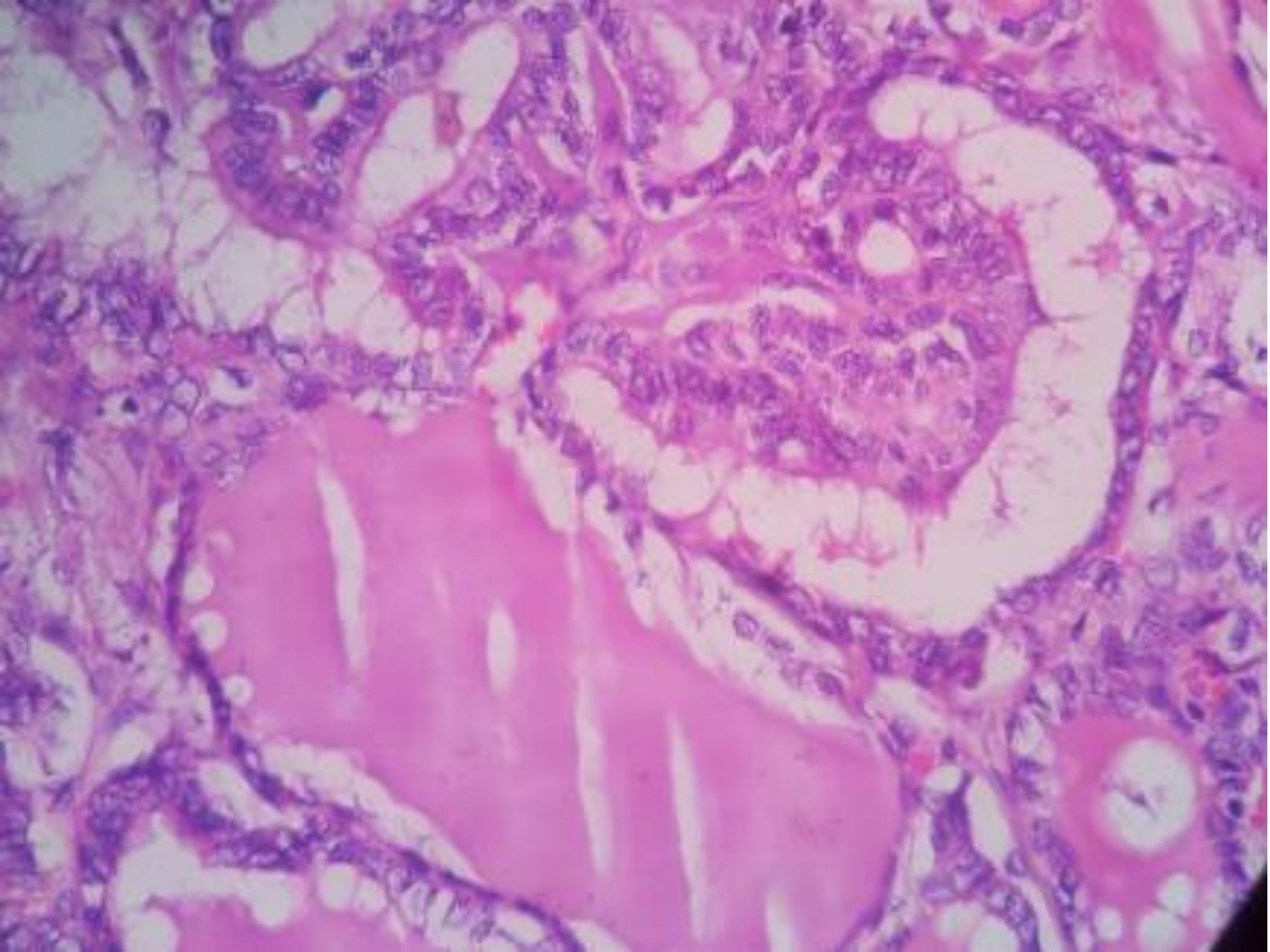


□ 47 Y.F. Thyroid .

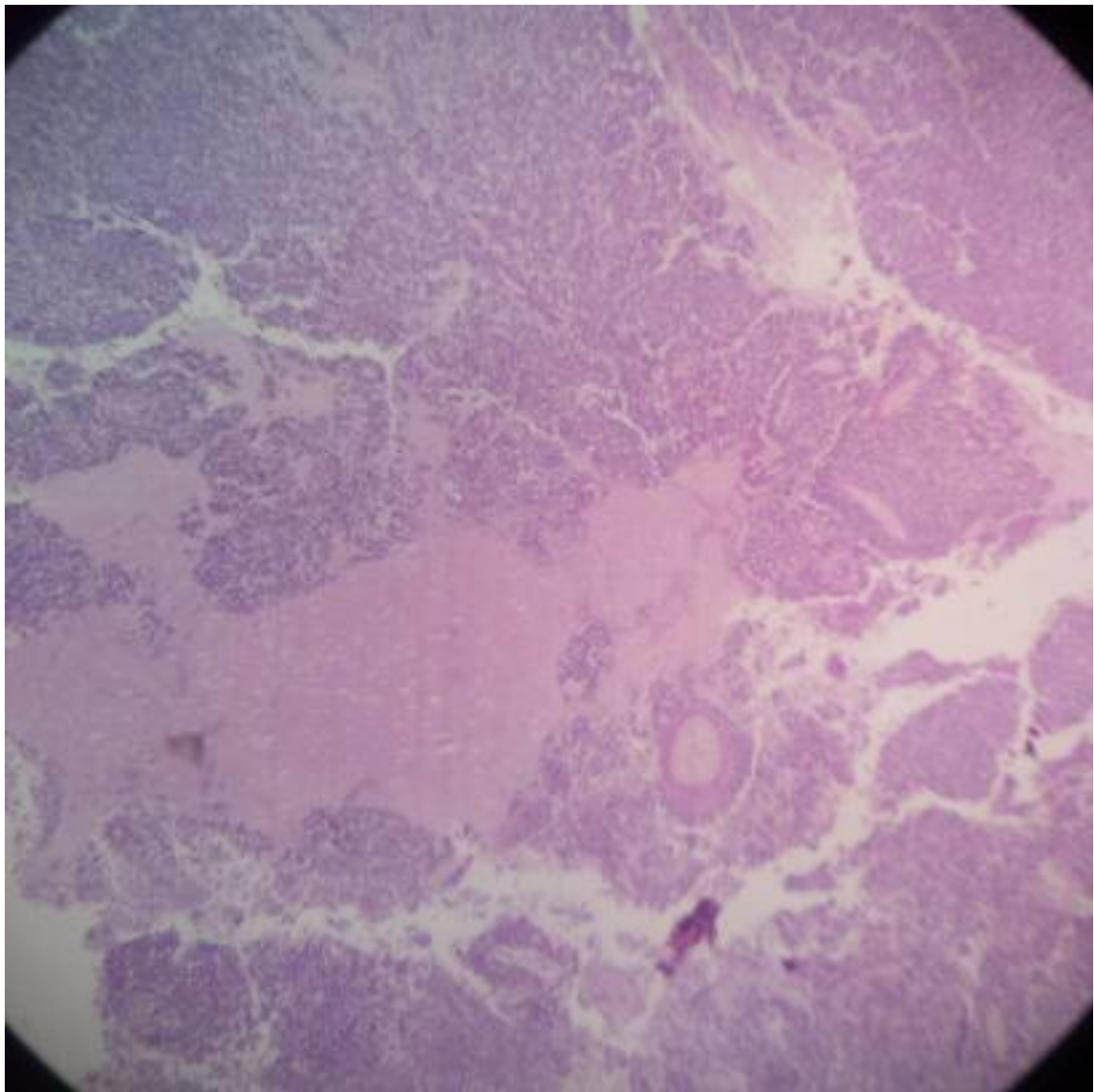


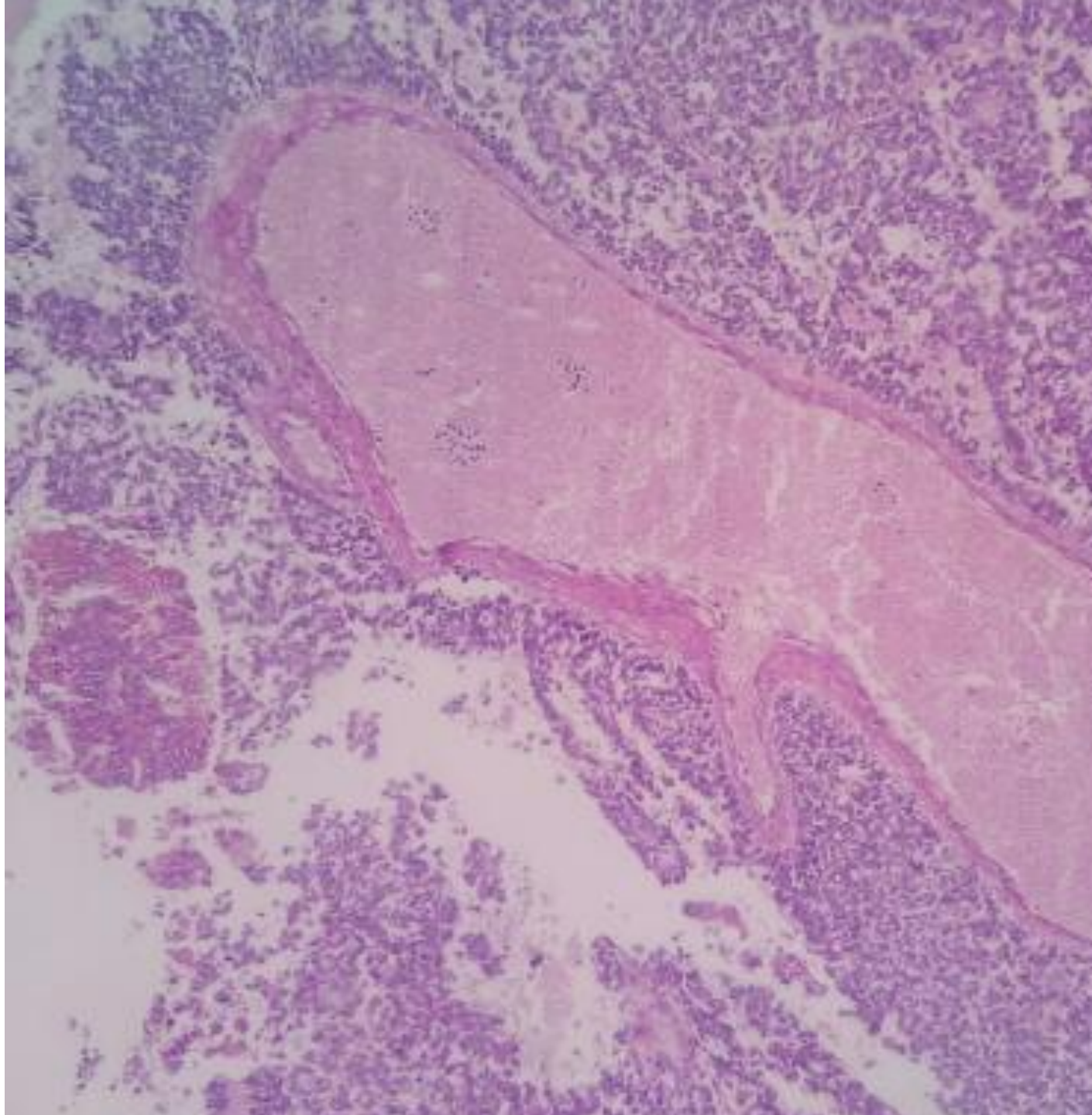


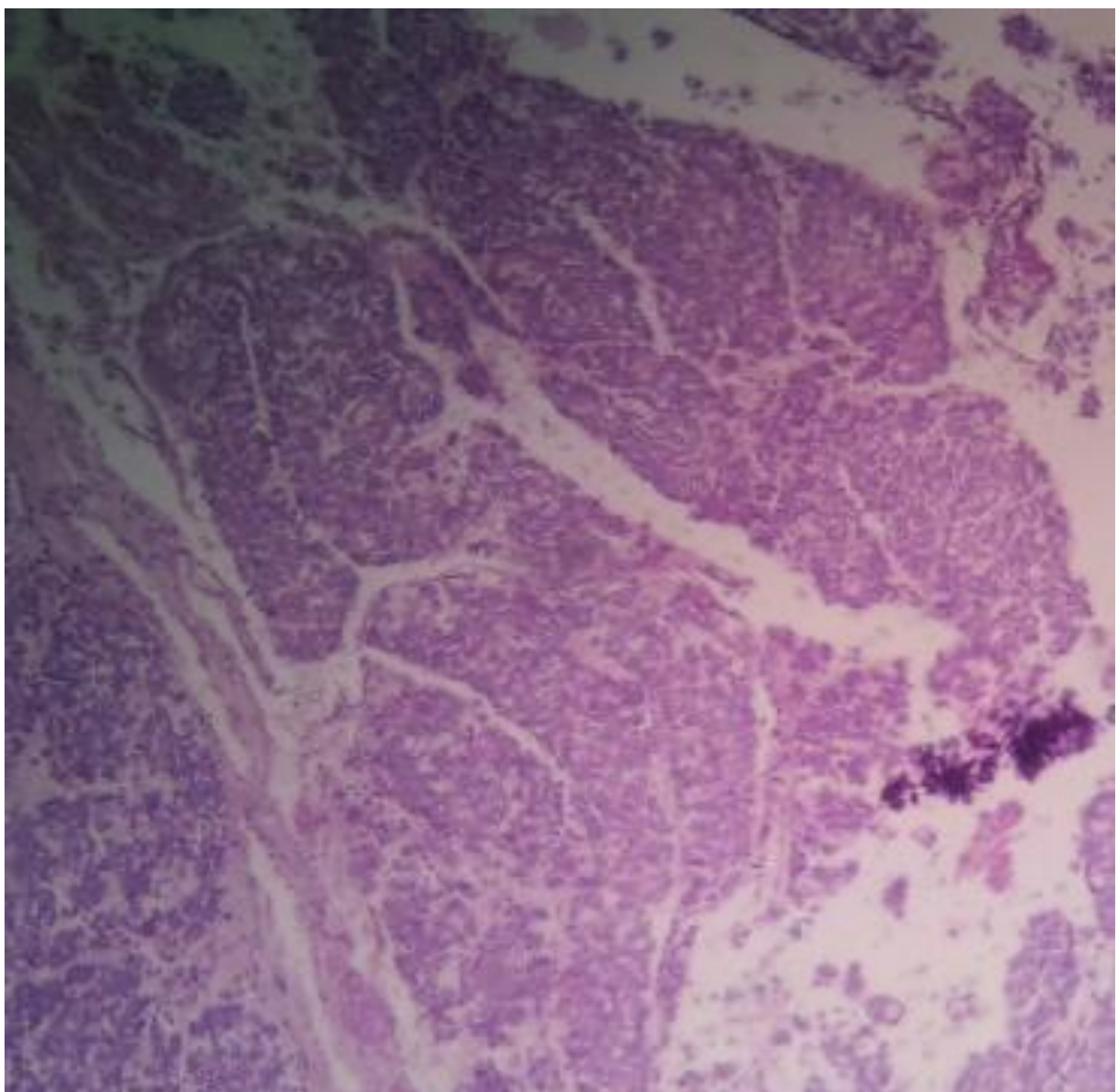


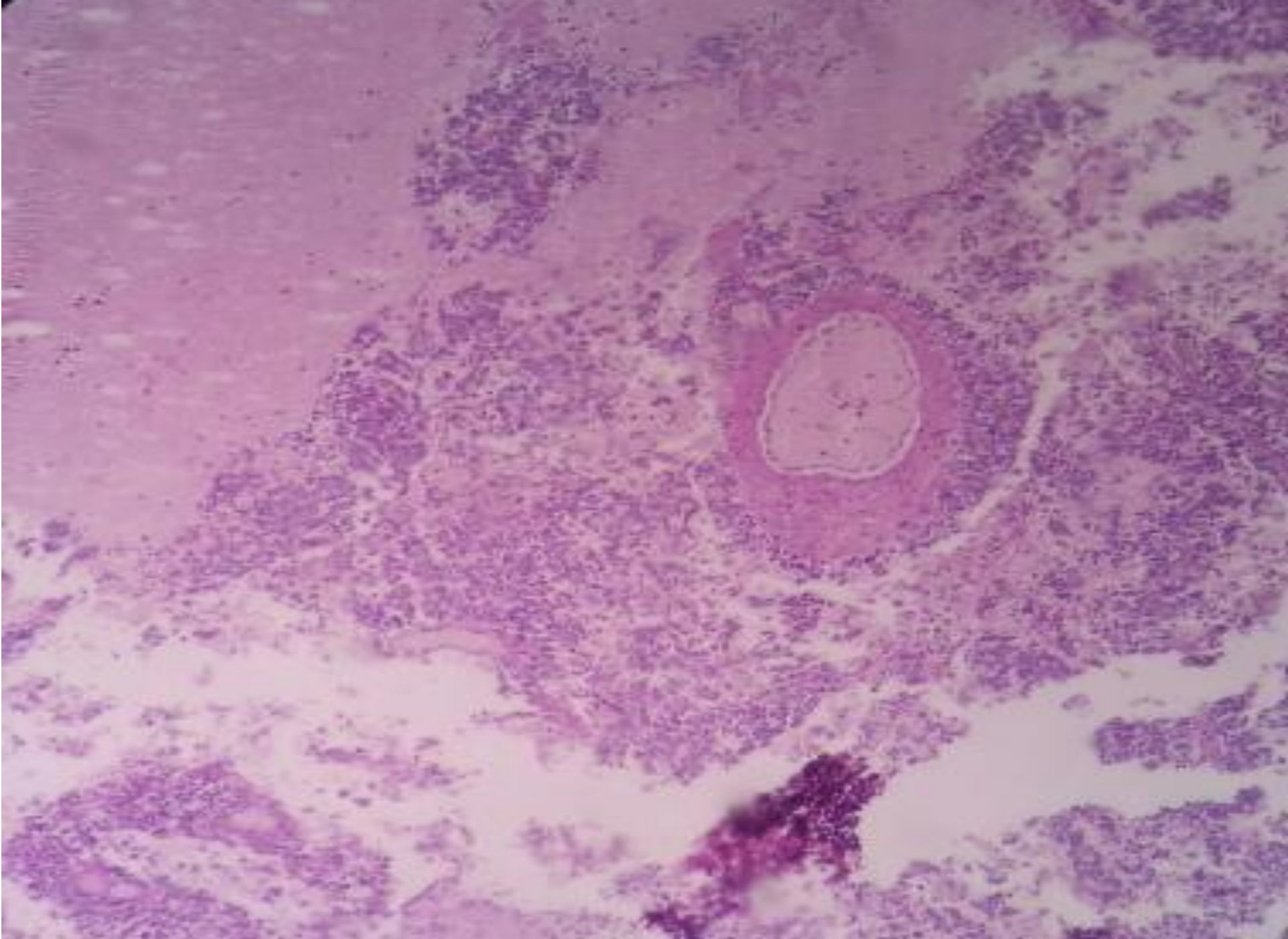


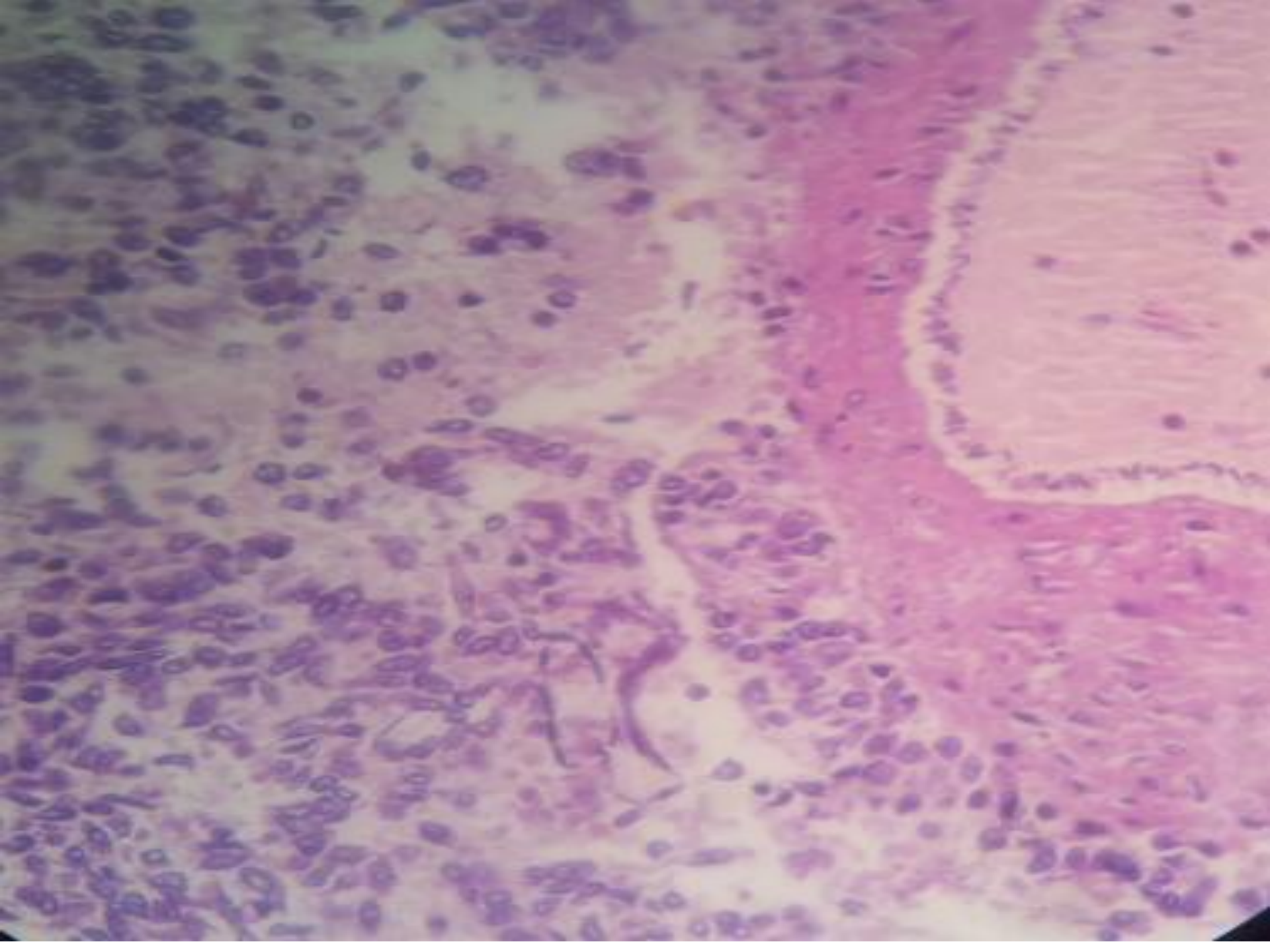
□ 8 Y.M. renal tumor

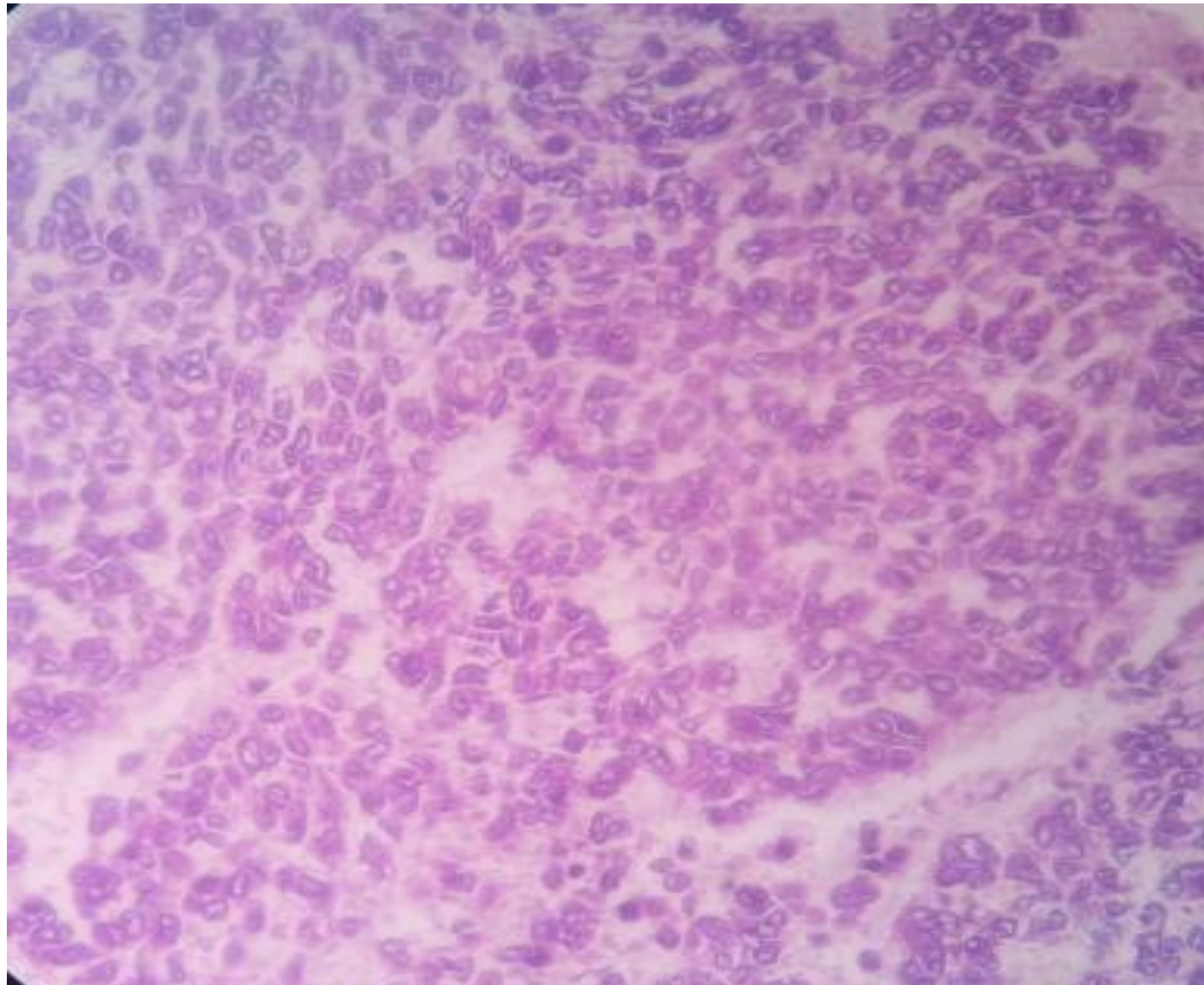


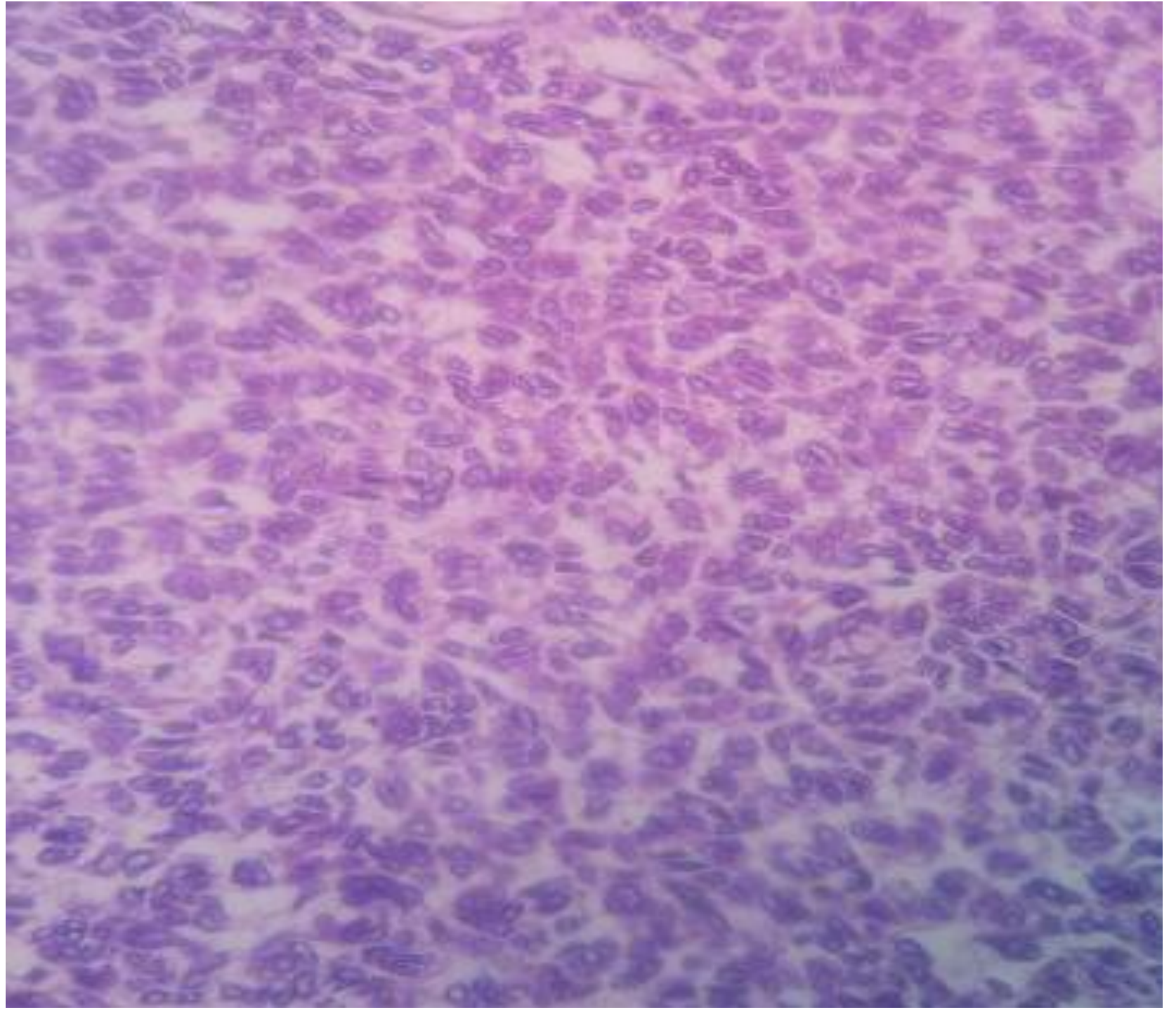




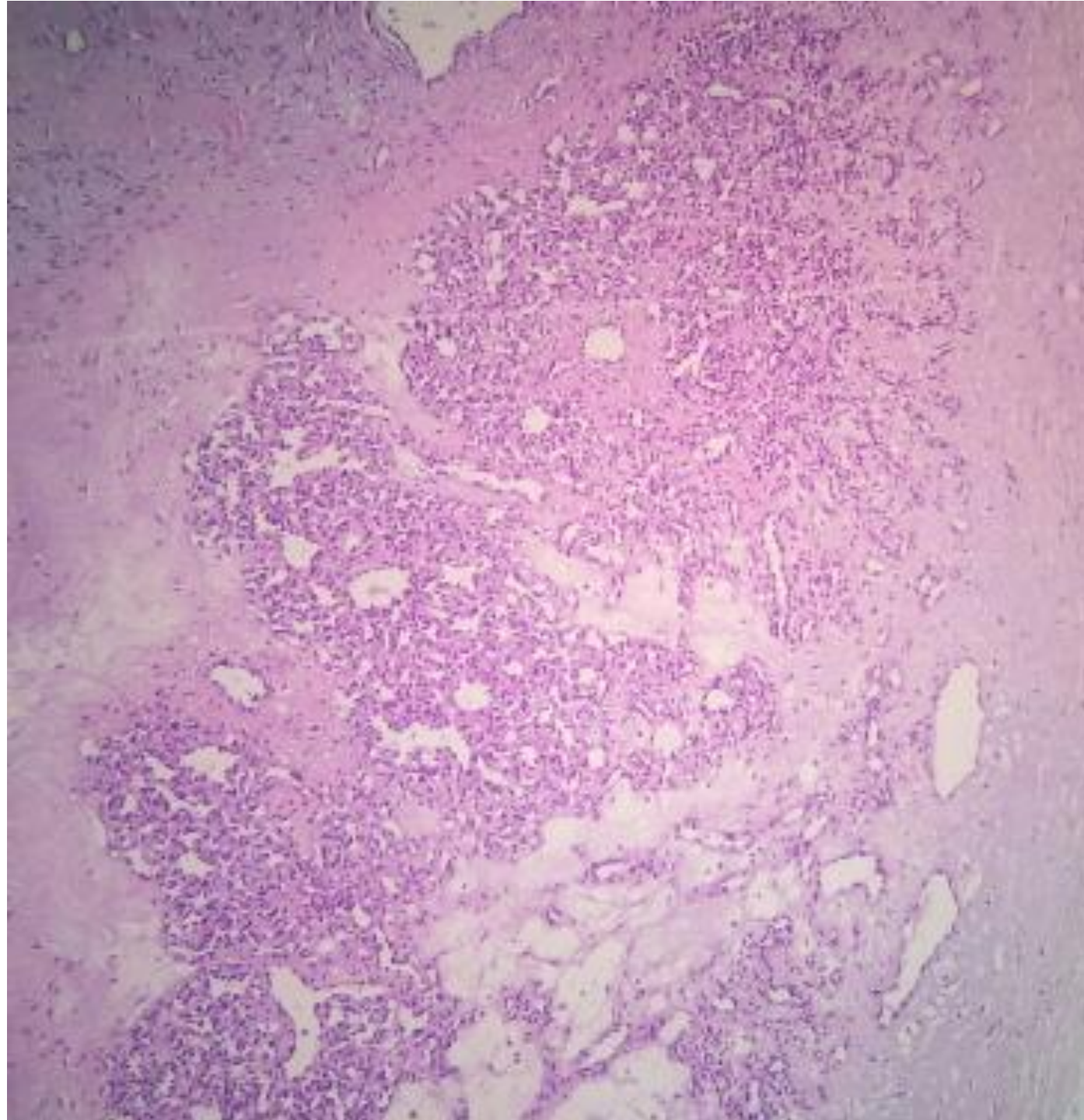


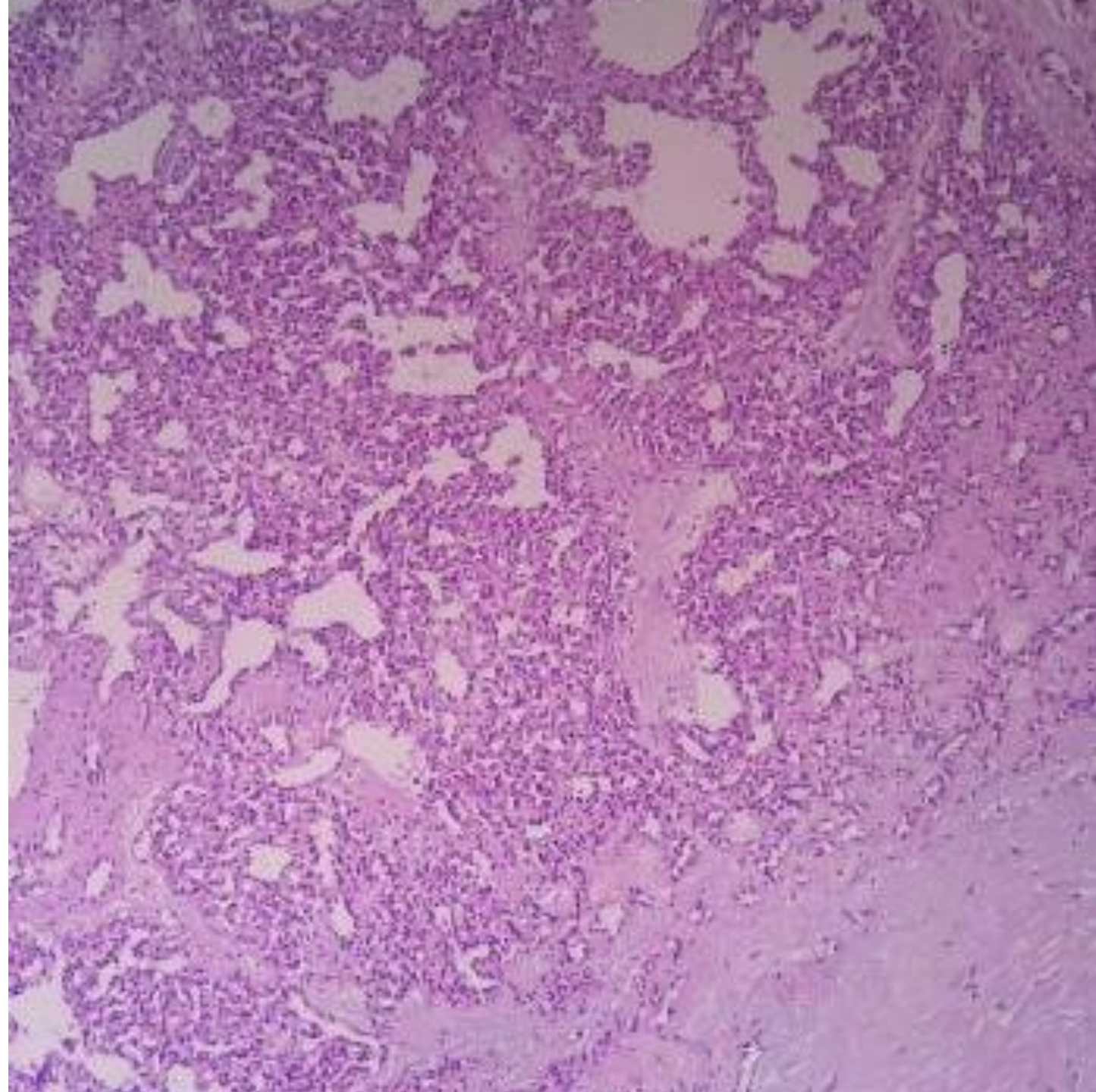


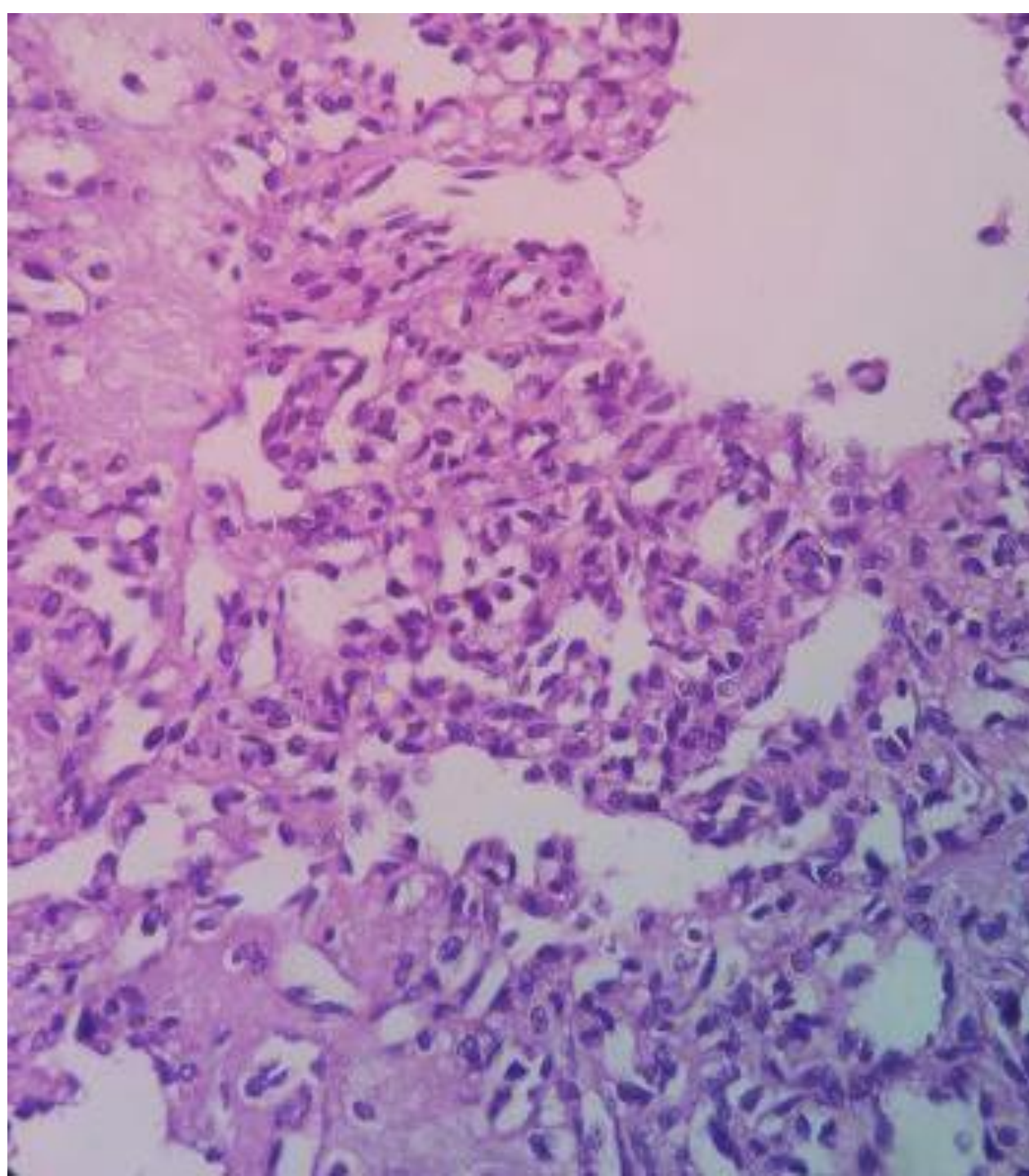


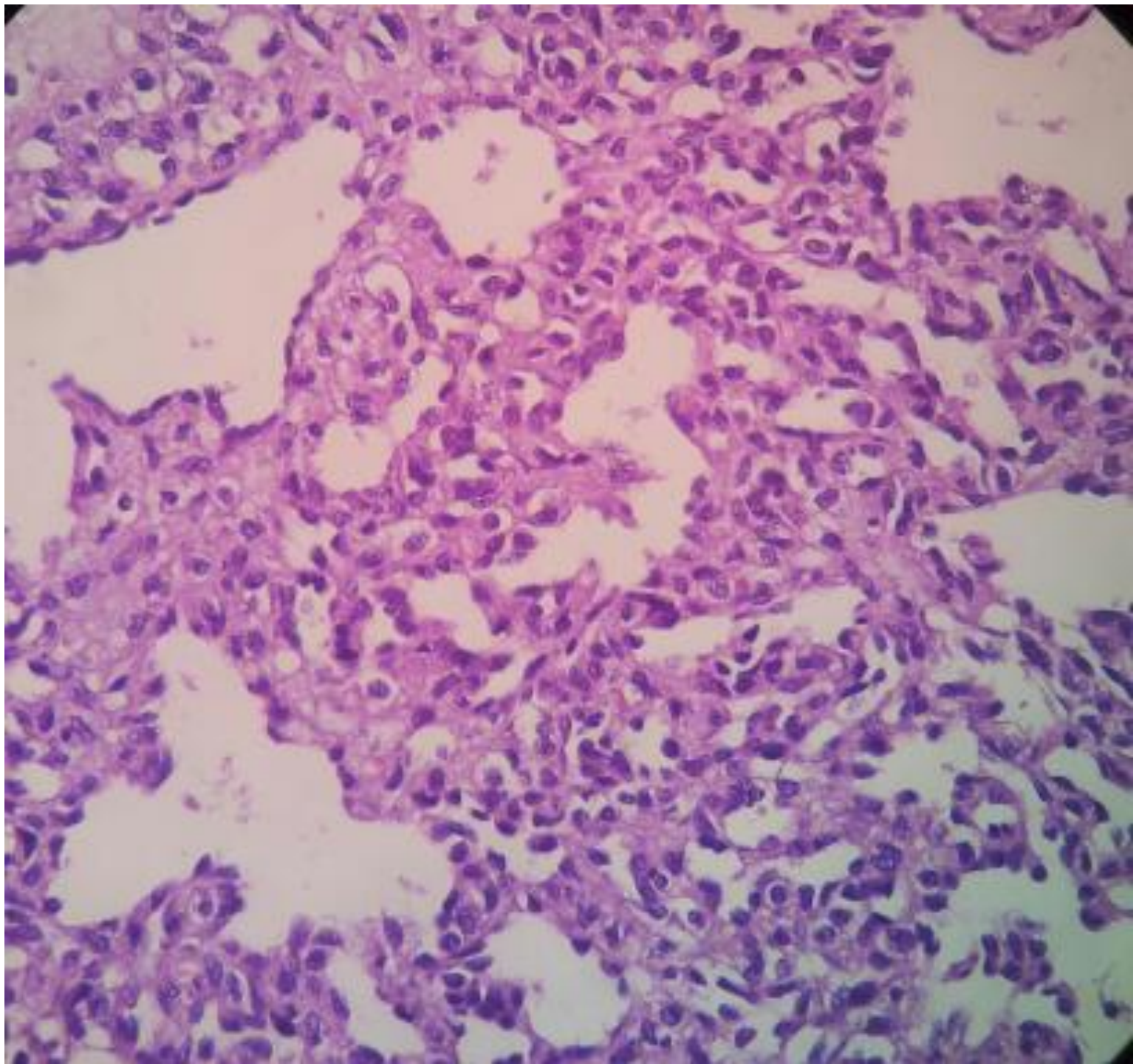


□ 5 Y.F leg mass.









THANK
YOU

