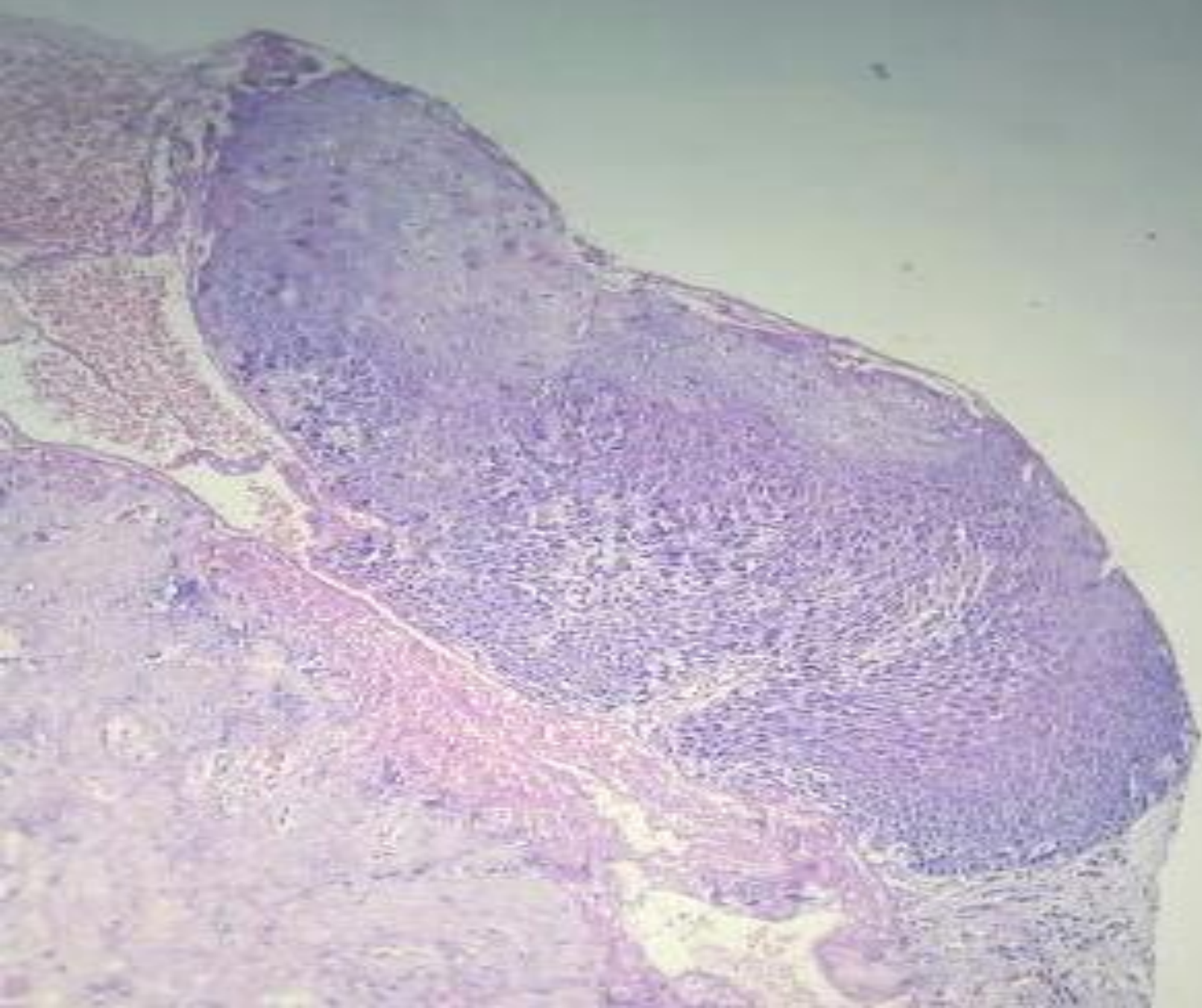
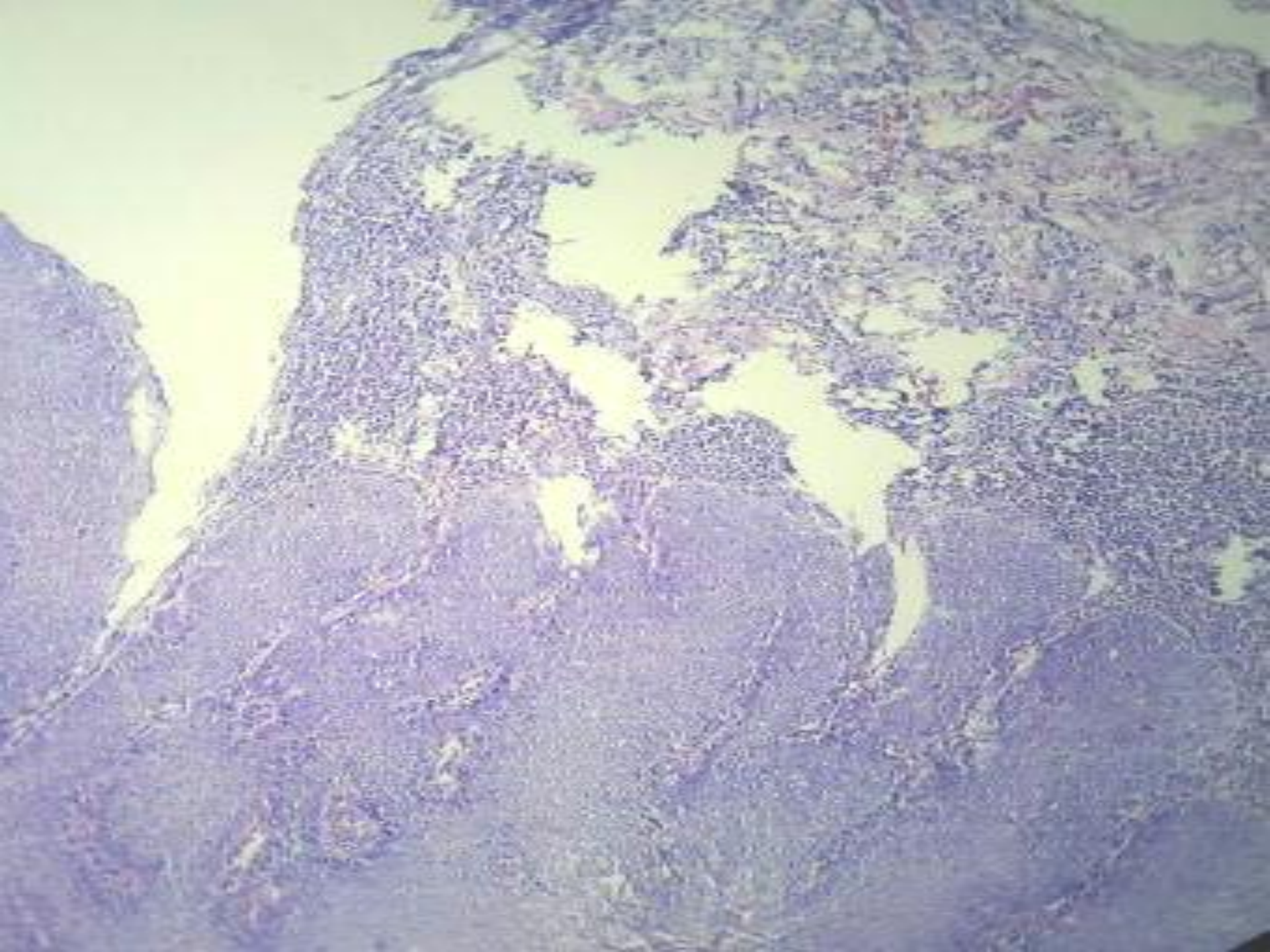
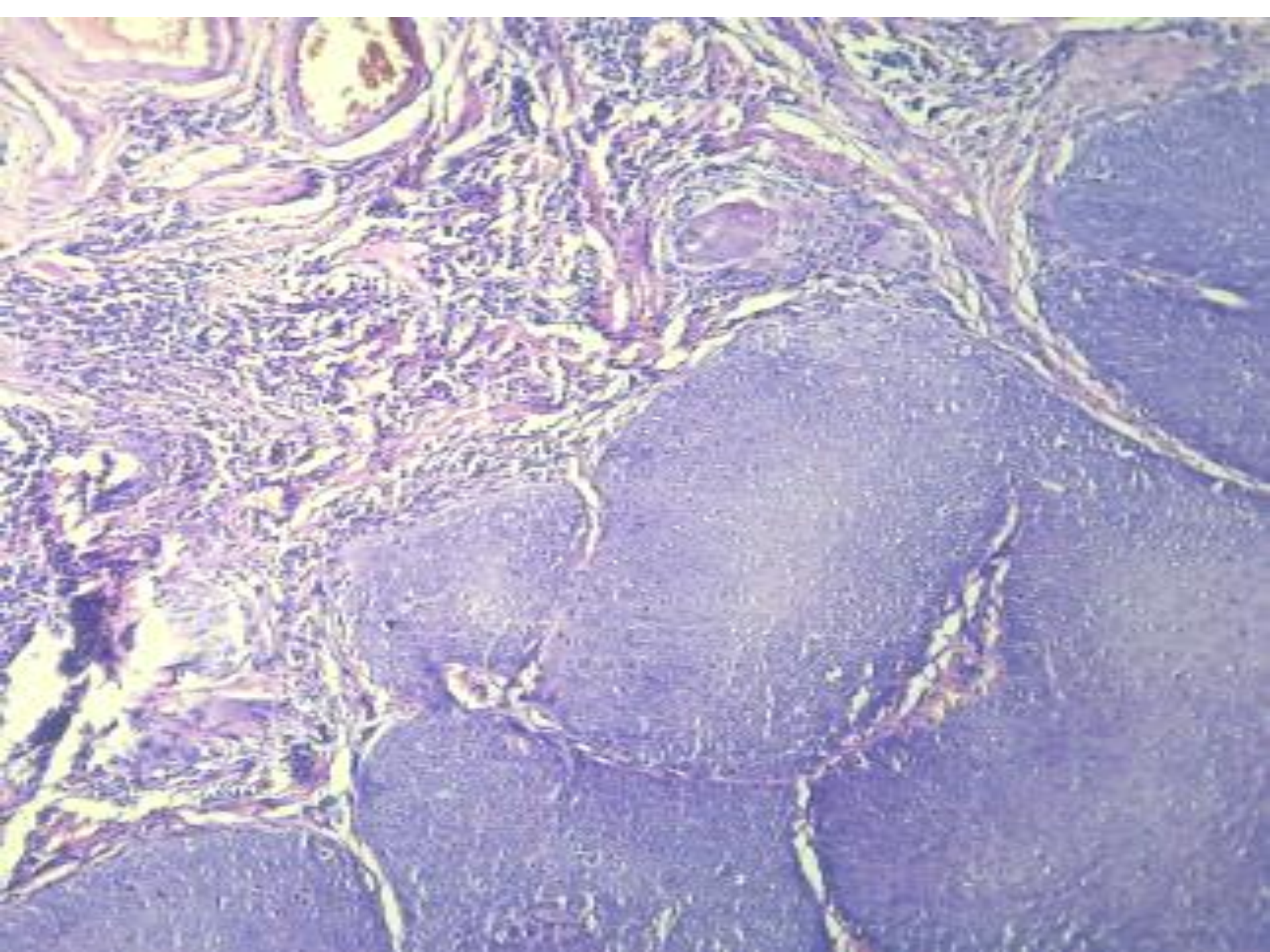


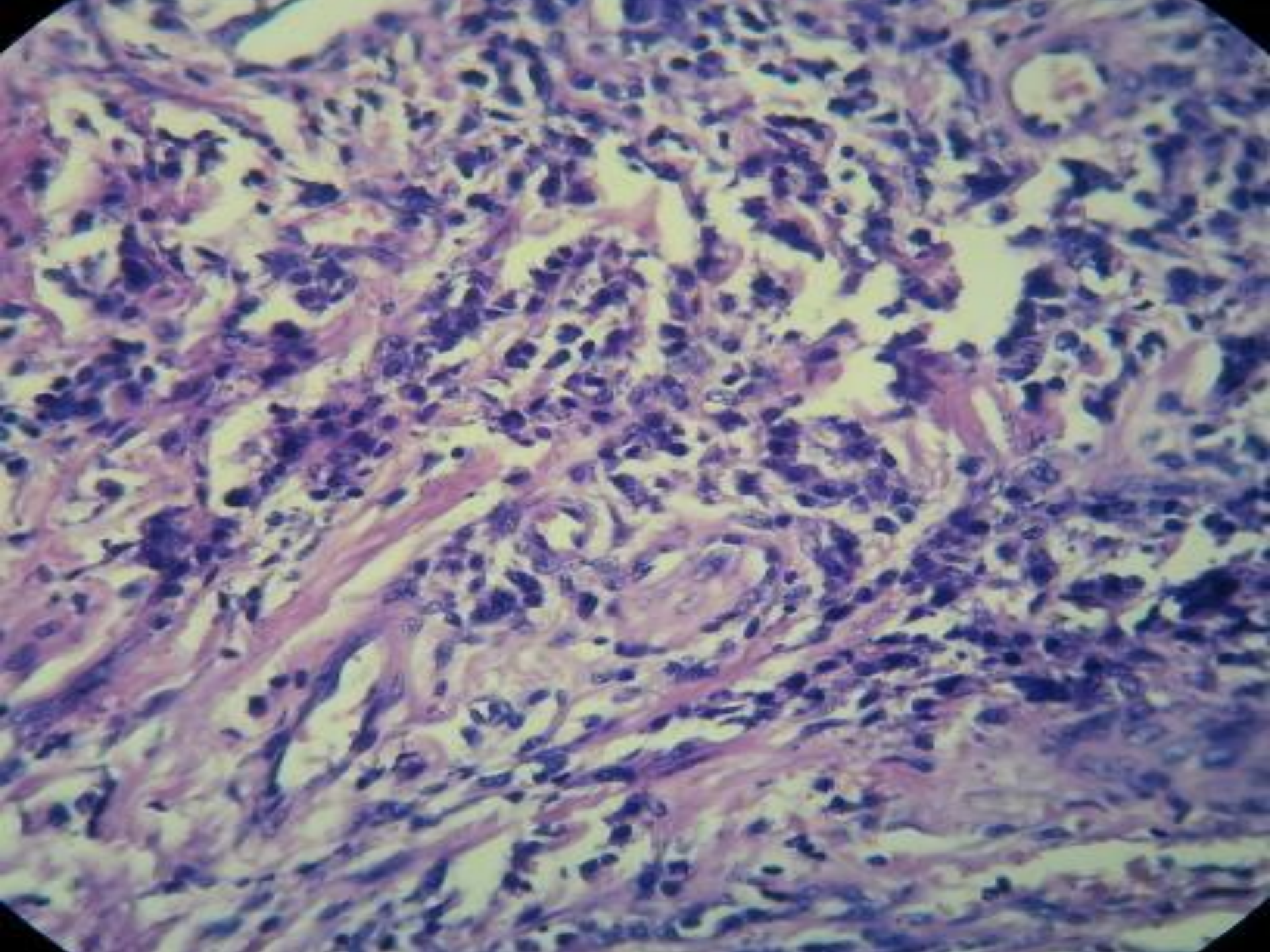
# 2<sup>nd</sup> Slide Meeting

- 65 Y.F. mass at lower lip.

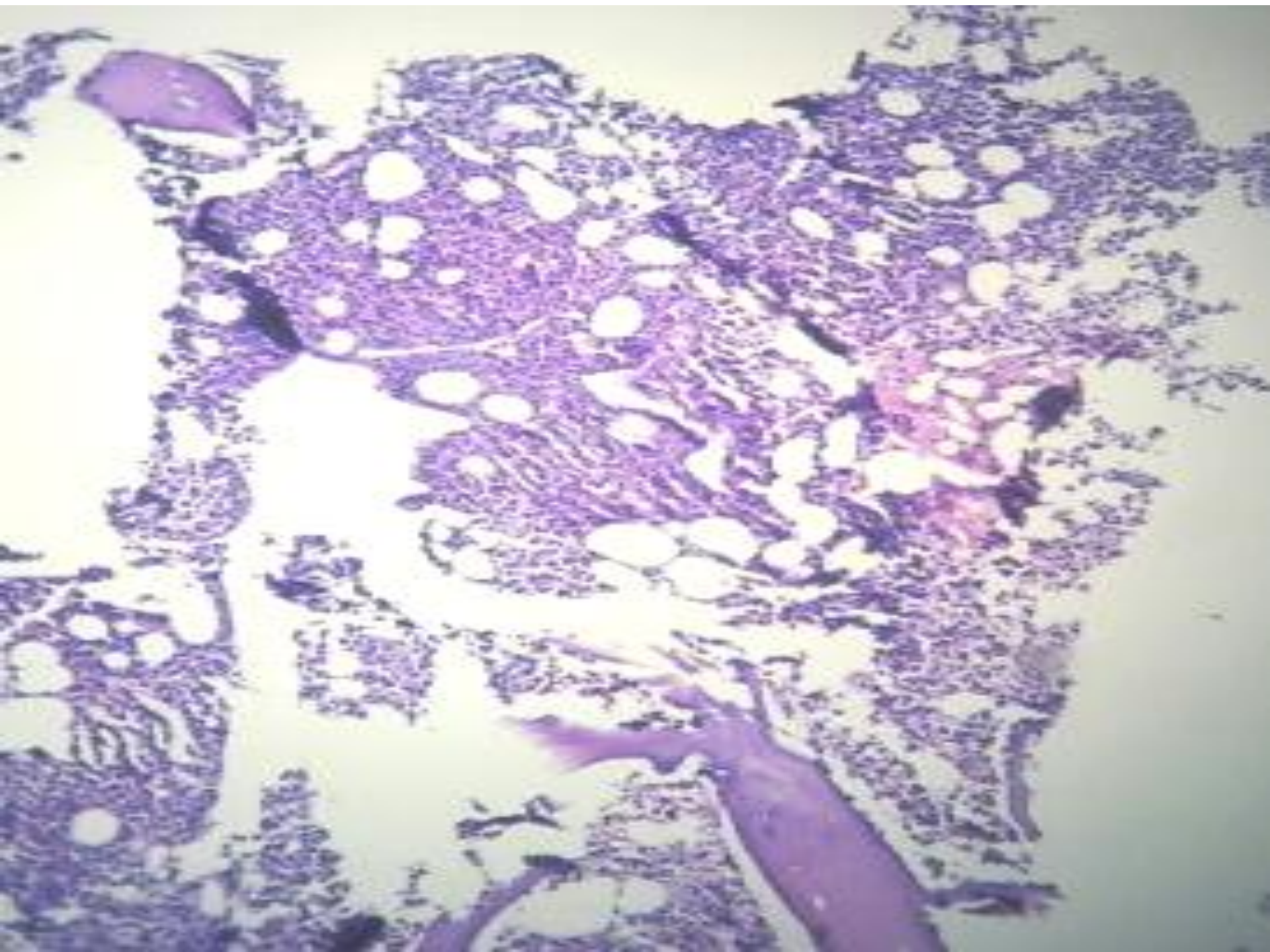




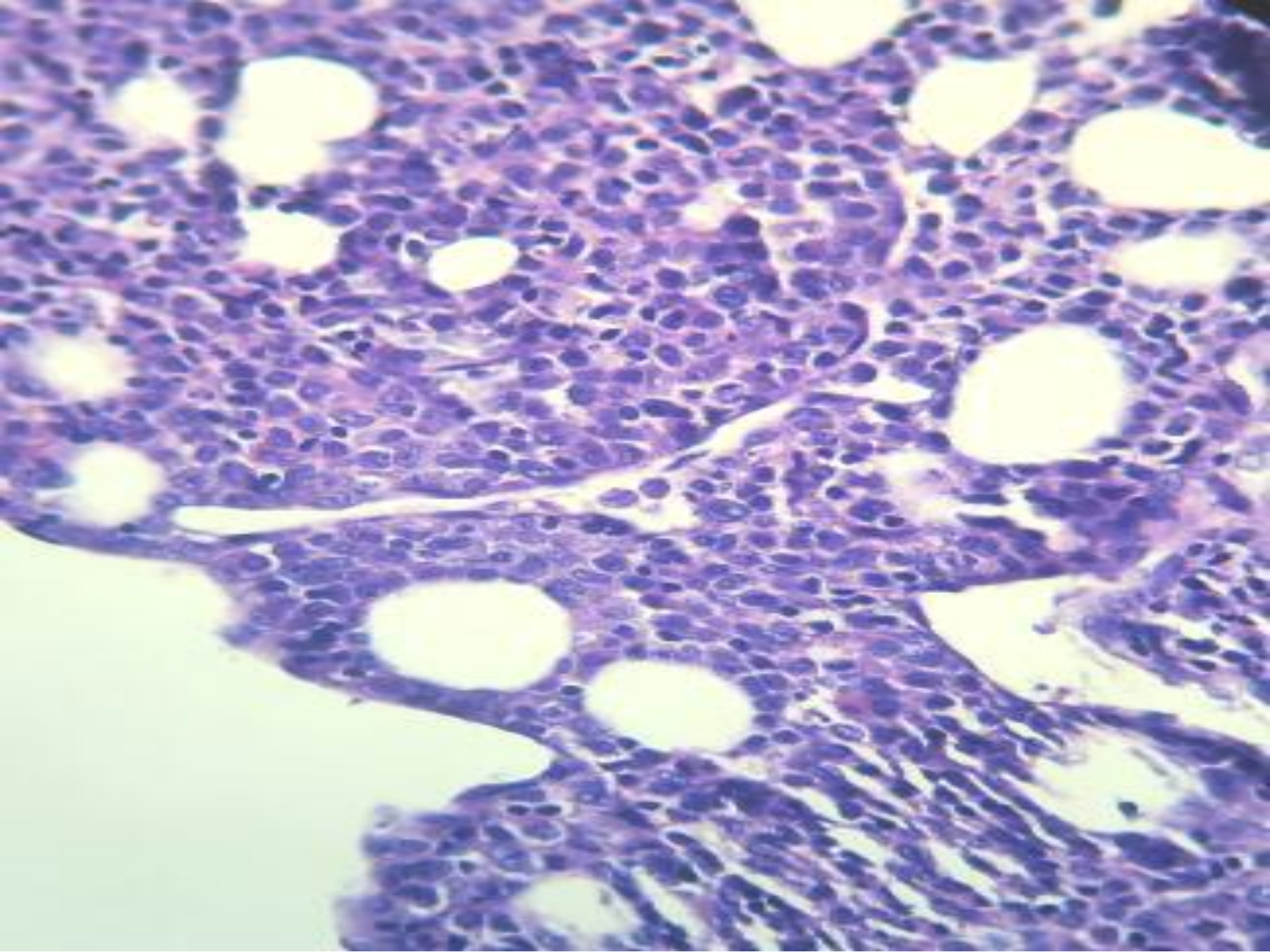


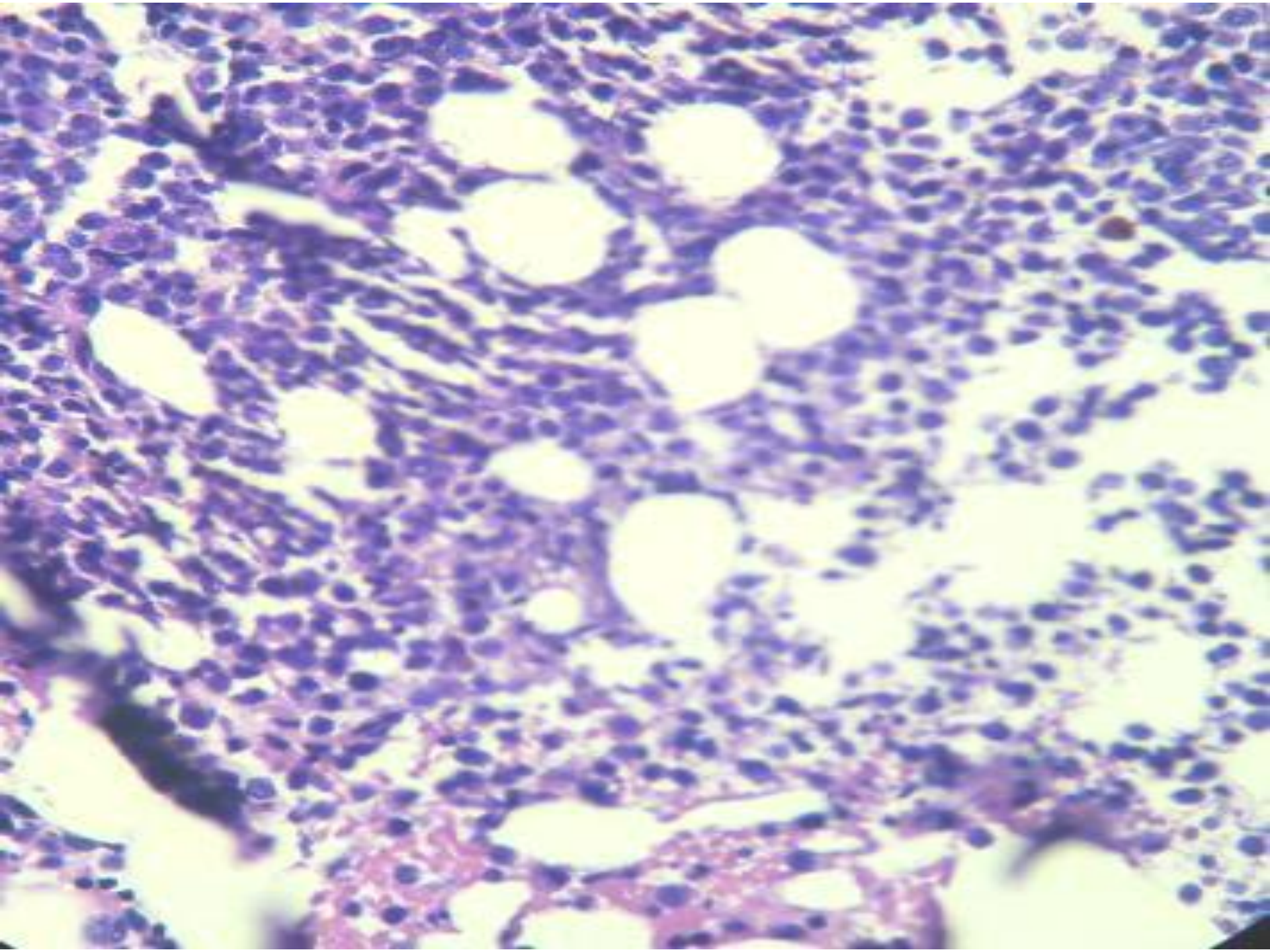


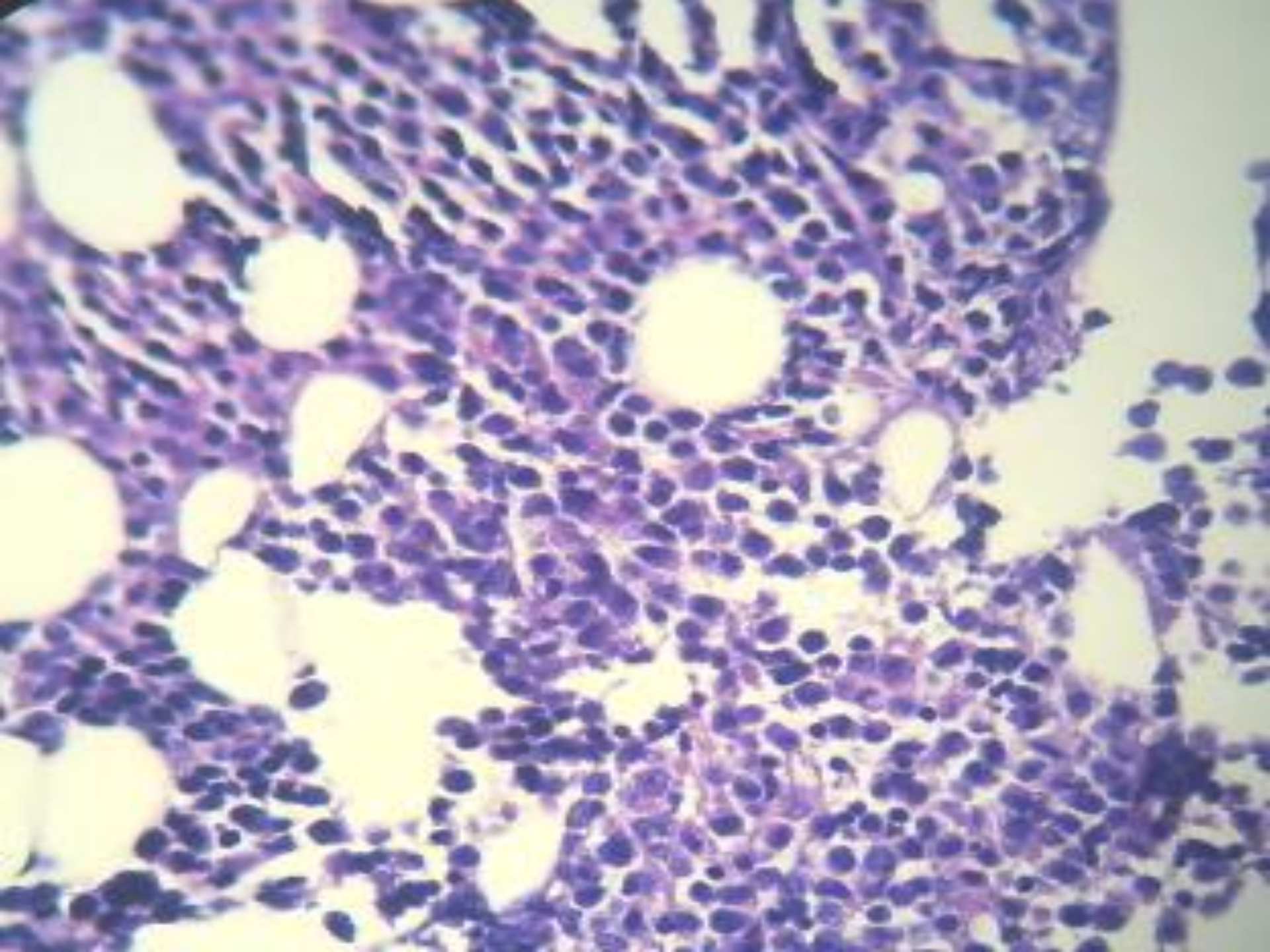
- 35 Y.M pancytopenia (Bone Marrow)











- 58 Y, M. polycystic kidney

