

بِسْمِ اللَّهِ الرَّحْمَنِ الرَّحِيمِ

Name: Amjed Saadon Sahee

Age : 8 years old

Residence: Tikrit

Chief complaint

Vomiting & fever for 3 days

History of present illness:

known case of (G6PD) deficiency, his illness started as diarrhoea for 2 days and stopped spontaneously without treatment & after about 10 days the patient developed vomiting, 3_4 times / day with fever, after 2 days, his mother noticed that color of urine became dark (tea color) & they consult a paediatric doctor who sent him for investigation and admitted him to the hospital, gave him 1 unit of whole blood & referred him to Mosul.

At 10/9/2013 admitted to Ibn sina hospital & renal biopsy done & referred to Erbil for peritoneal dialysis. In Erbil he was kept on peritoneal dialysis for (46 h) and continued by hemodialysis 3 sessions, received 3 units of packed RBC & 3 units of Plasma & returned to Mosul (Ibn sina hospital) in 25/9/2013 & continued on hemodialysis.

Review of other systems:

Nothing significant , except for CNS he developed 3 attacks of convulsion in Erbil .

Past medical history:

He exposed to an attack of hemolysis before 2 years and received 2 units of blood at that time.

Past surgical history:

Nothing significant

Drug history:

He prevented from drugs that may cause attacks of hemolysis.

Family history:

No similar condition in the family

On examination

Conscious , pale , jaundiced , no L.N. enlargement , no sign of bleeding.

PR 100 b/m

Temp 37.3° C

BP 110/70 mmhg

Chest clear

Heart NDR

Abdomen soft, no organomegaly

Investigations in Tikrit 4/9/2013

Hb:	9.3 g/dl	(11.5-15.5)
T.S.B:	1.6 mg/dl	(0.3-1.0)

At 5/9/2013

Hb:	7.6 g/dl	
T.S.B.:	1.9 mg/dl	
B. Urea:	93 mg/dl	(15-45)

General urine examination 4/9

Appearance: Deep Brown

Reaction: Acidic

Albumin: +++

Sugar: Nil

Bile salts: /

Bile pigment: /

Pus cells: (1-2) cell/HPF

RBCs: (1-3) cell/HPF

Crystals: Am.urate ++/HPF

Casts: Granular cast (+), Hyalin cast (few)/HPF

Epith. Cells: Few

Others: Nil

Investigations in Mosul 11/9/2013

Blood urea :	33.0 mmol/l	(3.3-7.5)
S. Creatinine :	722 μ mol/l	(60-115)
S. Sodium:	126 mmol/l	(136-155)
S. Potassium:	4.7 mmol/l	(3.5-5.5)
S. Phosphorus:	2.6 mmol/l	(0.8-1.6)
Ionized Ca ⁺⁺ :	1.0 mmol/l	(1.0-1.3)

.....

PT: 14 sec. (control 13 sec.) , INR: 1.1

APTT: 30 sec. (control 30 sec.)

Investigations in Erbil 12/9

Blood urea :	230 mg/dl	(10 – 50)
S. Creatinine :	5.6 mg/dl	(0.7 - 1.4)
S.L.D.H.:	1710 U/l	(up to 250)
S. Sodium:	120 mmol/l	(136-155)
S. Potassium:	4.2 mmol/l	(3.5-5.5)
S. Calcium	7.4 mg/dl	(8.5 – 10.5)

.....

Serology: HBV,HCV,HIV : negative

Investigations 14/9

C ₃	110	mg/dl	NR(90-180)
C ₄	26	mg/dl	NR(10-40)
ANA	2.69	IU/ml	Negative < 12
ds DNA Ab	1.89	IU/ml	Negative < 12

U/S of Abdomen

Normal size liver , spleen , pancreas

G.B. is contracted, normal biliary tree

Both kidneys mildly enlarged with slight increase in echogenicity but still preserved corticomedullary distance , no stones

normal U.B.

CBP in Mosul 30/9

RBC	2.5 *10 ¹² /l	(4-5.2)
Hb	7.4 g/dl	(11.5-15.5)
HCT	24.2 l/l	(35-45)
MCV	96 fl	(77-95)
MCH	29.6 pg	(25-33)
MCHC	30.6 g/dl	(31-37)
RDW	18.5 %	(11.6-14)
WBC	7.9 *10 ⁹ /l	(5-13)
Diff.	(N 61% , L 29% , M 6% , E 3% , B 1%)	
Plt	84 *10 ⁹ /l	(170-450)
Retic.	8 %	(0.5-2.5)
ESR :	10 mm/hour	

RBC : Normochromic normocytic, with many fragmented cells & echinocytes

WBC: Mature WBC

Plt : Moderatly Reduced

Biochemical 30/9

Blood urea :	17.0 mmol/l	(3.3-7.5)
S. Creatinine :	115 μ mol/l	(60-115)
S. Sodium:	136 mmol/l	(136-155)
S. Calcium:	2.03 mmol/l	(2.1-2.6)

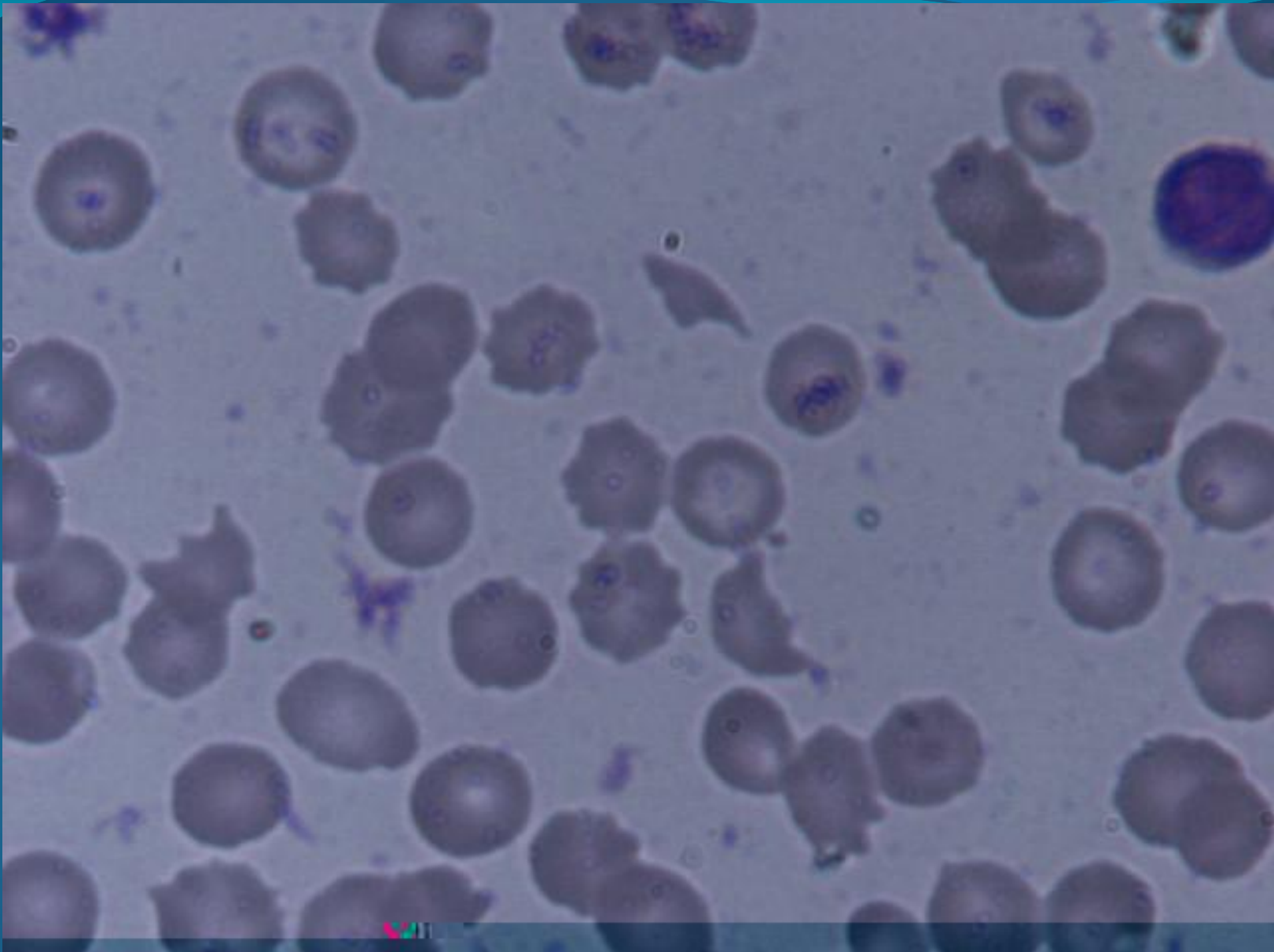
.....

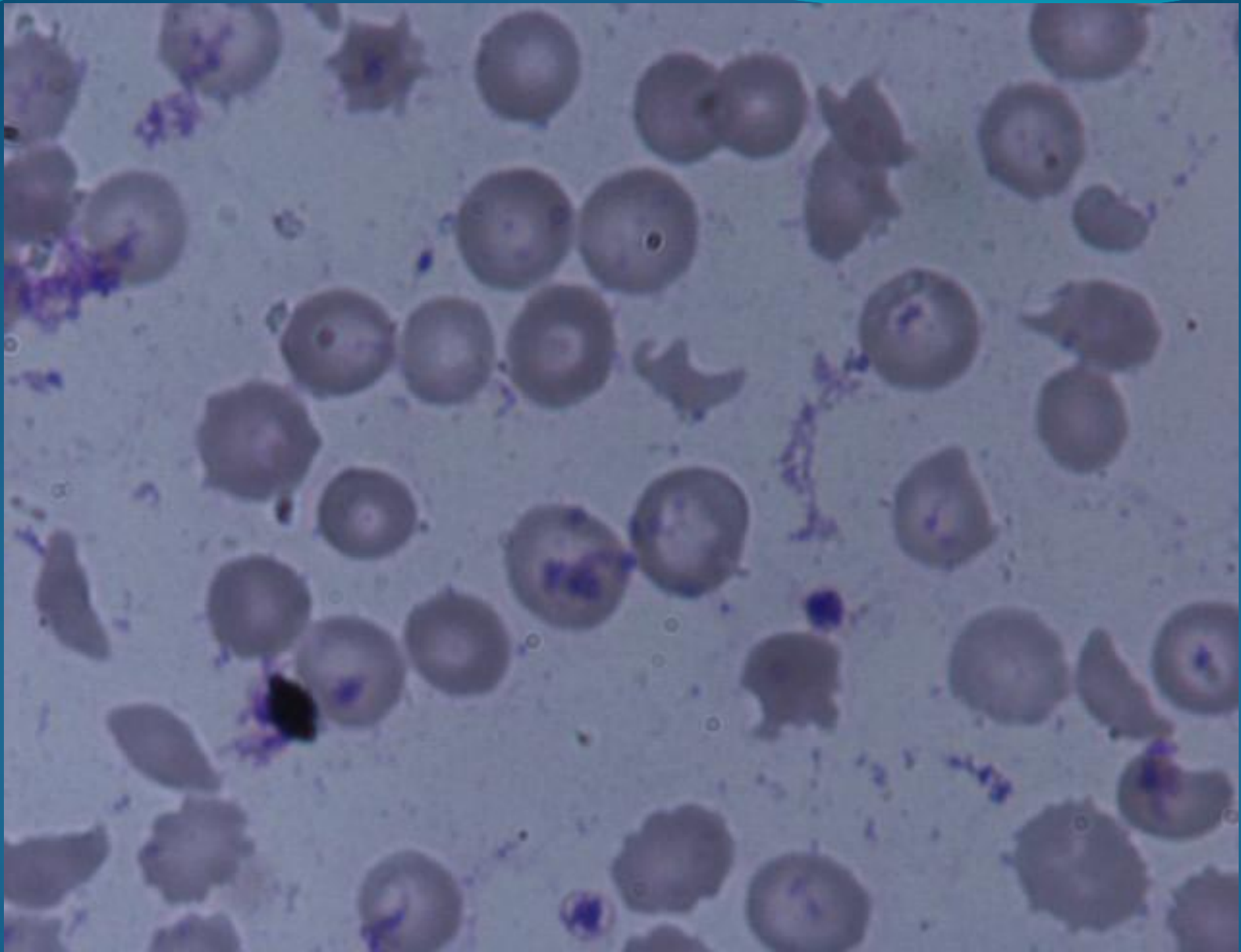
PT: 13.5 sec. (control 13 sec.) , INR: 1.1

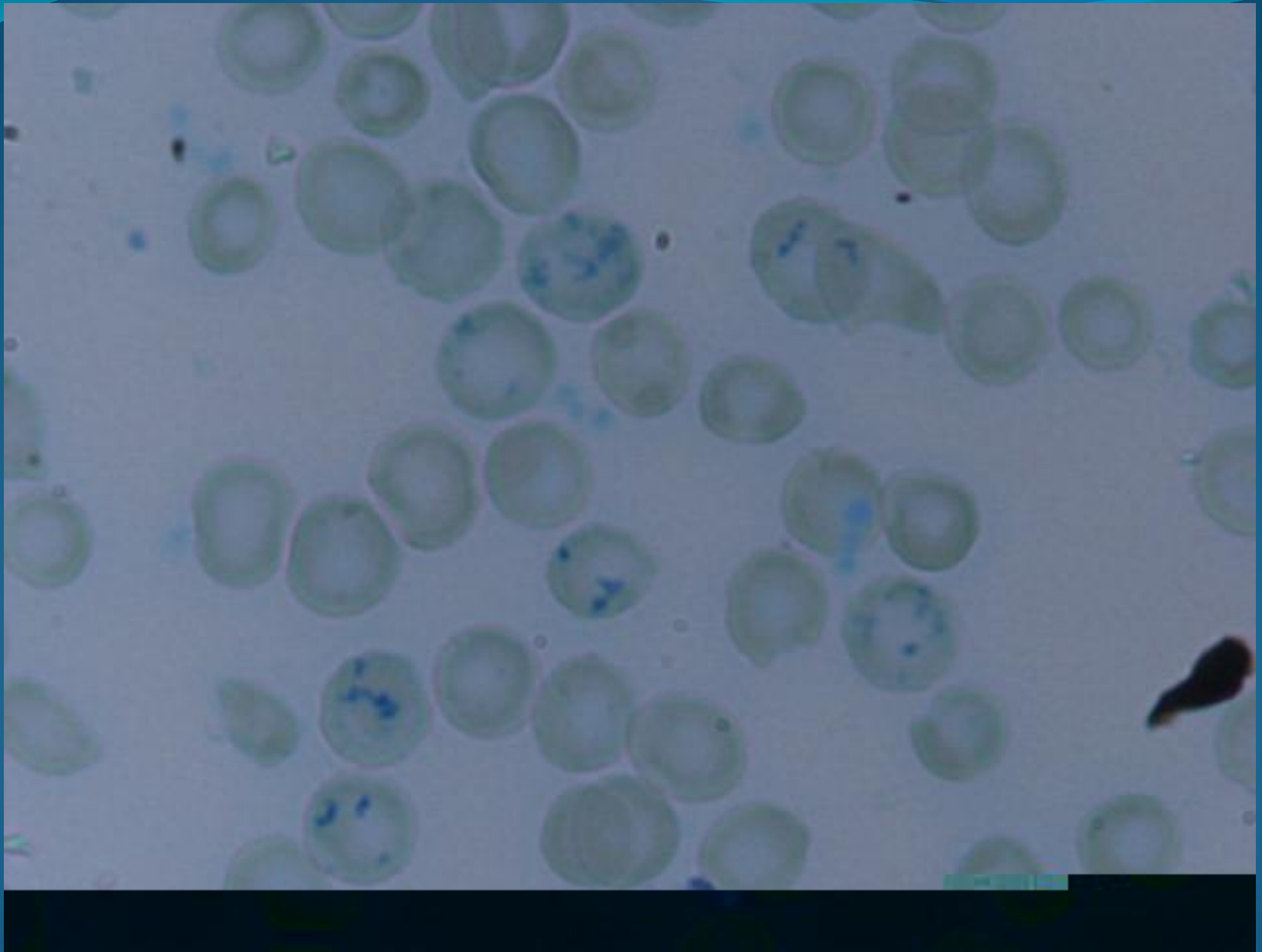
APTT: 35 sec. (control 30 sec.)

D.Dimer (latex agglutination): positive

Direct coombs test: negative

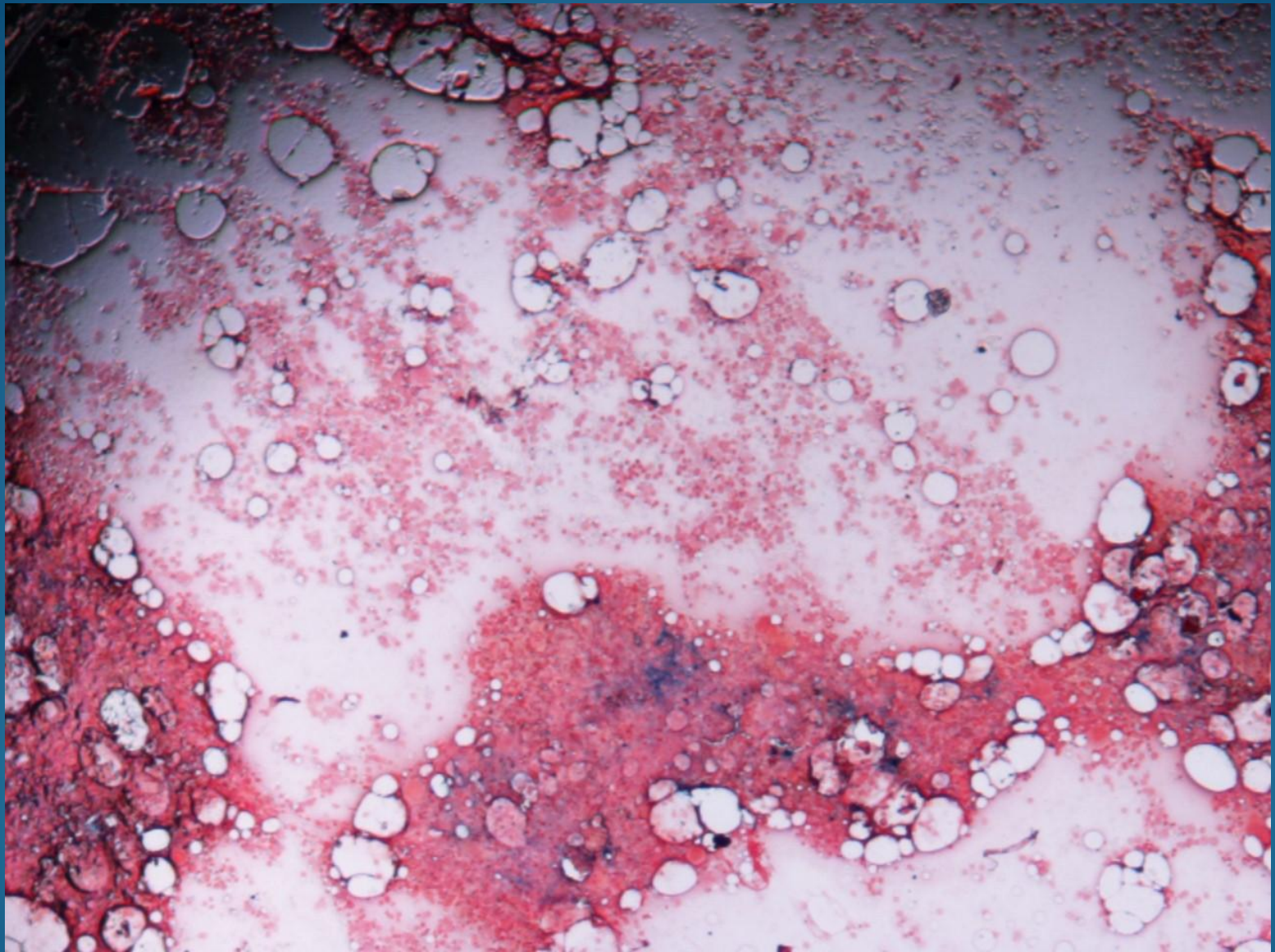





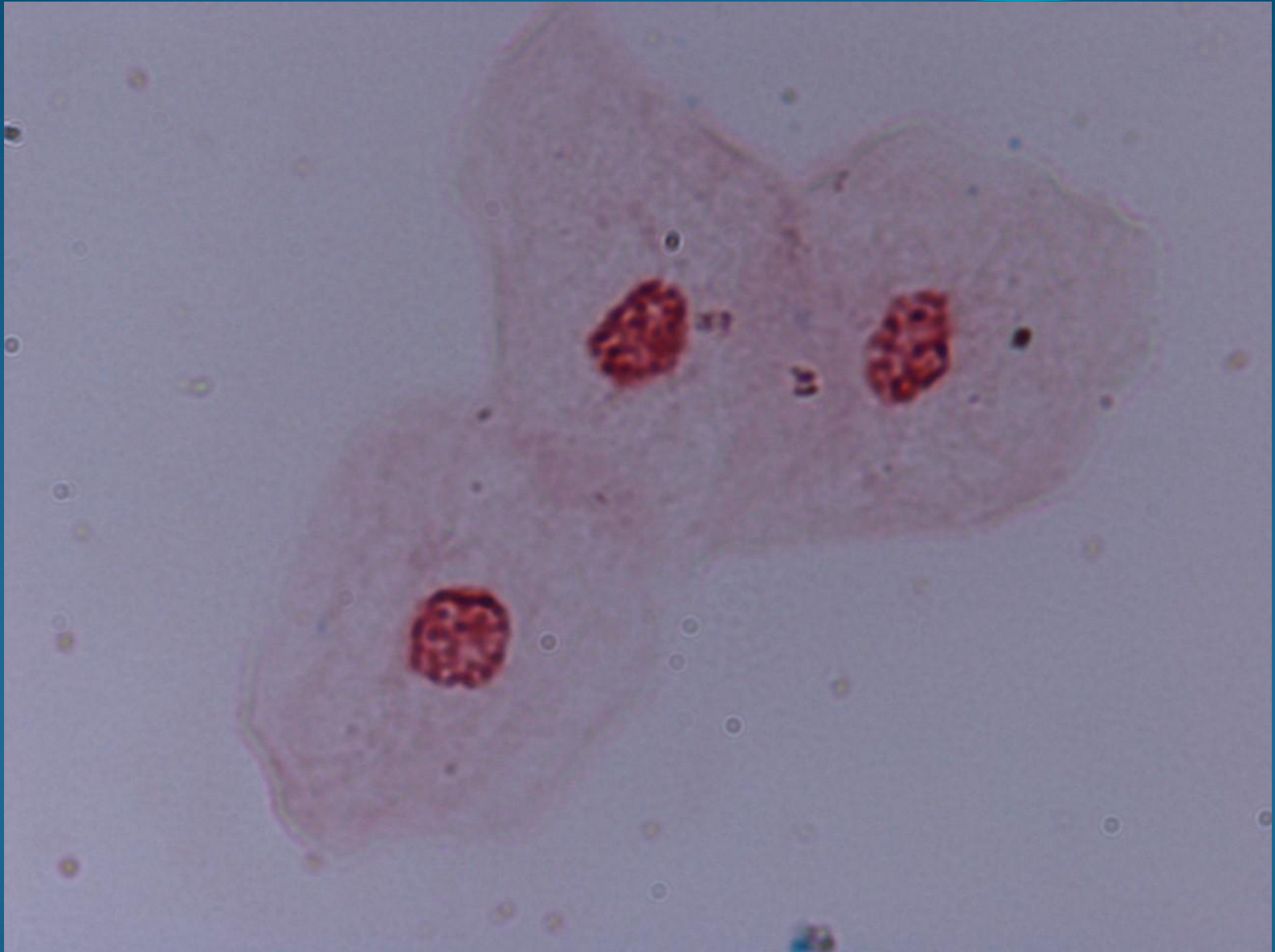


Haemoglobinuria: positive

Haemosiderin in urine: negative







Histopathology Report

Comment: It is not clear whether this thrombotic micro-angiopathy might be diarrhoea associated. There are much fewer than 50% glomeruli involved which should be prognostically favorable

Treatment

- Lazix ampule
- Ceftriaxone vial
- One-alpha drops
- Amlodpin tab.
- Packed RBC (3 unit)
- Plasma exchange (5 sessions)
- Hemodialysis

Haemolytic–uraemic syndrome

- The *typical* form of HUS called diarrhoea - related HUS, or D(+) HUS, is acquired and occurs acutely and sporadically after gastrointestinal infections with toxin - producing bacteria particularly in infants and young children but sometimes also in adults.
- There are two forms of *a typical* HUS. One is *familial*, has a sporadic or chronic recurrent course and is due to the inherited deficiency of complement factor H or other complement components. It occurs mainly in infants or young children but at least one - third of cases also occur in adults.
- *Another atypical* form of HUS occurs at all ages in association with situations commonly seen also in association with TTP.

Diarrhoea - related HUS

This acute syndrome almost always occurs as a single sporadic episode, heralded 2 days to 2 weeks before by bloody diarrhoea.

- The typical symptoms are severe renal failure with oligoanuria, jaundice and haemorrhagic signs such as petechiae, haemolytic anaemia and raised levels of serum LDH, but usually less marked than in TTP.
- Serum creatinine and urea are definitely more abnormal than in TTP, while the presence of ultra-large VWF is much less frequent than in TTP.
- Signs of compensated DIC, with higher plasma levels of D-dimer are another distinctive feature.
- Neurological involvement is uncommon, although coma and seizures may occur in association with uraemia and hypertension

Aetiology

- The most common bacterial agent that causes the prodromal gastrointestinal infection is *Escherichia coli* type 0157:H7 or, less frequently, *Shigella dysenteriae* serotype I. These and other more rarely involved infectious agents produce similar forms of exotoxins called verotoxin, shiga toxin and shiga - like toxins.
- These toxins, after absorption from the gastrointestinal tract into blood, have in common the property to bind to a certain membrane receptors that are particularly dense in the glomerular capillary endothelial cells of infants, young children and elderly individuals.
- The toxin –receptor complex is endocytosed and thereby causes cytolysis and extensive endothelial swelling and desquamation, which inturn engenders massive thrombus formation in the renal microvasculature.

Pathology and pathogenesis

- The pathology of diarrhoea - related HUS is characterized by more extensive endothelial injury and less VWF and more fibrin deposition in thrombi than in TTP.
- The behaviour of plasma VWF is also different, because ultra - large highly thrombogenic multimers are detectable less frequently during the acute phase of the disease.
- This phenomenon is thought to be due to the fact that VWF multimers leaking in excess into plasma from damaged endothelial cells bind avidly to GPIb on the platelet membrane and are thereby removed from plasma, particularly the multimers of larger size.
- There is quasi - unanimity of views that ADAMTS - 13 is normal or only mildly reduced in the plasma of patients with this variant of HUS.

Familial HUS

- Autosomal recessive and dominant forms of familial HUS without diarrhoeal prodromes account for about 5 – 10% of all cases.
- This variant is associated with a markedly severe impairment of renal function and with a high mortality rate (approximately one - third of the cases).
- Approximately half of the patients who survive acute disease require maintenance haemodialysis.

Atypical (non - diarrhoea-related) HUS

- This form can only be distinguished from TTP by the absence of neurological symptoms and the predominance of renal symptoms.
- There are cases of atypical HUS associated with severe deficiency of ADAMTS - 13, albeit less frequently than in TTP.
- Atypical HUS is often associated with the postpartum period or with the intake of several drugs.
- Individuals who have been treated for various illnesses by bone marrow transplantation make up a relatively large subgroup.
- Plasma therapy, using the same protocol recommended for TTP, is the treatment of choice.

THANK
YOU