

BREAST EXERCISE

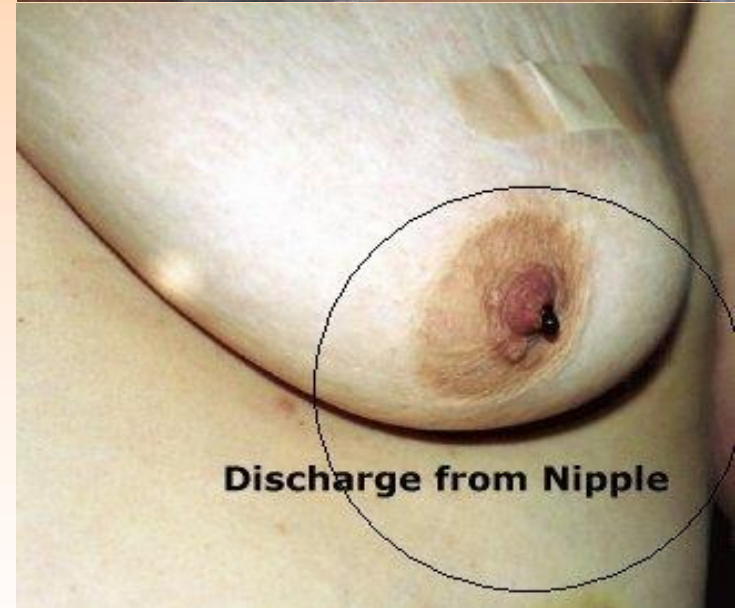
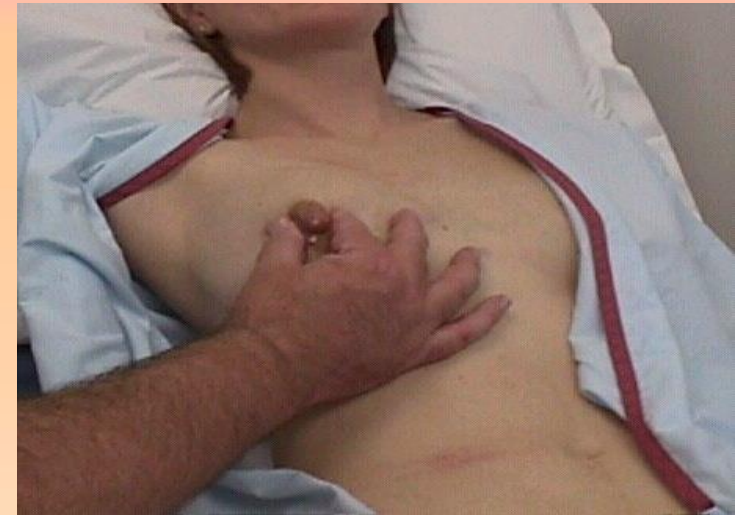Dr. Karam Kamal Younis
Dept of Surgery
Mosul Medical College
Mosul University
Mosul
IRAQ



**35 year- old lady with
bloody discharge from
nipple for 1 month**

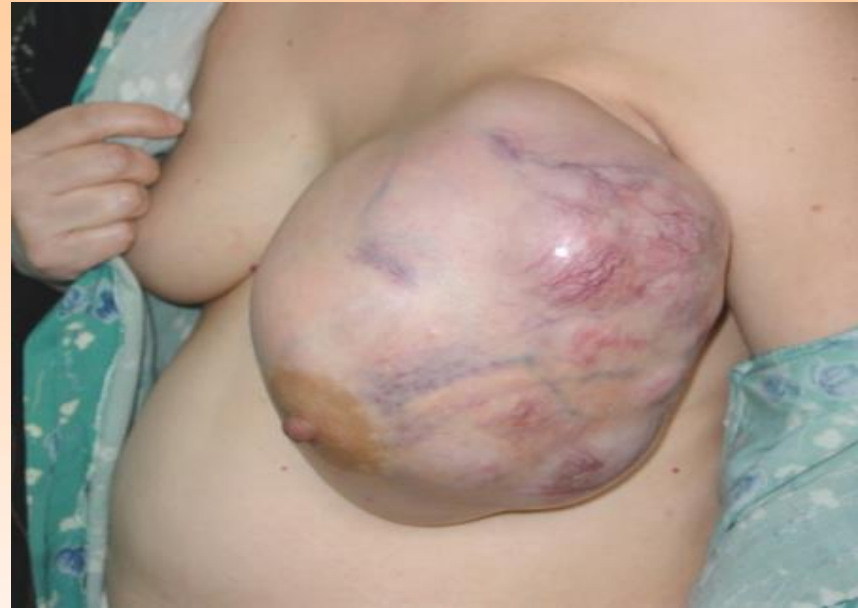**1- Give 3 possible
common causes**

**2-What are the 4 features
in bleeding that suggest
duct carcinoma?**



breast lump

- **What is the diagnosis?**
- **Describe the characteristic of breast surface here .**

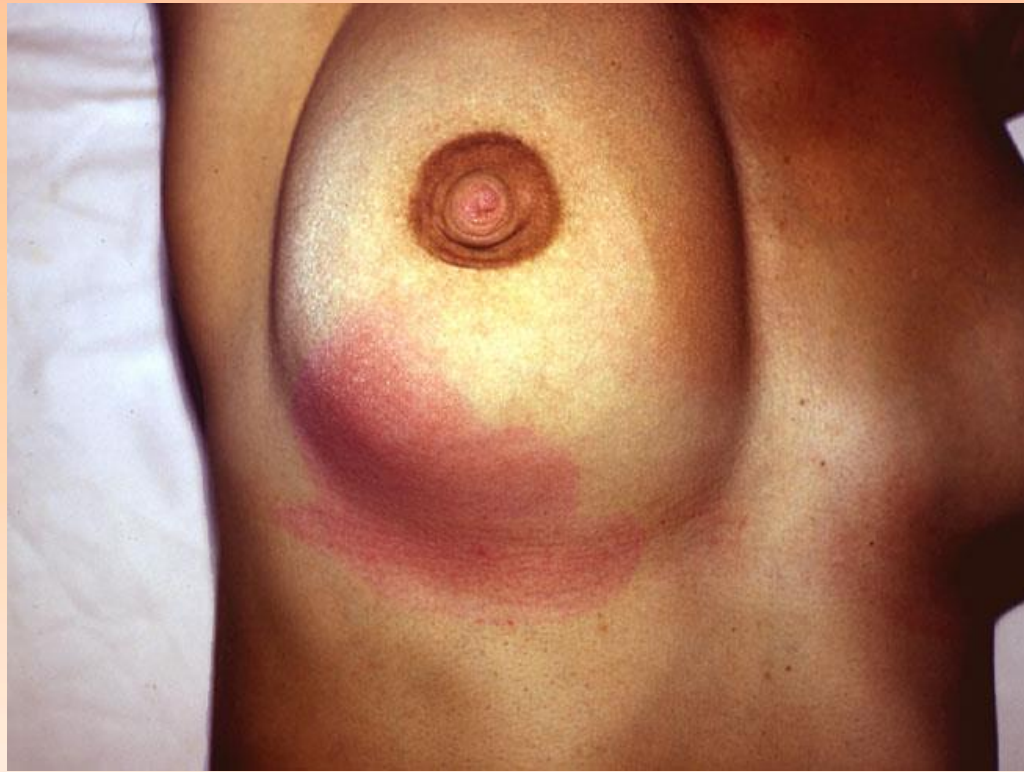



Old lady with two month history of this breast abnormality

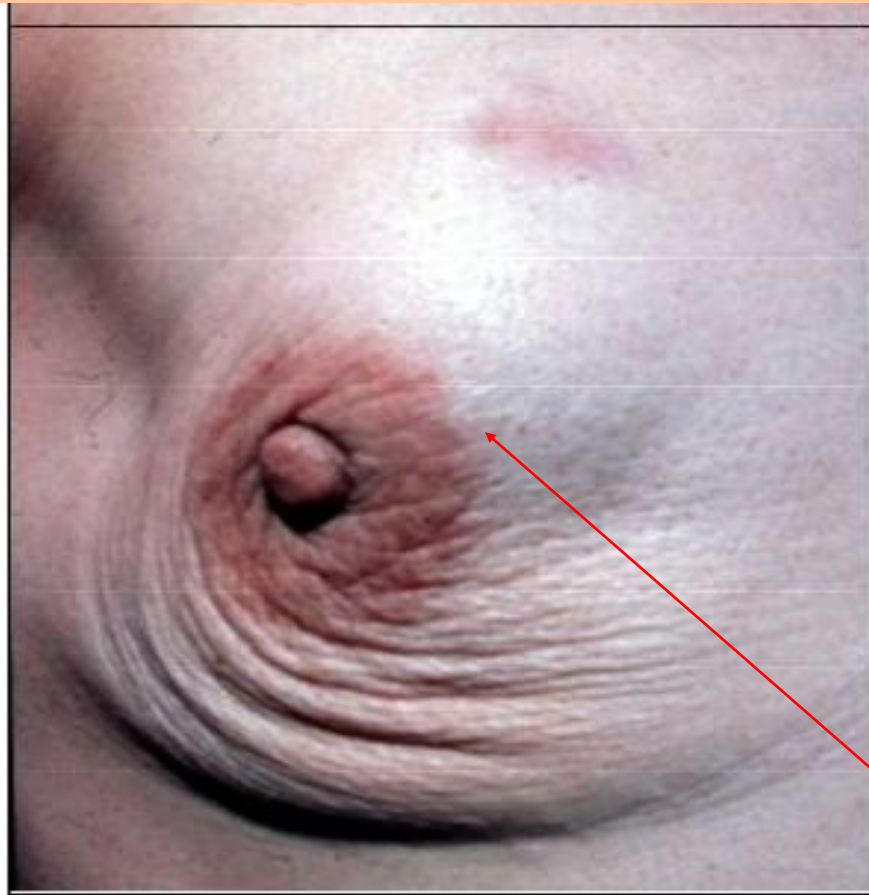
1- What 3 clinical signs do you see?

2- Name 2 probable causes for such a sign



30 year-old lactating lady with a painful breast.

- **What is this appearance typical of?**
- **What is the offending pathogen & its route of entry?**
- **What treatment you recommend?**



This 53 year old postmenopausal lady presented with this breast lump.

What is the differential diagnosis for a breast lump?

-)a) What is most likely in a woman aged 22?**
-)b) What is most likely in a woman aged 40?**
-)c) What is most likely in a woman aged 70?**



)a) Fibroadenoma

)b)- Breast Cyst

- Breast Abscess

- Fibrocystic changes

)c) Breast Cancer

This young female
had progressive enlargement of her left
breast & a hard lump

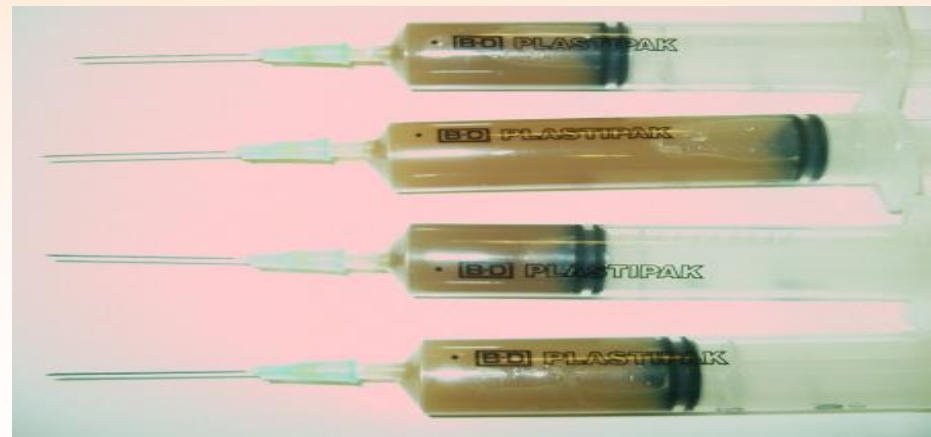
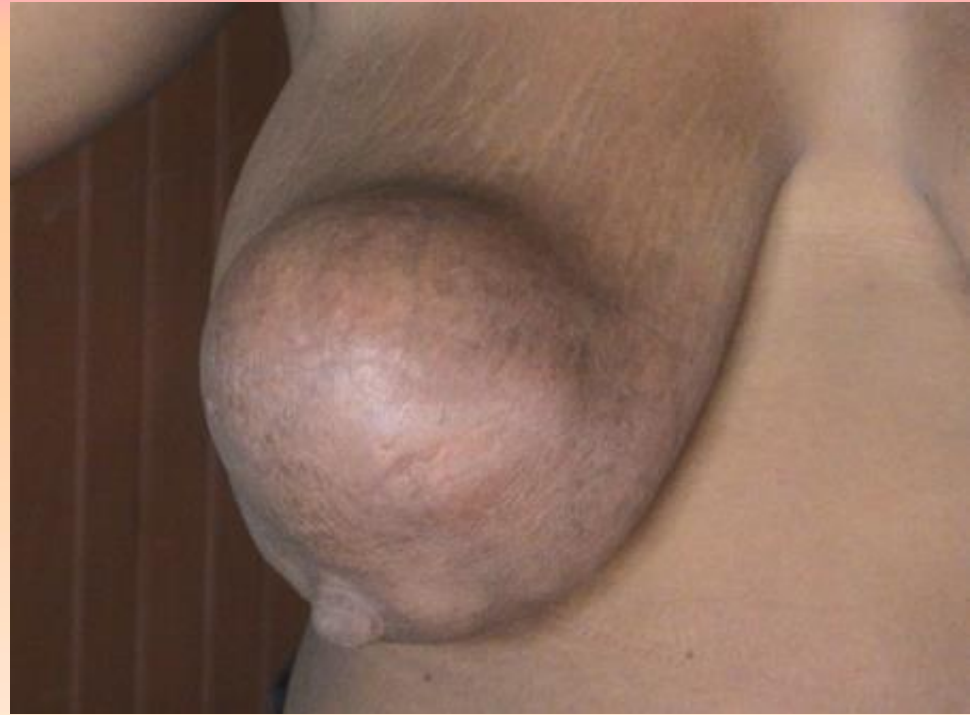
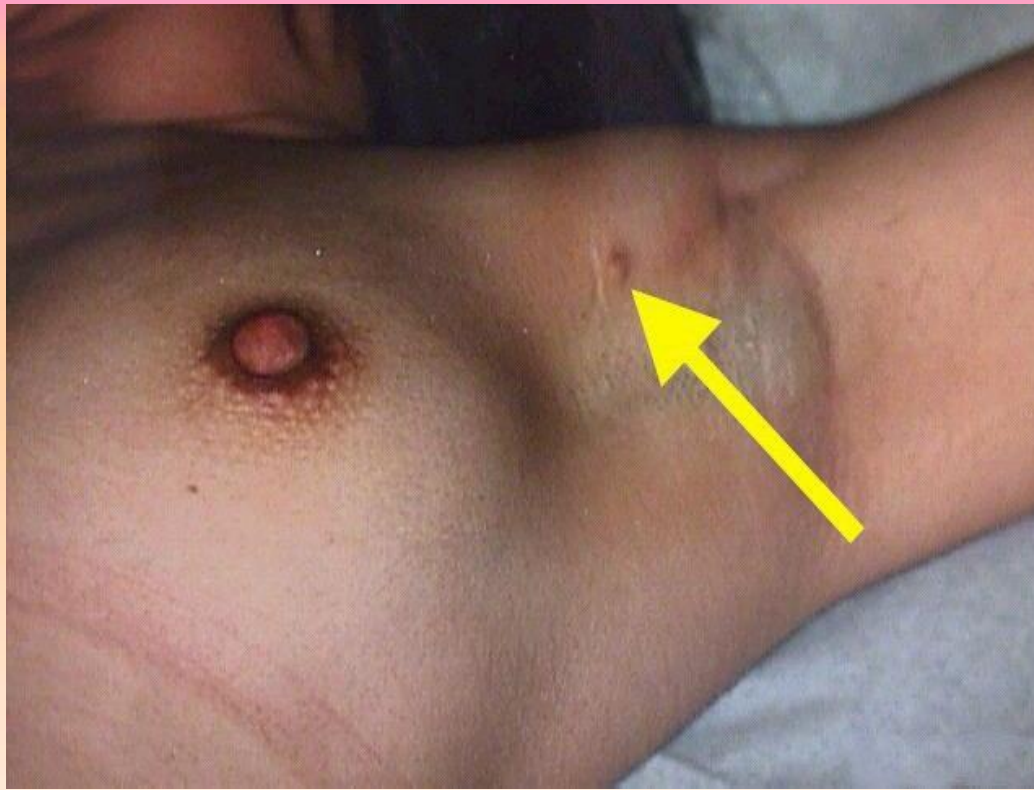
1-Name 3 common causes.

2-What is the “workup” for a breast mass?

30 Y lactating lady with a month history of this painless cystic breast lump following weaning

- 1- What assessment tool seen in the bottom slide?**
- 2- When do you proceed to open biopsy?**
- 3- Is the fluid from a breast cyst sent for cytology?**







- What is the diagnosis?
- 2 DDx?

REMEMBER 6 Ds


Destroyed



Deviated



Displaced



Depressed

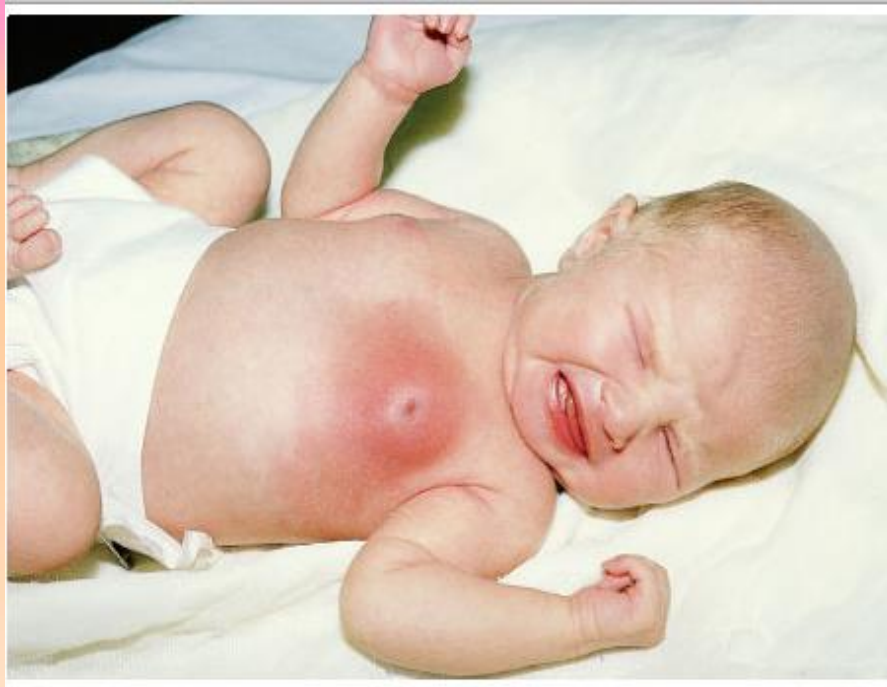

Discoloured



Discharging blood



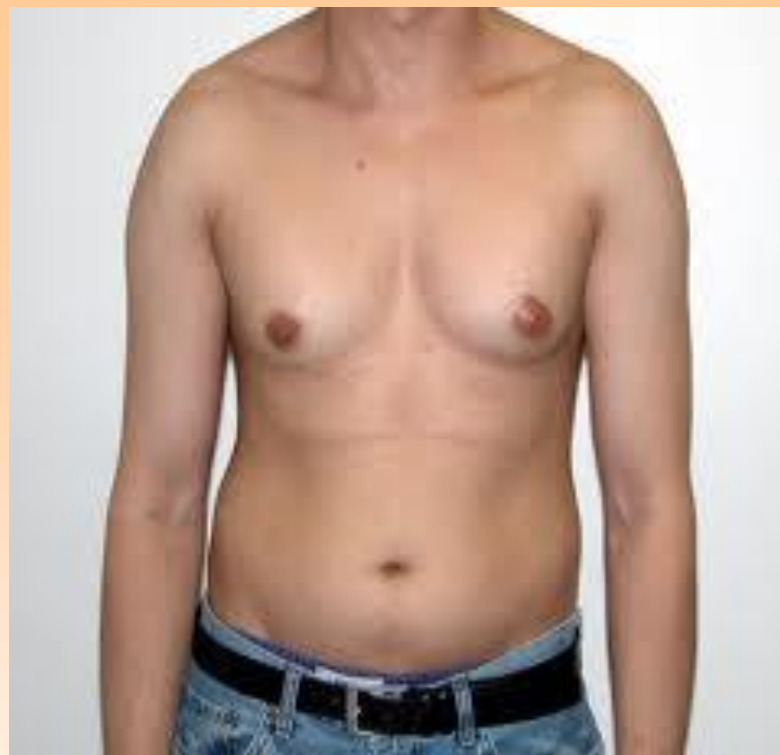

1 week neonate having this breast lesion

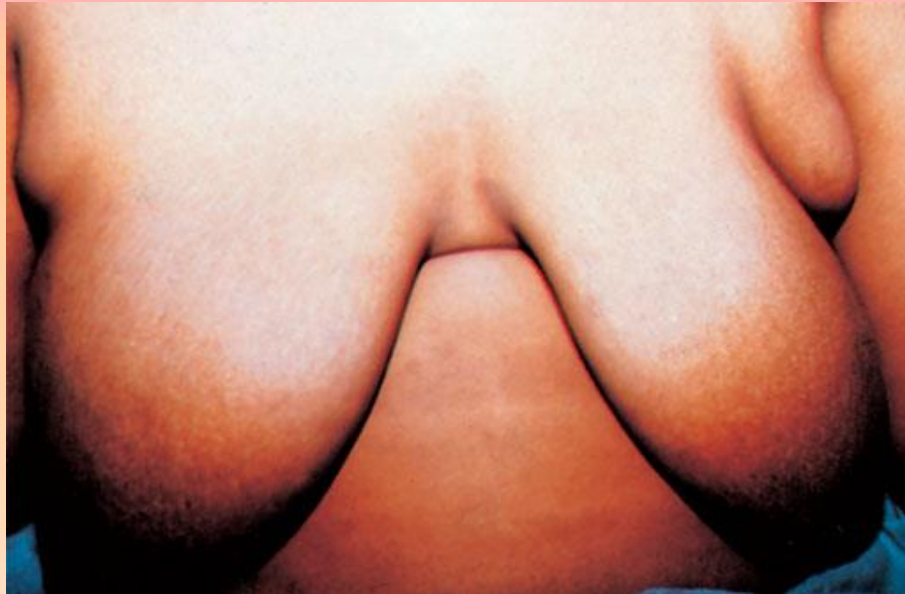1-What is it?

2-Cause?

3-Prognosis?



1. What is this male breast abnormality?
2. What are the commonest ages at which it occurs?
3. How should it be managed?



40 year-old lady with three years history of these bilateral axillary lumps.

- 1. What is this appearance typical of?**
- 2. Other sites of occurrence?**
- 3. Importance of this lesion surgically?**

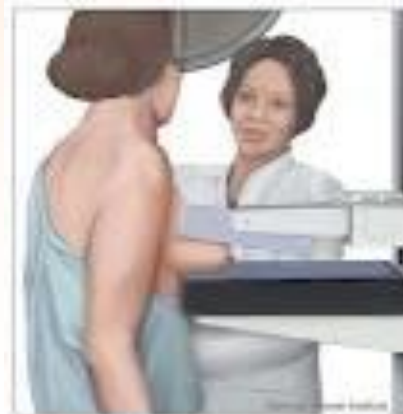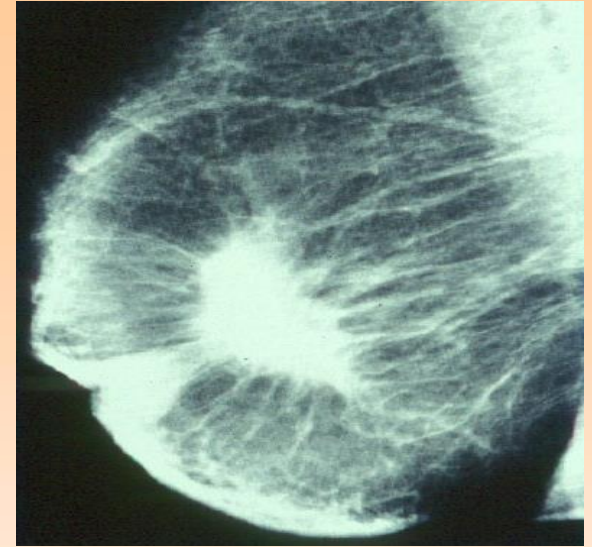Q1- What is this imaging?

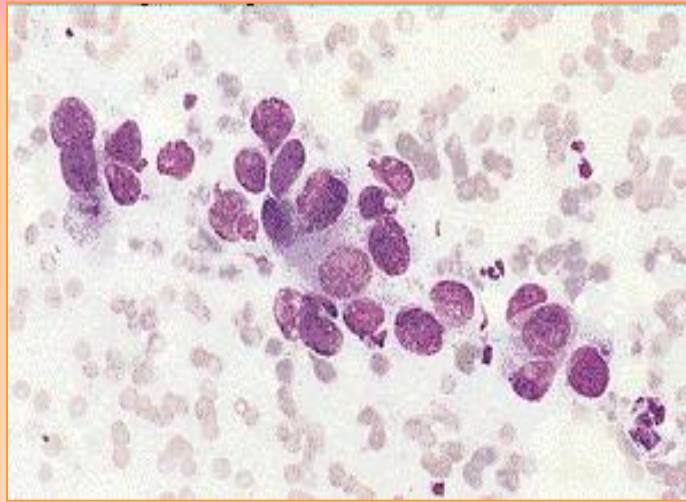
What are the views?

Q2- What is the procedure ?


Q3- What would be suspicious findings?

Q4- Why it is a more useful diagnostic tool in older women than in younger?

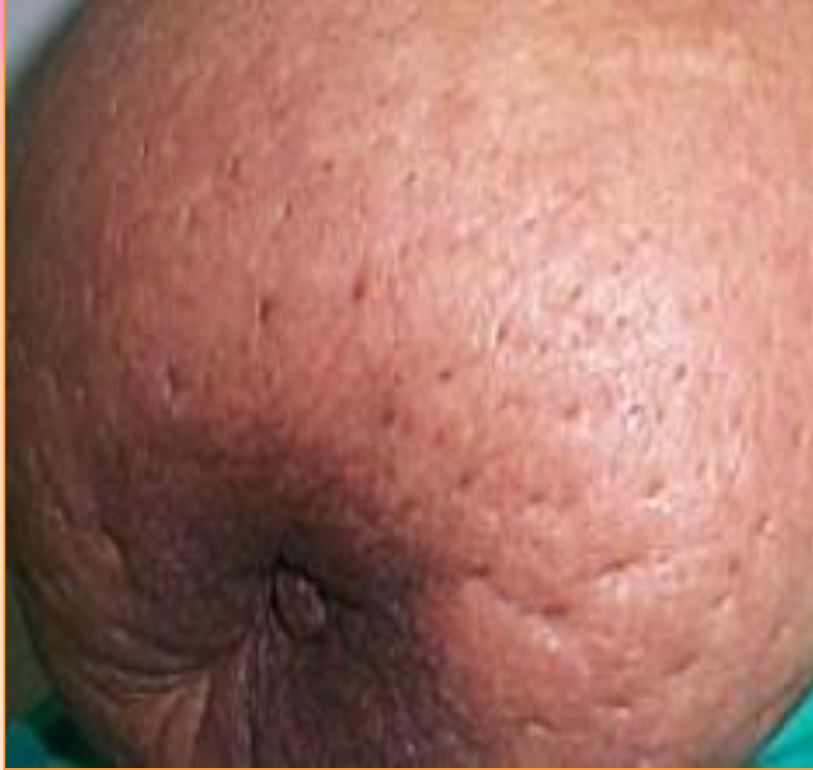



- **This test was done for the previous case . What is it & findings?**
- **Mention its advantages and disadvantage?**
- **What is obtained first, the mammogram or this test?**



- **What is this appliance?**
- **Mention its indication?**
- **Mention advantages and disadvantage?**



- **Define this sign of breast& why does it occur?**
- **What does it signify?**



What are FOUR cardinal local signs of late breast cancer?

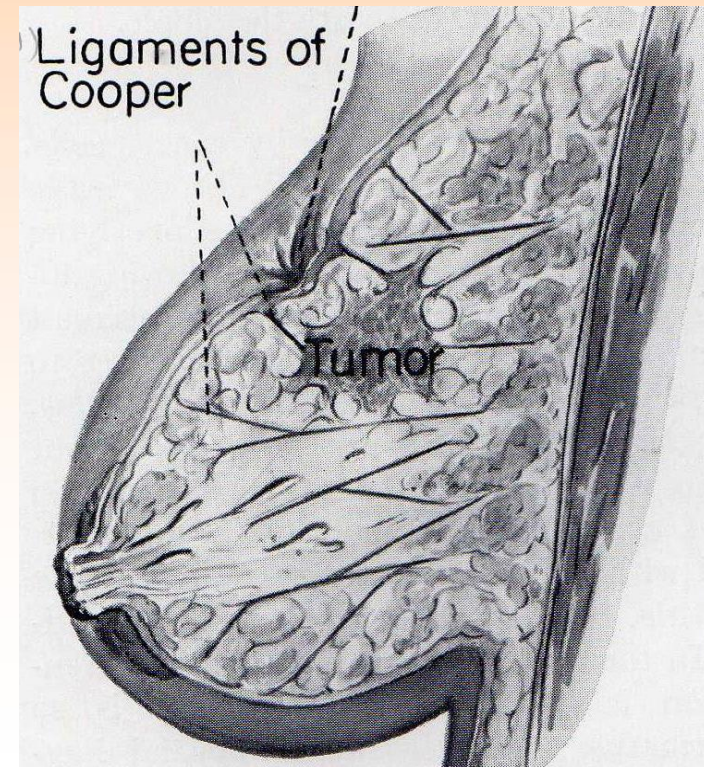
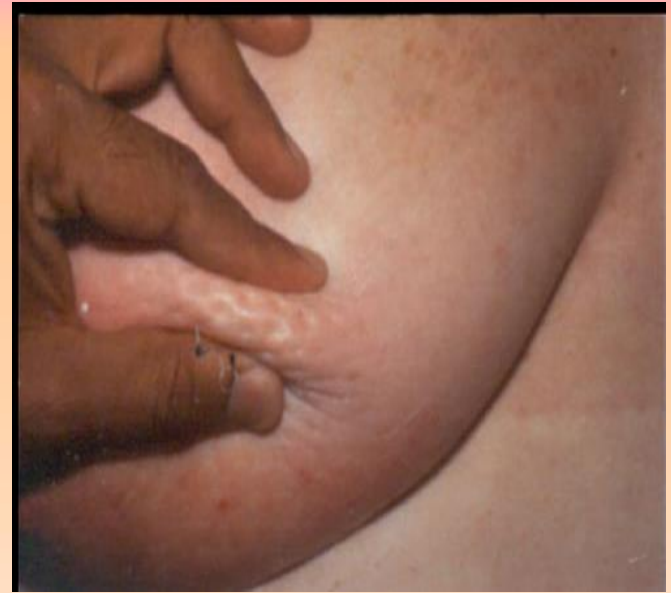What do you mean by tethering to skin ?

Why does it occur ?



Indentation of skin when moving the lump from side to side

Due to infiltration of Cooper's ligaments (suspensory breast ligaments) by tumor.



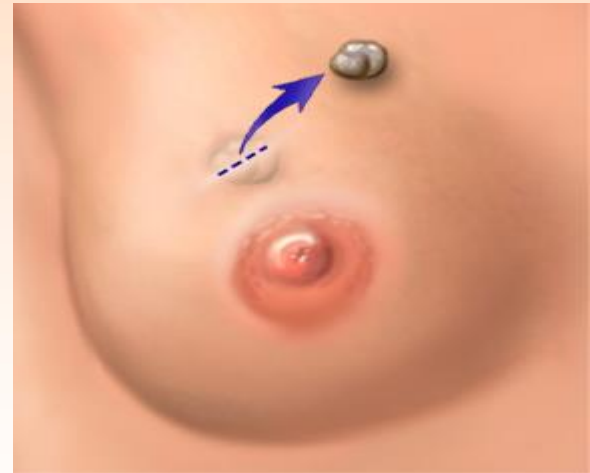

What do you mean by fixation to skin ?

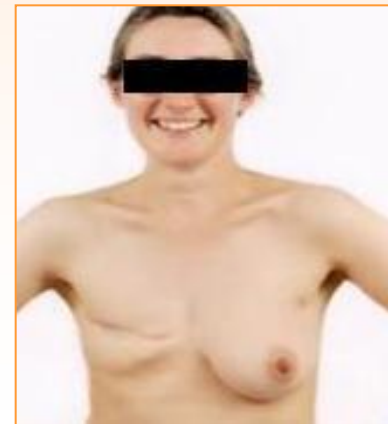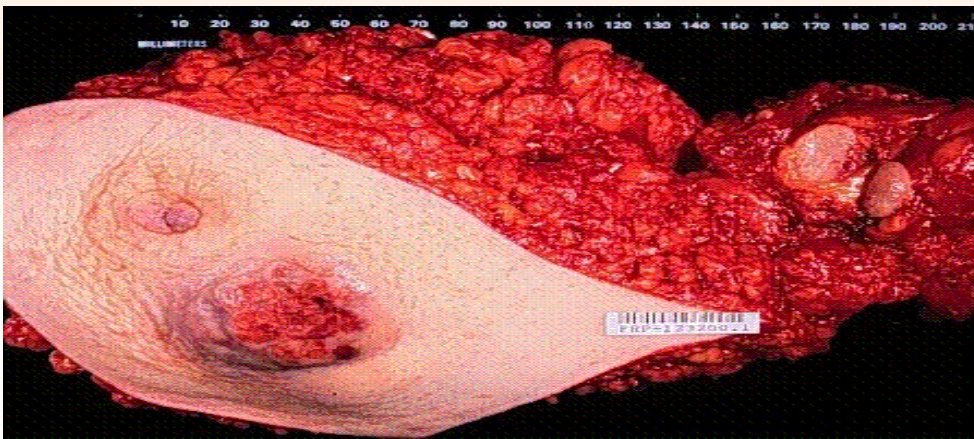
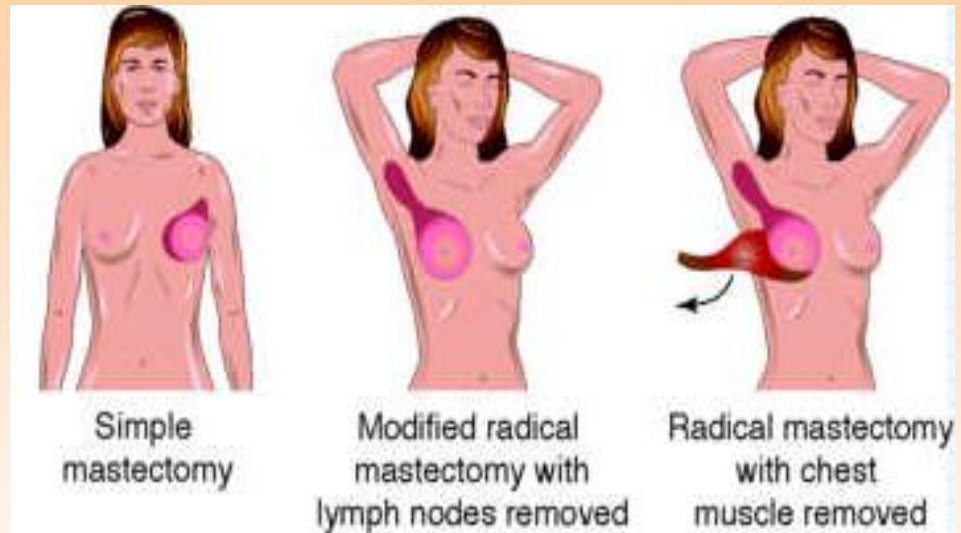
Why does it occur?




**What is the major absolute
contraindication to lumpectomy and
radiation?(BCS)**

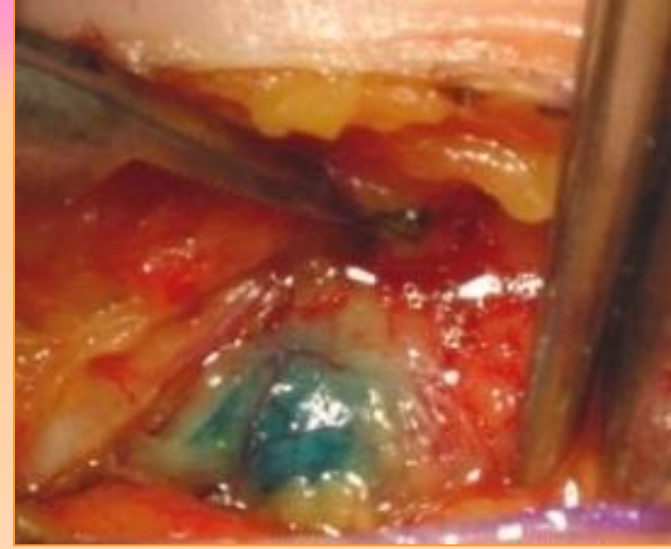


- 1. What is mastectomy?**
- 2. Where are the drains placed with mastectomy?**
- 3-When should the drains be removed?**

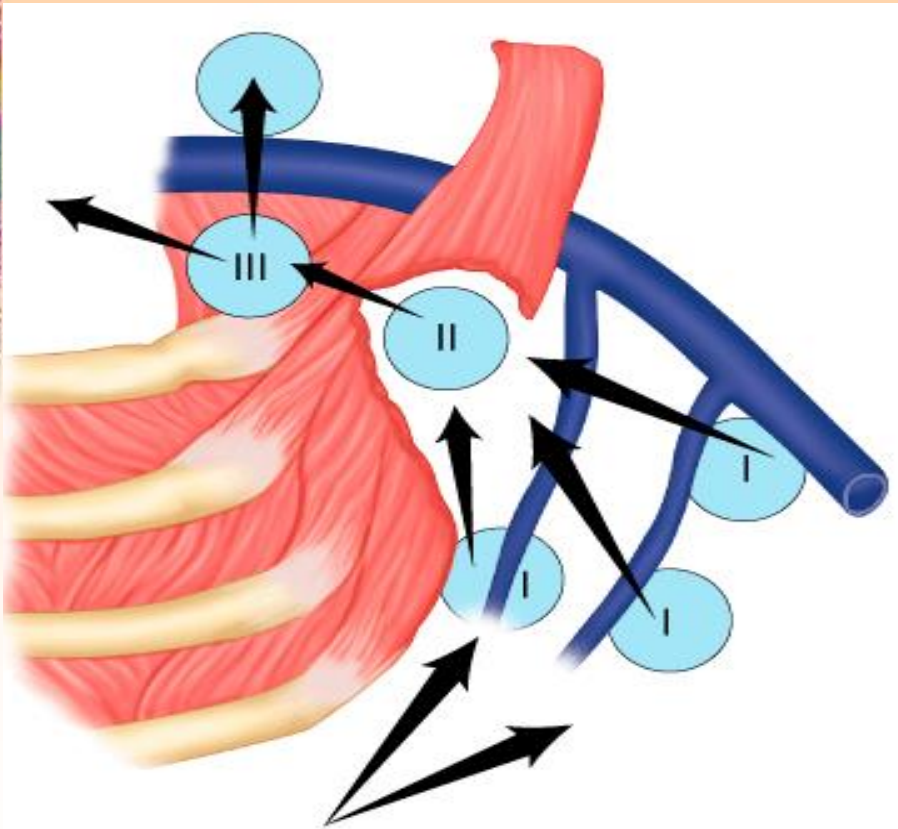


- 
- 1. Why would you manage axillary L.N. involvement by cancer of the breast?**
 - 2. What is now considered standard for lymph node evaluation in women with (stages I and IIA) and clinically negative axillary LN?**
 - 3- Describe the levels of axillary L.N.?**

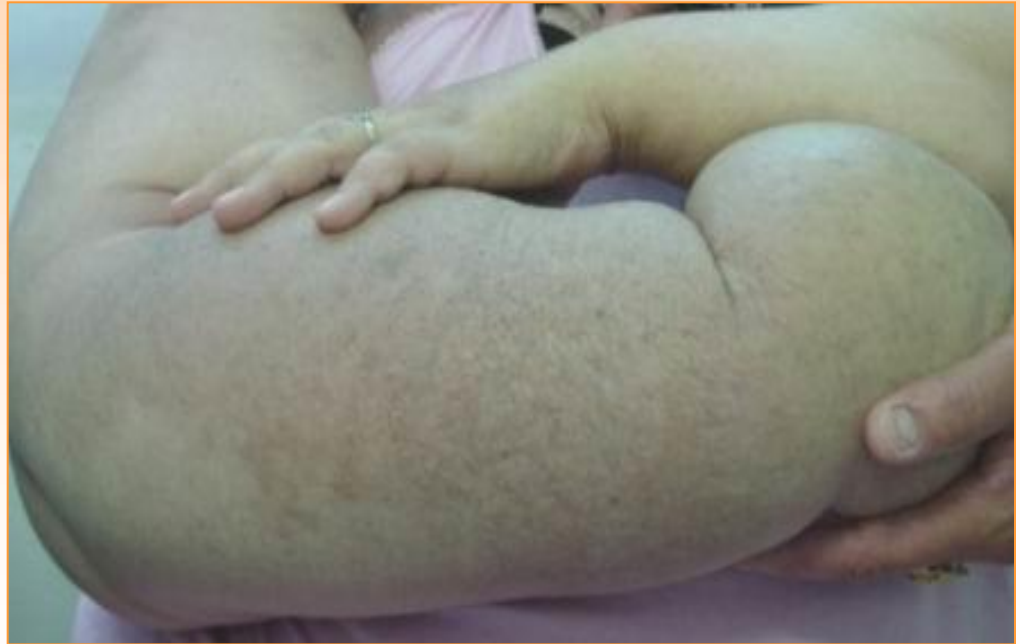



SLNB




- **What is this complication ?**
- **Name four etiological factors?**



Name FOUR nerves must the surgeon be aware of during an axillary dissection & what is the possible injury?





What is the follow up plan after treatment of ca breast?



Thanker
for your
Attention

