

CASE PRESENTATION :OBSTRUCTIVE JAUNDICE IN THE YOUNG

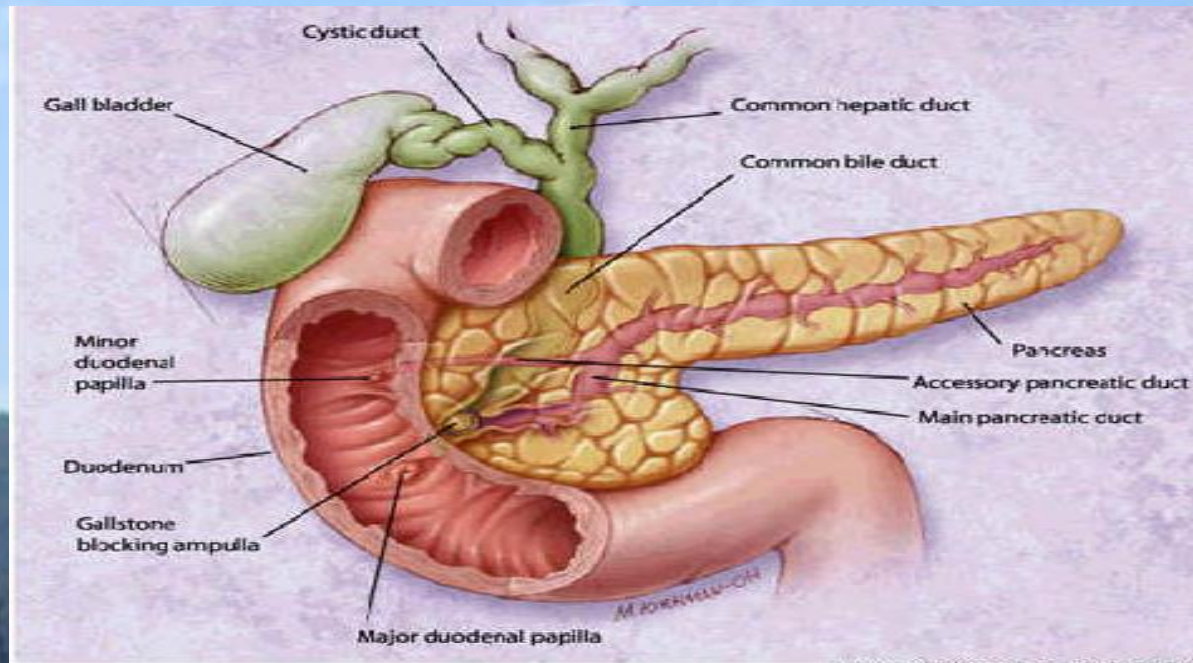
SUPERVISED BY

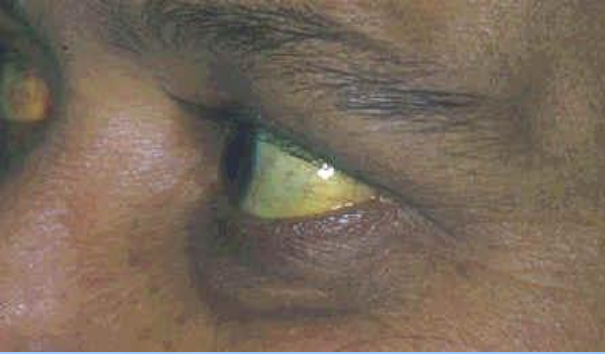Dr. Karam Kamal Younis

Assistant professor and consultant surgeon

Dept Of Surgery in Mosul Medical College

Mosul -IRAQ





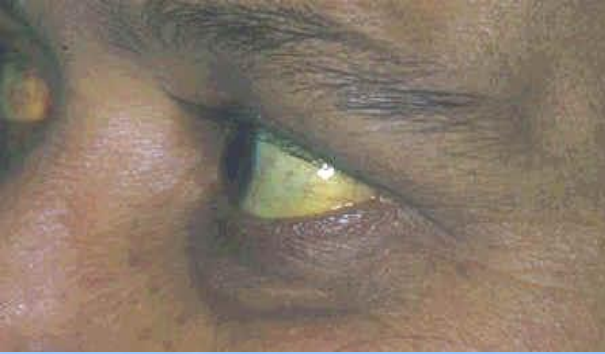The case

- A.M a 19 year- old male student from Kirkuk (Al Hawayja) with 2 months history of severe pain in the epigastrium not related to meal radiating to the back associated with progressive jaundice of 2 weeks duration. He had anorexia and significant weight loss but no fever. No hyperacidity, no hematemesis or melena
- Many times consulted doctors & diagnosed as IBS where he tried many pain remedies and analgesics that did not relieve his pain.



The case (Cont)

- For the last 10 days prior to admission, pain intensified where it interfered with sleeping . Jaundice deepen with tea colored urine and clay colored stool with weakness but no itching.
- Admission to Kirkuk hospital & referral to Mosul Ibn Seena for evaluation.
- Surgical consultation 2 days after admission for his jaundice?.
- **Review of Systems: NOS**



The case (Cont)

- **PMH:** None No bl.transfusions or contact with jaundiced, no hydatid disease, no DM
- **PSH:** None
- **Allergies:** -ve
- **Medications:** None
- **Family History:** Non contributory
- **Social History:** Patient is a student lives with his family not smoker or alcohol drinker. Denied drug abuse. No special pets or animals at home.

Q/What important points in history of jaundice you should ask?

In *Jaundice history remember the mnemonic*

ABCDEFGHI

Alcohol

Blood tranfusion

Contact

Drugs (eg Paracetamol)

Extrahepatic causes

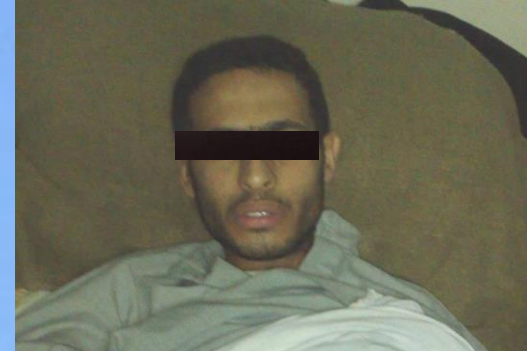Family History, Foreign Travel

Gallstones

Homosexuality

Infections (HBV, EBV, Leptospirosis)

Physical Examination



- **GENERAL**

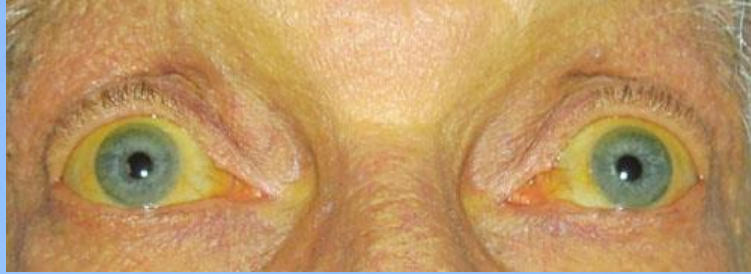- Fully oriented, well developed, but cachectic.
- Uncomfortable due to pain, deeply jaundiced, dry mucous membranes, no palpable supraclav. LNs, no leg edema & no stigmata of ch. liver disease
- Vitals: PR=76b/m, Bp=120/80mmHg, Temp=37.6C & RR=14/m

- **Abdominal O/E**

- Central distension, moves with respiration & Soft.
- A tender, firm, irregular vague & fixed intraperitoneal mass in the epigastrium=7x8 cm.
- Liver and spleen were just palpable, BS normal
- PR empty rectum no mass or blood & good tone

- **Systemic O/E :**

NORMAL



Q/What is the main diagnostic difficulty encountered during evaluation of jaundiced ?

Differentiate medical from surgical jaundice


What are the basic initial evaluation for jaundice?

- ❖ History & Exam.
- ❖ Urine & stool investigation
- ❖ Lab. Test (tsb, sap, cbp, liver enz., pt, s. alb.)
- ❖ 80% diagnostic

Laboratory Data



- **CBP**=Hb of 10.4 g/dl ,WBC count of $21 \times 10^9/l$ with 88% polymorphs, ESR=52mm/h, normal platelets & no retic.
- **Serum bilirubin 167** micromol/l mainly direct
- **Serum alkaline phosphatase =607** IU/I (n = 35-125)
- **transaminases 108/261** U/l (n = 5-40)
- **GUE 1-2** Pus/hpf & **+ve bilirubin**
- **Creatinine 1.1**
- **Glucose 103mg%**
- **Na 138meq%**
- **K 2.8meq%**
- **Cl 95 meq%**
- **BUN 40mg%**
- **TSP=30g**
- **PT/INR=16**
- **Viral screen for hepatitis –ve**



Questions

- 1. Based on the patient's presentation and invx what is the likely diagnosis?**
- 2. What are five causes of this diagnosis?**

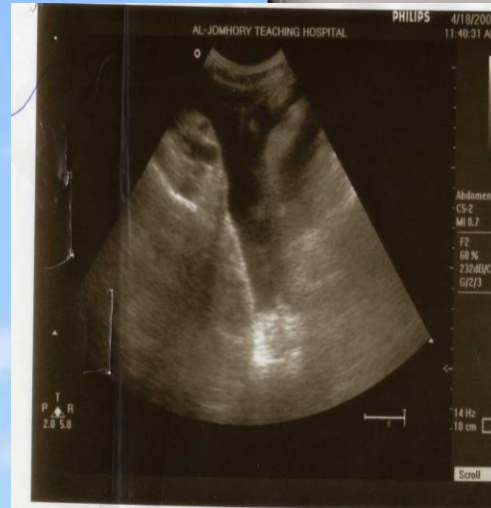
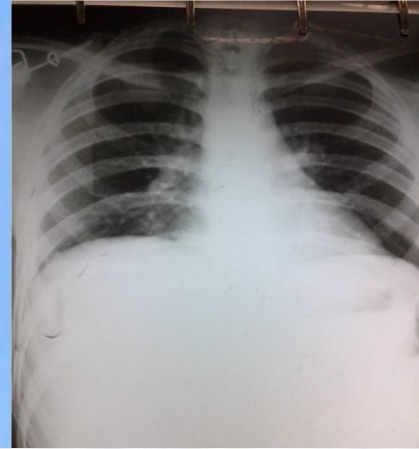
1-This is a classical presentation of obstructive (surgical) jaundice

2- Causes include :

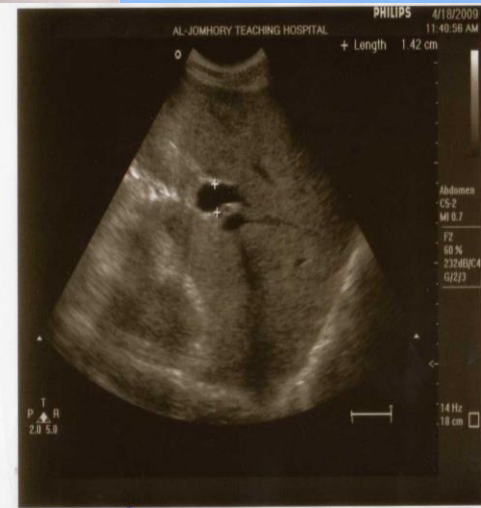1. Hepatitis with cholestasis
2. Biliary stones
3. Hydatid causing pressure on CBD or intrabiliary rupture
4. Pancreatitis
5. Tumors of CBD or head of pancreas

Imaging data

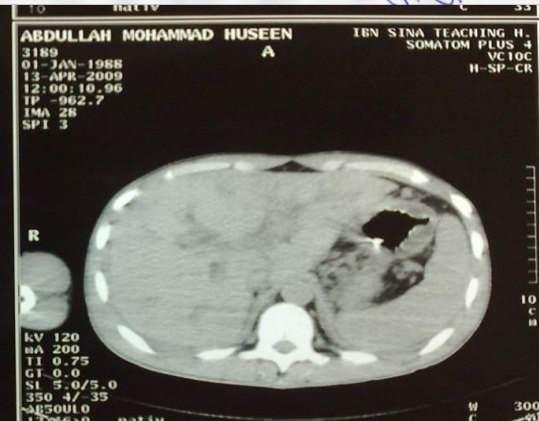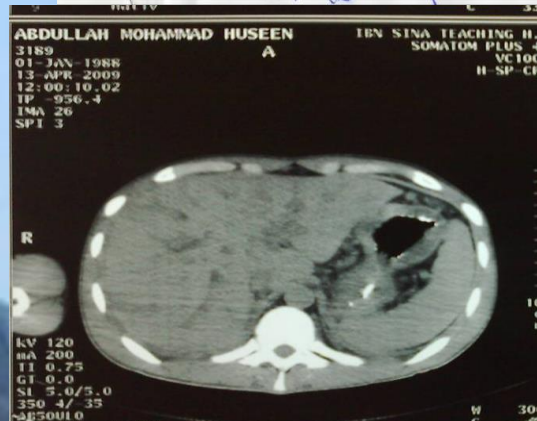- CXR normal
- Ultrasonography and CT scan of the abdomen dilated intrahepatic biliary radicles and a distended GB; the CBD dilated & measured 16 mm + a hypoechoic mass seen in the head of the pancreas. + free fluid pelvis



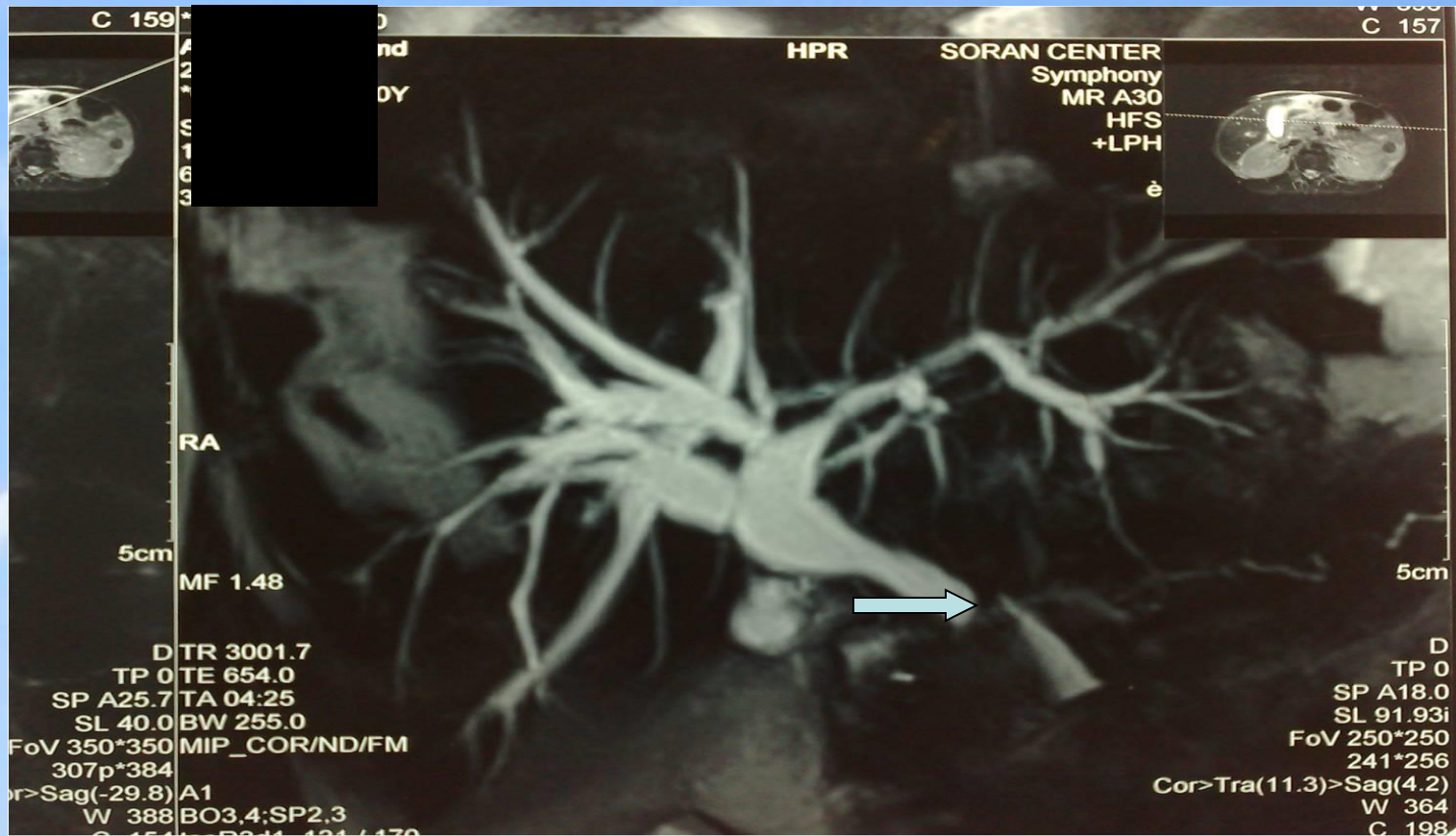Free fluid at pelvis



Dilated C.B.D.



Q/What is the next imaging?



- **MRCP**- to assess biliary dilatation/excludes choledocholithiasis.
- Intra & extrahepatic biliary duct dil. with **abrupt obst.of** CBD of an irregular 'shouldered' short segment a feature of **malig. obst. of distal CBD**

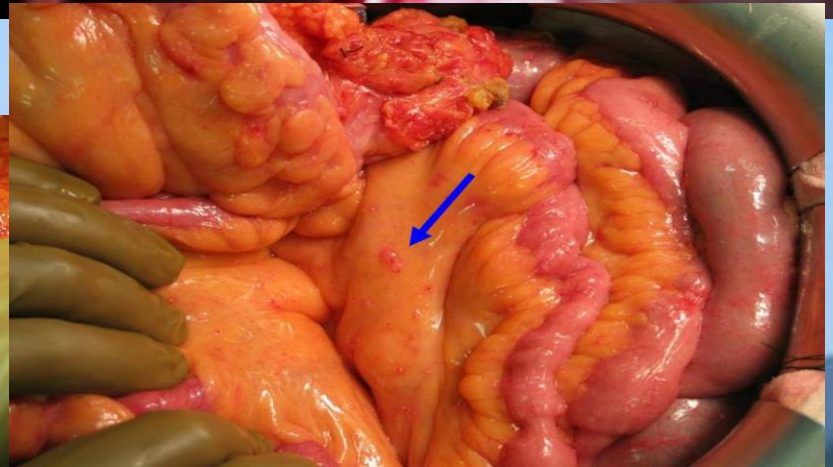
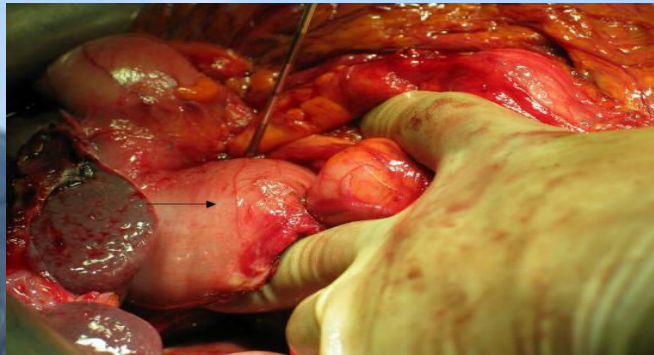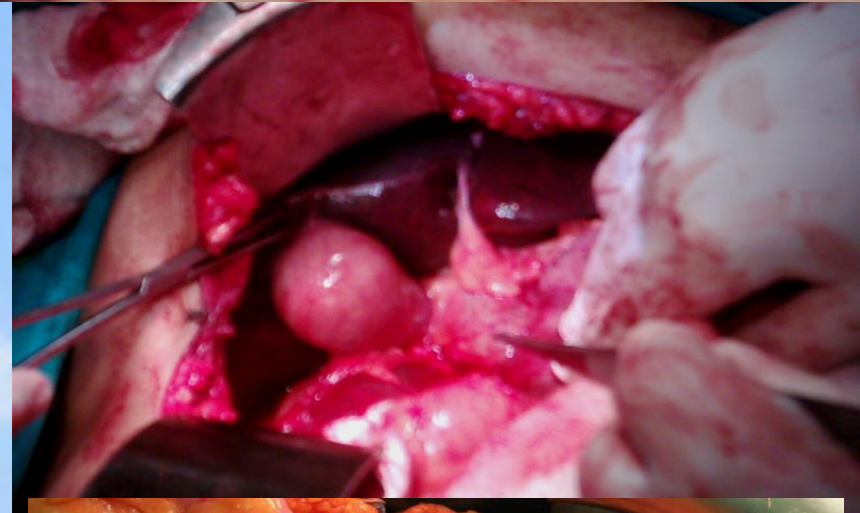
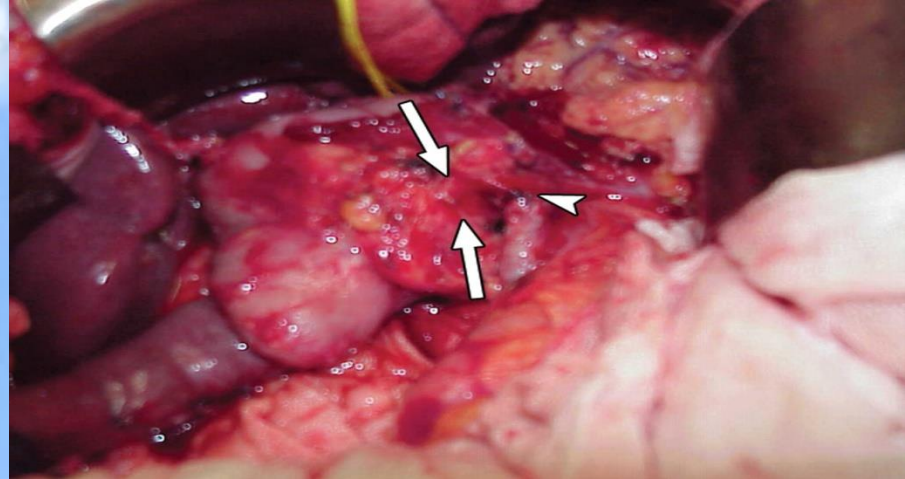
Surgery decided following

Pre operative preparations

- ✓ **Correct dehydration \pm introp. mannitol 500cc of 10% to prevent hepato renal shutdown.**
- ✓ **Antibiotic prophylaxis intravenous 3rd generation CS**
- ✓ **Vitamin k 10 mg intravenously every 24 hours.**
- ✓ **FFP**
- ✓ **High gl.,low fat ,low sodium**
- ✓ **Avoid hepatotoxic drugs**

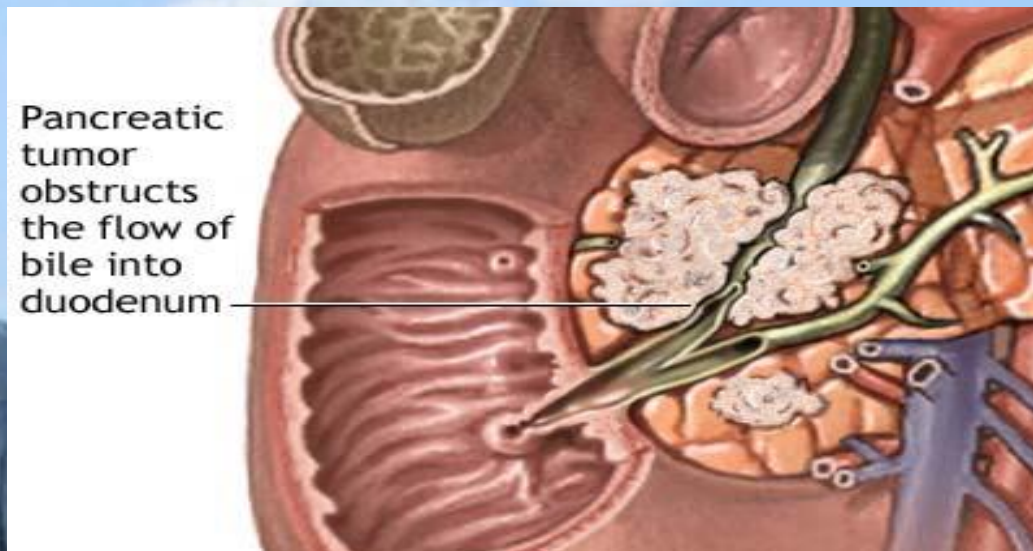
At laparotomy

- Ascites mainly at pelvis with seedling nodules in the peritoneum, omentum, liver & pelvis that all were biopsied.
- 8 x 6 cm hard non resectable mass in the head of pancreas extending across into the neck. Vascular planes posterior and inferior to the pancreas were obliterated, GB distended with thick bile, no stones. **Courvoisier's Sign**
- Cholecystojejunostomy & entero-enterostomy were done.



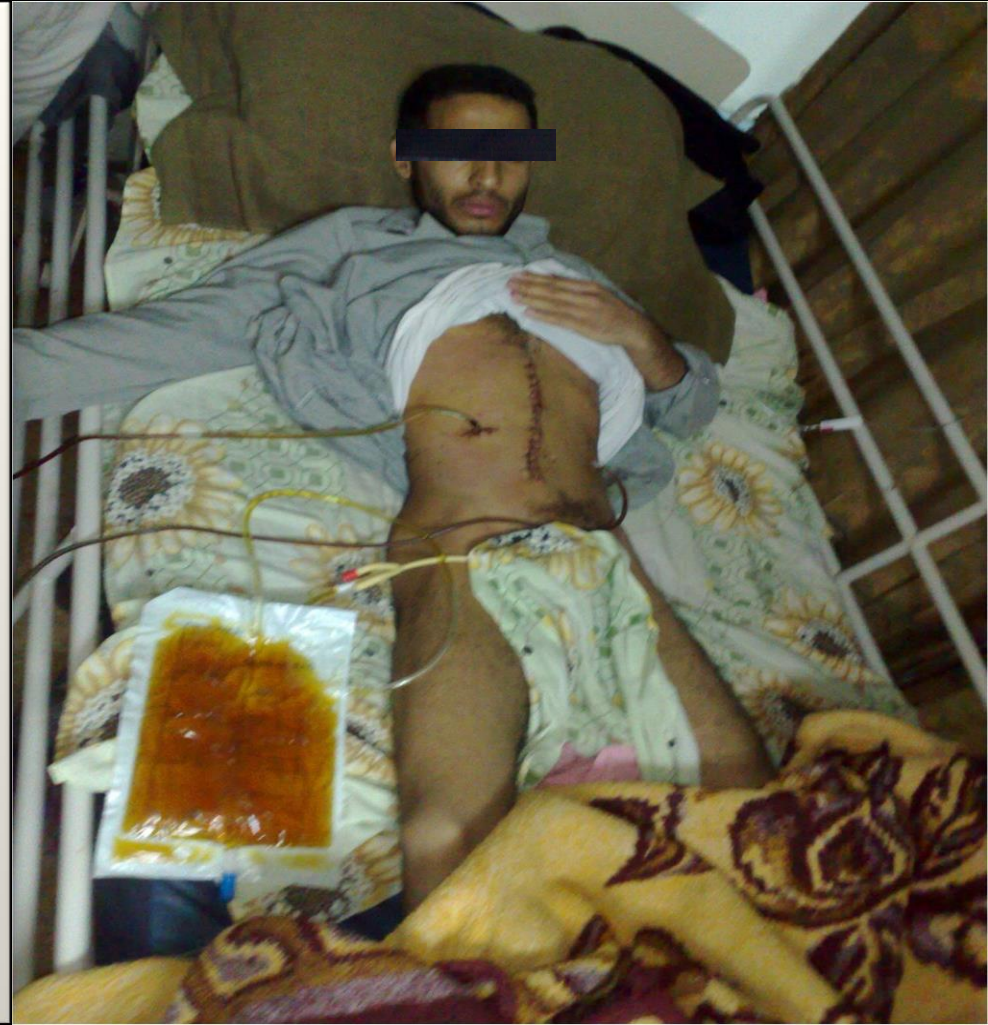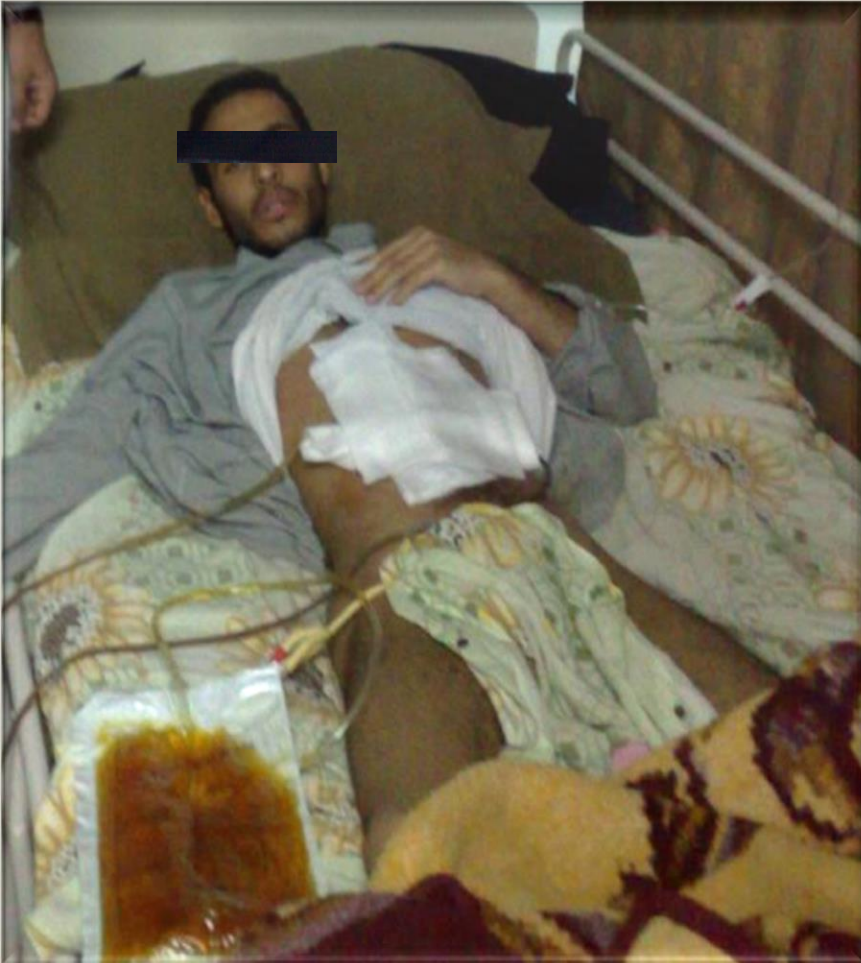Histopathology

- The intraoperative biopsy from seeding implants in the peritoneum & liver revealed a ***poorly differentiated metastatic adenocarcinoma of pancreas.***



Postoperatively

- Jaundice regressed and patient was relatively relieved from pain.



What are the treatment options in this case?

- Potentially curable lesions: pancreaticoduodenectomy (Whipple's procedure).

BUT HERE

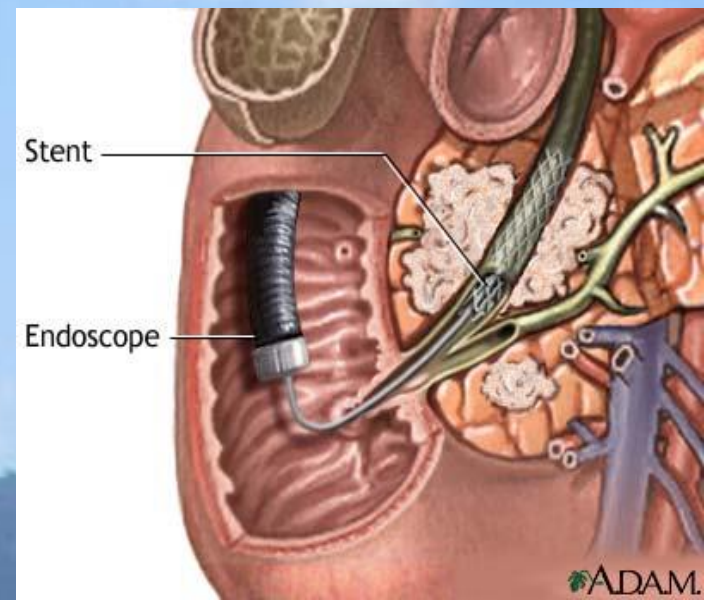
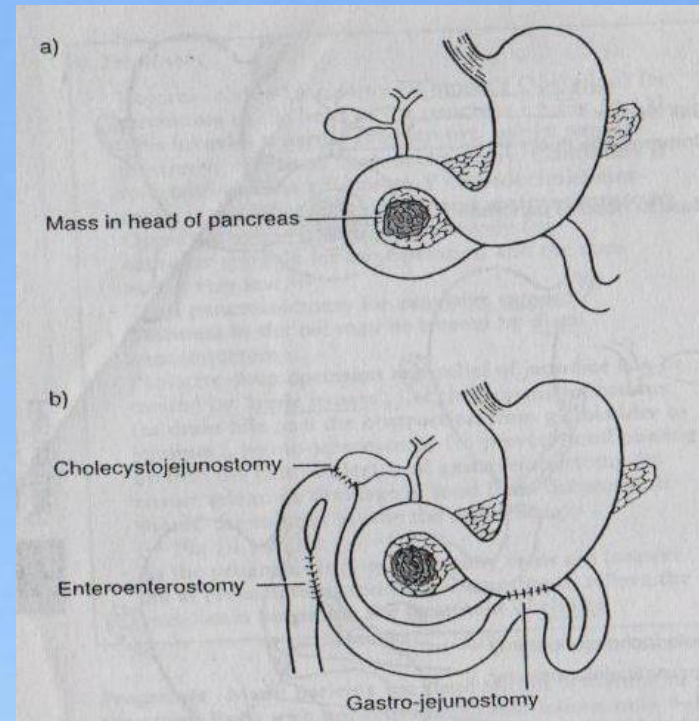
Palliative treatment: in 80–90% :

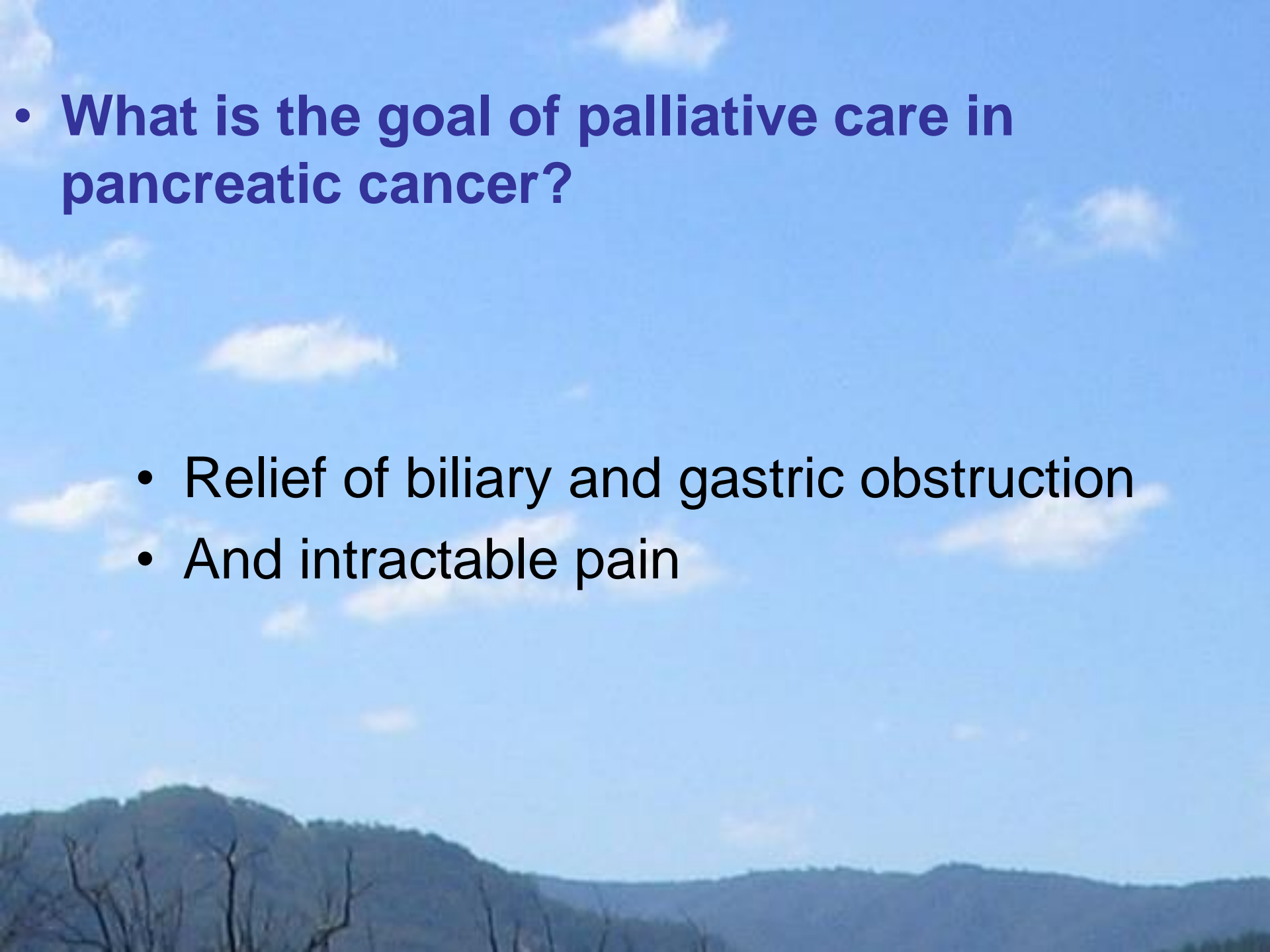
- **Surgery:**
 - ❖ Bilo-enteric +/- gastric bypass Intra-operative
 - ❖ insertion of an internal or intero-external stent. (EndoBiliary Stent)
- **Non-surgical:** intubation (\pm stenting) of the tumour through percutaneous or ERCP.

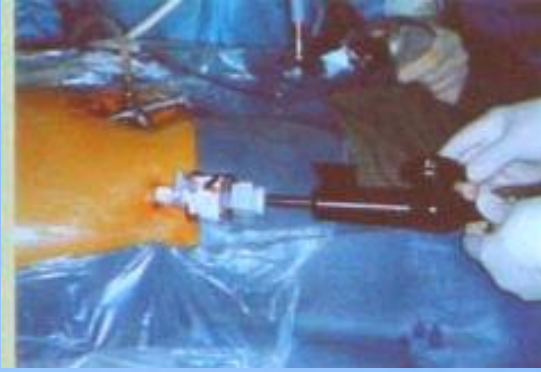Celiac plexus block-

Effective in 90%, and lasts up to 6 months.

Post op . Chemotherapy /- XRT



- 
- **What is the goal of palliative care in pancreatic cancer?**
 - Relief of biliary and gastric obstruction
 - And intractable pain



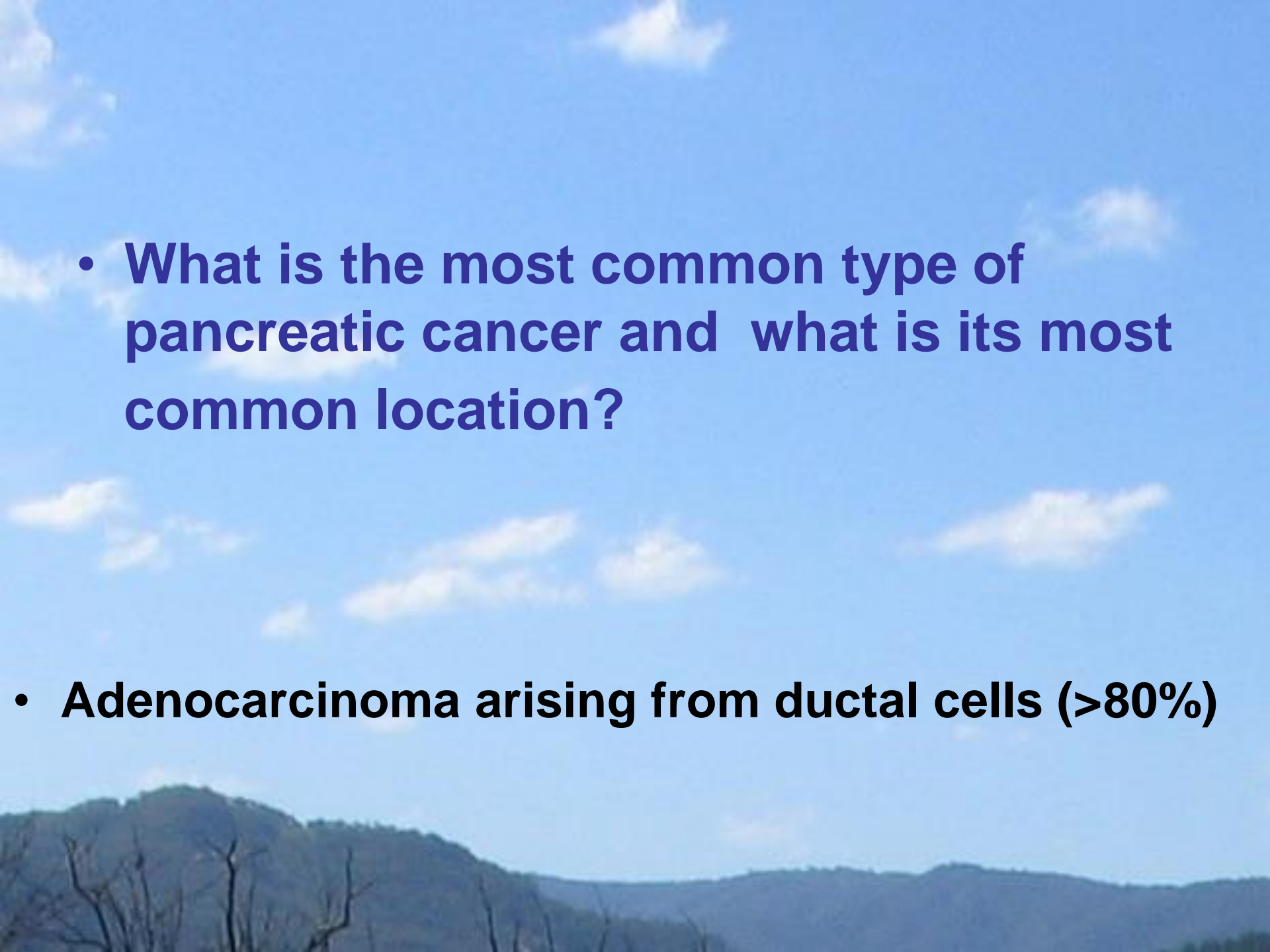
Is there a role for laparoscopy in managing ca head of pancreas?

YES → *Laparoscopy*

- To demonstrate liver and peritoneal mets not seen on CT
- It may prevent unnecessary laparotomy in 10% of pts presumed to have resectable disease
- Therapeutic only in localized, resectable tumors.
- May be more useful in pts with tumors in body and tail

Cancer of the pancreas- a brief review

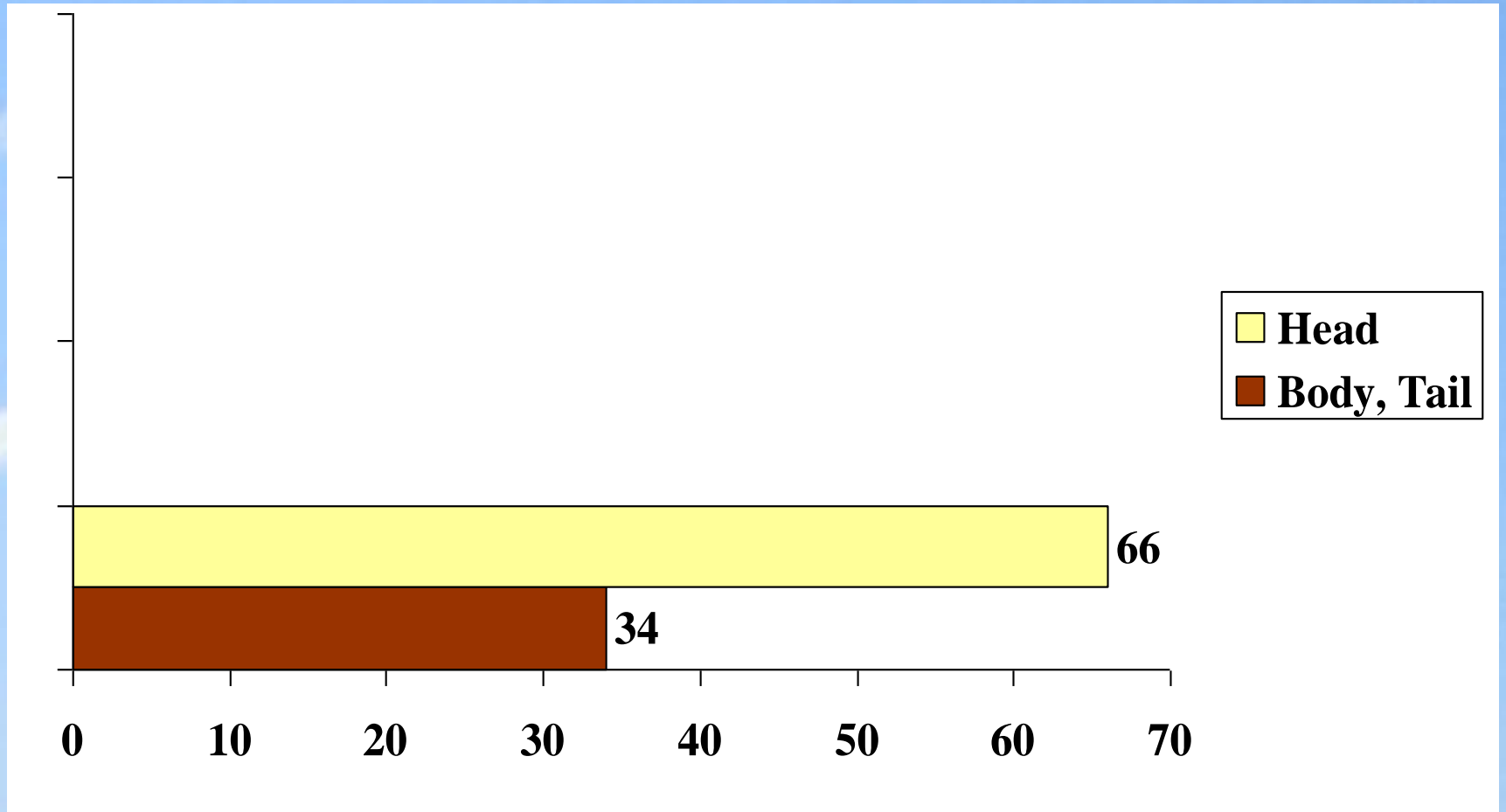
- It is now the **4th most common cancer** causing death (90% of patients die within 1 year of diagnosis)
- Affects men and women 3:2 and it is **rare below 40**
- **80%** occurring **between 60-80 years** of age
- In 1990 a **28year old female** reported as the **youngest case of carcinoma of the pancreas** in the English literature.
- After that in 2011 a **13-year-old boy** reported as the **youngest** reported case with metastatic pancreatic adenocarcinoma.



- **What is the most common type of pancreatic cancer and what is its most common location?**

- **Adenocarcinoma arising from ductal cells (>80%)**

Pancreatic Cancer- Site



What are the most common symptoms of cancer of the pancreatic HEAD?

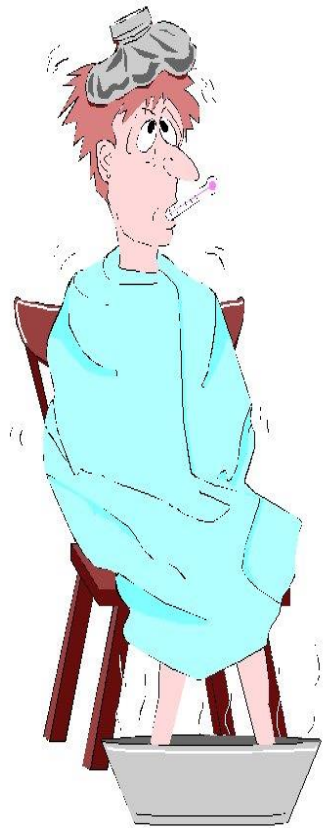- ✓ 1. Weight loss (90%)
- ✓ 2. Pain (75%)
- ✓ 3. Jaundice (70%)

- What are the two most significant risk factors of pancreatic ca?
 - Smoking
 - Increasing age!!

<i>Risk Factors</i>	<i>Relative Risk</i>
Smoking	3x
Alcohol	+/-
Coffee	+/-
High-fat diet (fried meat)	+/-
Increasing age	2
Previous Gastric surgery	+/-
Diabetes	+/-
Ch.Pancreatitis	+/-
Familial Pancreatic Cancer	+/-

- Which tumor marker is associated with pancreatic cancer?

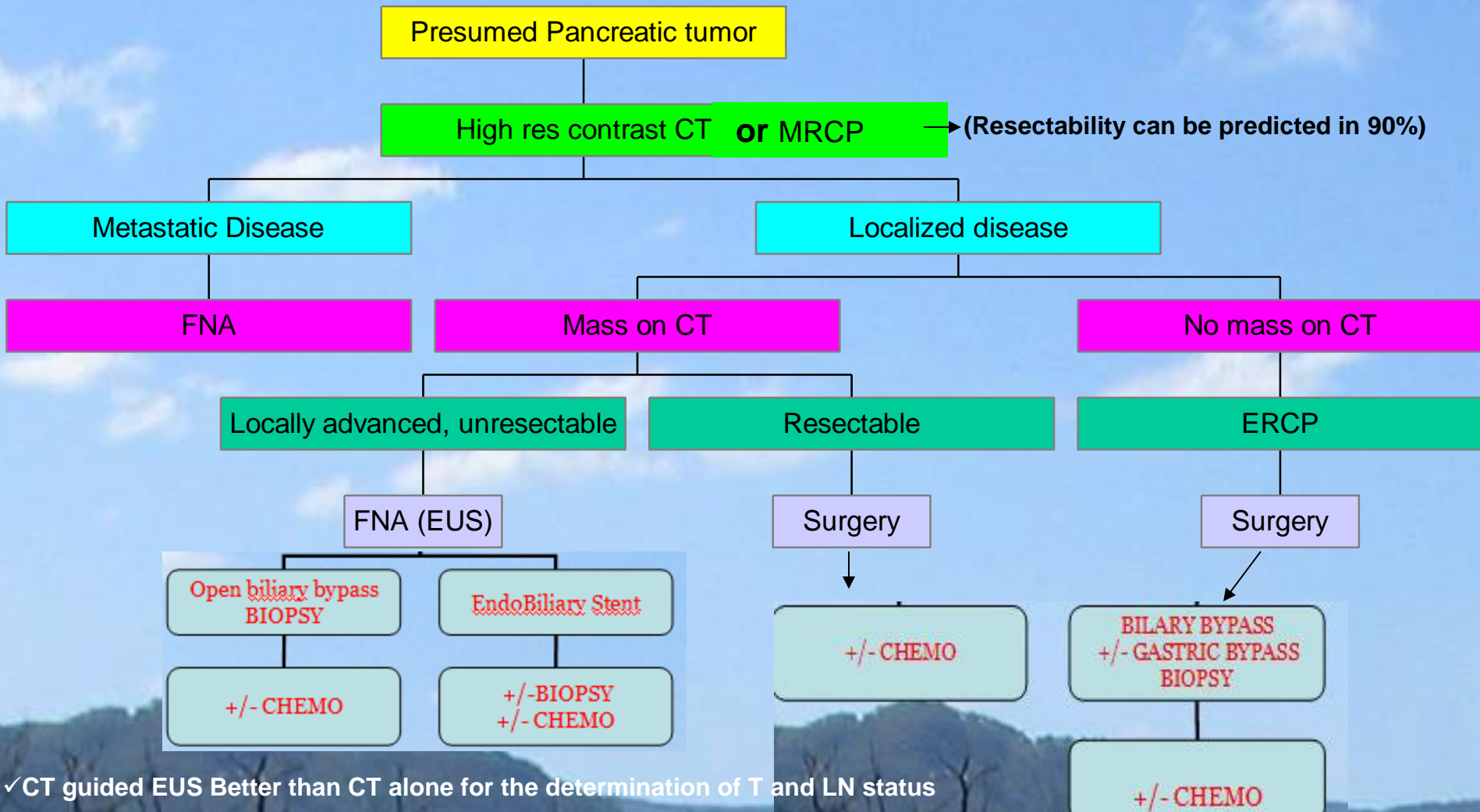
Serum Carbohydrate Antigen 19-9 = 150 a very high tumor marker value ($n < 37$)



✓ THANK
✓ YOU
✓ FOR
✓ YOUR
✓ ATTENTION

Pancreatic Cancer – Diagnostic algorithm

U/S



✓CT guided EUS Better than CT alone for the determination of T and LN status

✓PET scanning=(accuracy 85-93%).