



Lecture title: Types of Nouns

Lecturer Affiliation: *Omar A. Al-Mahmood, Ph.D. Department of Public Health College of Veterinary Medicine, University of Mosul, Mosul, Iraq*

<https://orcid.org/0000-0003-2065-6165>

<https://www.researchgate.net/profile/Omar-Al-Mahmood>

Summary:

Terms Used to describe Direction and Position:

- 1- **Ventral:** refers to belly or underside of body.
- 2- **Dorsal:** refers to back of body.
- 3- **Cranial:** near or toward the head.
- 4- **Caudal:** near or toward the tail.
- 5- **Anterior:** means front of the organ, used with organ or body part.
- 6- **Posterior:** means rear or behind of the organ. Used with organs.
- 7- **Rostral:** means the nose end of the head.
- 8- **Medial:** toward the midline of body.
- 9- **Lateral:** means away from the midline of body.
- 10- **Superior:** means uppermost or above other parts.
- 11- **Inferior:** means lowermost or below other parts.
- 12- **Proximal:** means nearest to the beginning of a structure or organ.
- 13- **Distal:** means farthest to the beginning of a structure or organ.
- 14- **Superficial:** means near or on the surface (also used external).
- 15- **Deep:** means away from the surface (also used internal).

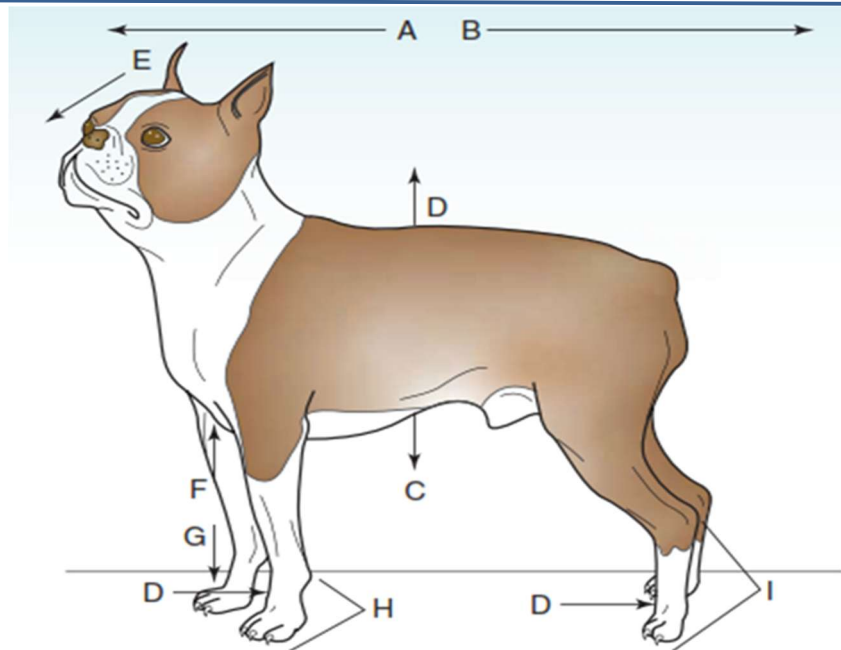
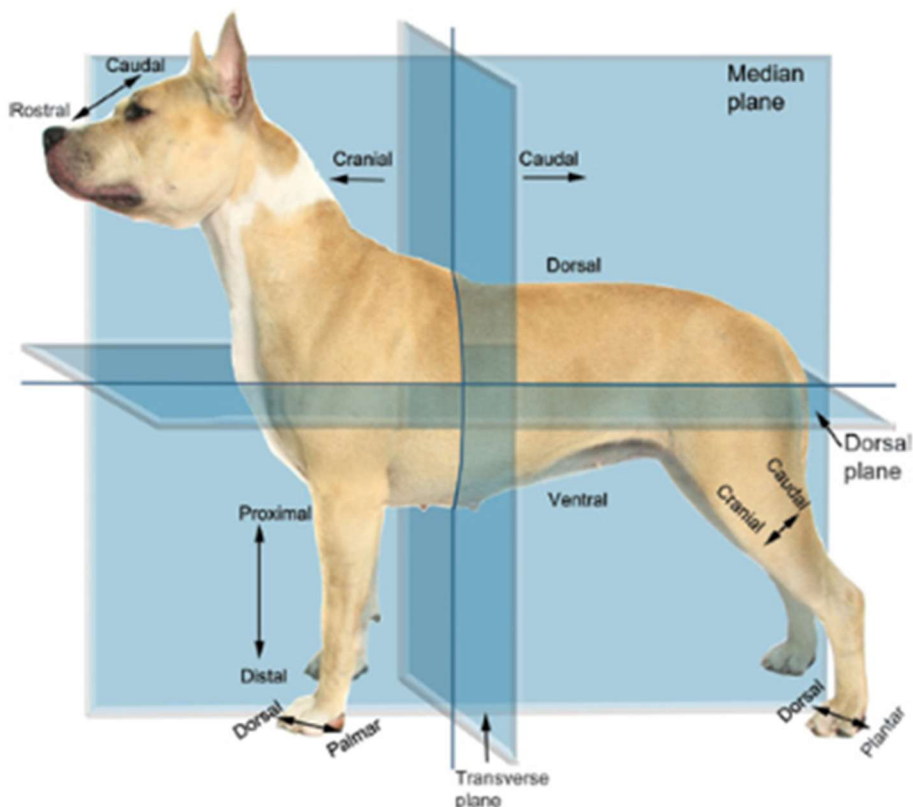


Figure 2-1 Directional and surface terms. The arrows on this Boston terrier represent the following directional terms: A = cranial, B = caudal, C = ventral, D = dorsal, E = rostral, F = proximal, G = distal, H = palmer, I = plantar.





Two: Terms Used to describe Body Planes:

Planes are imaginary lines that are used to divide the body into section to facilitate the describe body locations.

1- Midsagittal Plane: is the plane that divides body into equal left and right halves. It's called also median plane because its cross into midline of body.

2- Sagittal Plane: that plane divides body into two unequal left and right halves.

3- Dorsal Plane: that plane divides body into dorsal and ventral parts. It's also called frontal plane or coronal plane.

4- Transverse Plane: that plane divides body into cranial and caudal parts. It's also called horizontal plane.

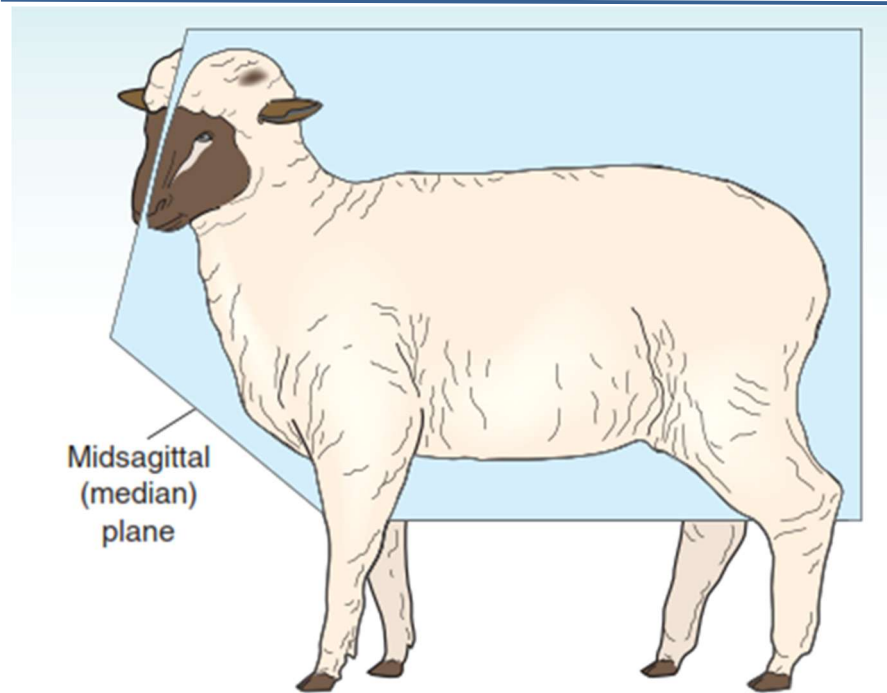


Figure 2-3 Planes of the body. The midsagittal, or median, plane divides the body into *equal* left and right portions.