



---

**Lecture title: *Pet bird diseases***

**Lecturer Affiliation:**

**Summary:**

***Pet bird diseases***

**Psittacine beak and feather disease**

This common disease is caused by a circovirus that occurs in wild Australian cockatoos but is known to be able to infect nearly all species of Psittaciformes. Transmission occurs by inhalation and/or ingestion of the virus and can occur vertically. The virus is very stable in the environment. The bird becomes unwell, and the virus affects rapidly growing cells and will cause feather loss by preventing further feather growth in the fledging birds. The feathers lose their blood supply

**an acute form,**

which occurs predominantly in nestlings and juvenile Grey parrots (*Psittacus erithacus*) and is characterized by the rapid onset of leucopenia and liver necrosis that result in the development of secondary infections and general malaise; birds often die within a week after onset of the clinical signs, without obvious feather lesions present

**a chronic form**

which usually becomes apparent when the bird goes through its first moult and the normal feathers are replaced by dystrophic feathers giving rise to progressive and often bilateral symmetrical feather, claw and beak deformities.

Feather abnormalities commonly seen in PBFD-affected birds generally comprise of one or more of the following: thickened and/or retained feather sheath; haemorrhage

within the shaft or pulp cavity; stunting or clubbing of feathers; stress lines across the vanes; annular

constrictions of the calamus; curling of the feathers and feather necrosis of both contour and down feathers

In the later stages, feather development is hampered until eventually all feather growth ceases and the bird becomes progressively bald. In addition to feather changes, beak and claw abnormalities (e.g. overgrowth, malformation, necrosis, fractures and fissures)

The clinical course of the chronic form of the disease may run from months to years until the birds eventually succumb to secondary infections. A presumptive diagnosis can usually be made based on

the distinct clinical features of the disease. **There is no treatment for PBFD and affected birds may be euthanized once the disease progresses. Although experimental inactivated vaccines are available**



Acute PBFD in young Grey parrots (*Psittacus*

*erithacus erithacus*). Feather abnormalities may be generalized, but affected birds, especially young Grey parrots, may also die prior to developing the characteristic feather lesions, as a result of immunosuppression and secondary infections.

### Polyomavirus

This is a widespread infection in Psittaciformes, but was first called **budgerigar fledgling disease** (BFD). Budgerigars have BFDV-1, the rest of the parrots BFDV-3 (polyomavirus will also affect finches). **Budgerigar chicks can die in the first few weeks of life – either suddenly, or with abdominal distension, subcutaneous hemorrhages and ataxia. Some cases are more chronic and develop dystrophic primary and secondary wing feathers and tail feathers but do not die**

These cases resemble PBFD. Other species of psittacine birds, when affected by polyomavirus, can be very ill at weaning with non-specific weight loss, anorexia, partial paralysis of the gut, polyuria and watery droppings

**This form of the disease, also termed 'French moult' follows a relatively typical pattern:**

budgerigars less than 2 weeks of age show a lack of powder down on the head and neck; those of 2 to 4 weeks of age show a lack of or incompletely developed flight feathers; and those older than 25 days of age will develop



Diagnosis using a PCR test can be made using cloacal swabs or tissues from post-mortem examination. A vaccine has become available in the USA. Polyomavirus infection in a budgerigar (*Melopsittacus undulatus*), resulting in a condition called 'French moult'. The primary flight feathers often do not develop in affected juveniles, essentially rendering them flightless. This is why such birds are often called 'runners' or 'creepers'.

### Herpesvirus

This is the cause of **Pacheco's parrot disease**: a sudden-onset, usually overwhelming, hepatitis. Many birds that are ill will die. Some that recover and some that are subclinically infected will become lifelong symptom-free carriers. In stressed or low-grade unwell birds e.g. imported birds in quarantine, the morbidity and mortality are high. In healthy birds that are well fed the morbidity seems to be much lower, but mortality is the same. Post-mortem signs include a very enlarged liver and some enlargement and darkening of spleen and kidneys. Histopathology reveals intranuclear inclusion bodies, and it is possible to isolate the virus. Treatment with acyclovir may work, but it is not known how this affects the carrier status of recovered birds. Vaccination with a dead vaccine is available in the USA, but not legally obtainable in Europe.

### Avian influenza

Influenza viruses come in three groups; B and C affect humans and rarely birds; influenza type A affects birds and rarely humans. Avian influenza has affected parrots causing anything from no illness to sudden death; or death after depression, diarrhea and neurological signs. However this is a virus that is rarely seen in parrots and most psittacine infections have occurred either in quarantine stations where it was caught from other birds in the quarantine station, or it has been caused experimentally. Avian influenza virus varies considerably in its pathogenicity, and the serotypes that affect poultry are not usually a great risk to parrots and vice versa.

### Paramyxovirus

Newcastle disease (PMV-1) and several other paramyxovirus strains have caused disease in Psittaciformes. The signs can be per acute death; respiratory disease or gastrointestinal disease or a combination of both; chronic central nervous system disease (sudden onset and incurable opisthotonos, torticollis, tremors or paralysis). It is an uncommon disease in parrots, and is not seen in single pet birds. The disease is diagnosed on virus isolation from the trachea, lung and brain. This range of viruses will cross the species barrier very readily and is highly contagious.

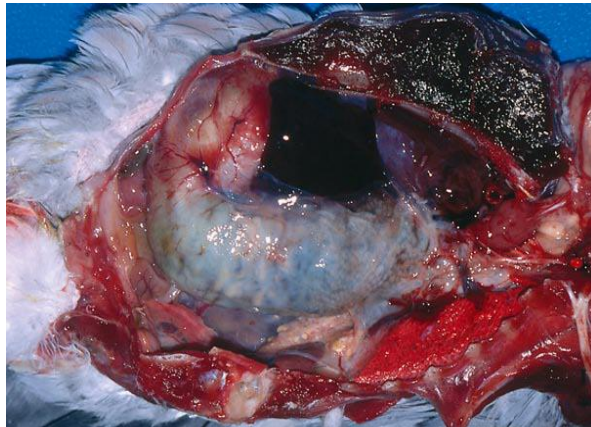
### Proventricular dilatation disease

Larger parrots, such as grey parrots, macaws and cockatoos, may be presented with signs of weight



loss and regurgitation or weight loss and the passage of whole seeds . many birds will appear to be hungry and make pathetic begging-for-food noises. Most of these cases have proventricular dilatation disease (PDD). Diagnosis in the live bird is aided by radiography. Lateral and ventrodorsal views often show a dilated proventriculus and gizzard, Confirmation of the diagnosis in a live bird may be obtained in many cases from histopathology on a biopsy of the crop; this is relatively easy to perform.

Post-mortem examination can be used to confirm the diagnosis in most outbreaks of this disease, as there is a high mortality rate. The crop, proventriculus and gizzard can be variously thin-walled, dilated and impacted with seed Treatment of this disease is possible, and some individuals recover. Treatment is empirical: a high fiber, moist diet, with little seed; broad-spectrum antibiotics to prevent peritonitis and pneumonia (trimethoprim/sulphonamide) enlarged proventriculus distended by whole seeds. The seed can be seen filling the proventriculus and gizzard as well as filling the oesophagus and crop

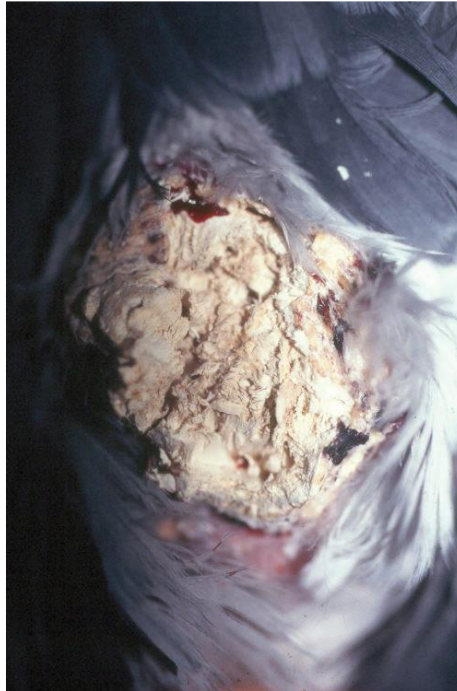

### Folliculitis

Folliculitis (inflammation of the feather follicles) is a condition that may develop due to (secondary) bacterial and/or fungal pathogens. Pathogens that have been implicated in folliculitis include Staphylococcus spp., Aeromonas spp., Mycobacterium spp., Aspergillus spp. and Malassezia spp.

Grossly, the lesions are characterized by presence of perifollicular swelling and erythema, but hyperkeratosis, crust formation and discolouration of the feathers have also been noted when fungal organisms are involved ,In case of bacterial folliculitis, treatment is preferably based on the results of the sensitivity test; in case of fungal folliculitis, antimycotic drugs such as itraconazole, fluconazole, clotrimazole and terbinafine may be used. Prolonged treatment periods of >3 weeks are often needed to effectively eliminate the infection.. Fungal dermatitis due to Aspergillus spp. In a Grey parrot (Psittacus erithacus erithacus). Note the hyperkeratosis and crust formation of the skin.





### **PTFE poisoning**

**Polytetrafluoroethane (PTFE)** poisoning from over-heated non-stick Teflon®-coated cooking utensils is a common cause of severe, rapid, terminal pneumonia. Over-heating is not difficult if the pan is empty, and it causes the coating to depolymerize to form a lethal vapour; birds in the same air-space will drop off their perches, dead, within half an hour of inhaling the vapour. Some self-cleaning ovens and some spotlight bulbs are also coated with Teflon®. Examination of the lungs at post-mortem shows edematous bloody tissue throughout both lungs. Over-heated, smoking cooking oil can have a similar effect, as will bonfire or barbecue smoke.

### **Zinc**

'New wire disease' is sometimes seen in birds that are placed in newly meshed aviaries, and zinc toxicity may be suspected in birds that become chronically unwell in new cages. The diagnosis may be confirmed on blood samples, The source of zinc is either the white powdery coating found on the new wire (known as white rust), Zinc does not remain in the body and is quickly removed once ingestion has stopped; there is no evidence that EDTA treatment is useful. Lumps of metal in the gizzard should be removed by endoscopic retrieval, by flushing the gizzard under anaesthetic, or by surgical exploration of the gizzard through an incision in the proventriculus

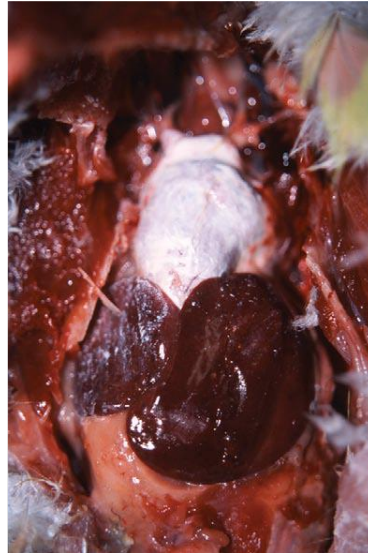
### **Visceral and articular gout**

These syndromes are commonly seen in parrots. The birds are often unwell, and pasty white uric acid deposits may be visible under the scaly skin of the legs and feet . The uric acid will also be deposited around the viscera in the various peritoneal cavities (hepatic, pericardial, etc.) Affected birds seldom recover. Allopurinol has been suggested as a treatment because it works in humans (a 100 mg tablet crushed in 10 mL of water; 1 mL of this solution added to 30 mL of drinking water). However, its efficacy in birds has been questioned as it has been shown to cause gout in



some birds

on



Visceral gout with urate deposits thickly coating the heart. The typical appearance of urate deposits under the skin the leg of an Australian parakeet. These parakeets are often affected by 'gout'.

## Pruritic birds

External parasites are very uncommon in parrots, except for *Cnemidocoptes pilae* that causes 'scaly face' in budgerigars. These mites live in tunnels in the epidermis and cause considerable skin thickening. The mite can easily be killed with an injection or oral dose of ivermectin (200 g/kg), repeated after 2 weeks. Red mites can cause problems in aviary birds and, occasionally, pet birds.

Most pruritic parrots have some definable behavioural problem, a pyoderma, or internal disease such as hepatitis, air sacculitis or an internal abscess.

