



Stomach of ruminants

The ruminal grooves:

Rumen divided into several parts by the following grooves (pillars from inside):

1/Right & left longitudinal ruminal grooves.

2/Cranial & caudal transverse ruminal grooves.

These 4 grooves (pillars from inside) form together horizontal constriction called the **internal ruminal opening** which divide the ruminal cavity into **dorsal ruminal sac** and **ventral ruminal sac**. Both sacs extend caudally to form the **caudodorsal blind sac** and **caudoventral blind sac**. The caudoventral blind sac extend caudally more than the caudodorsal blind sac **in small ruminants**.

The most cranial part of dorsal ruminal sac called **cranial ruminal sac**, while the most cranial part of the ventral ruminal sac called **ruminal recess**.

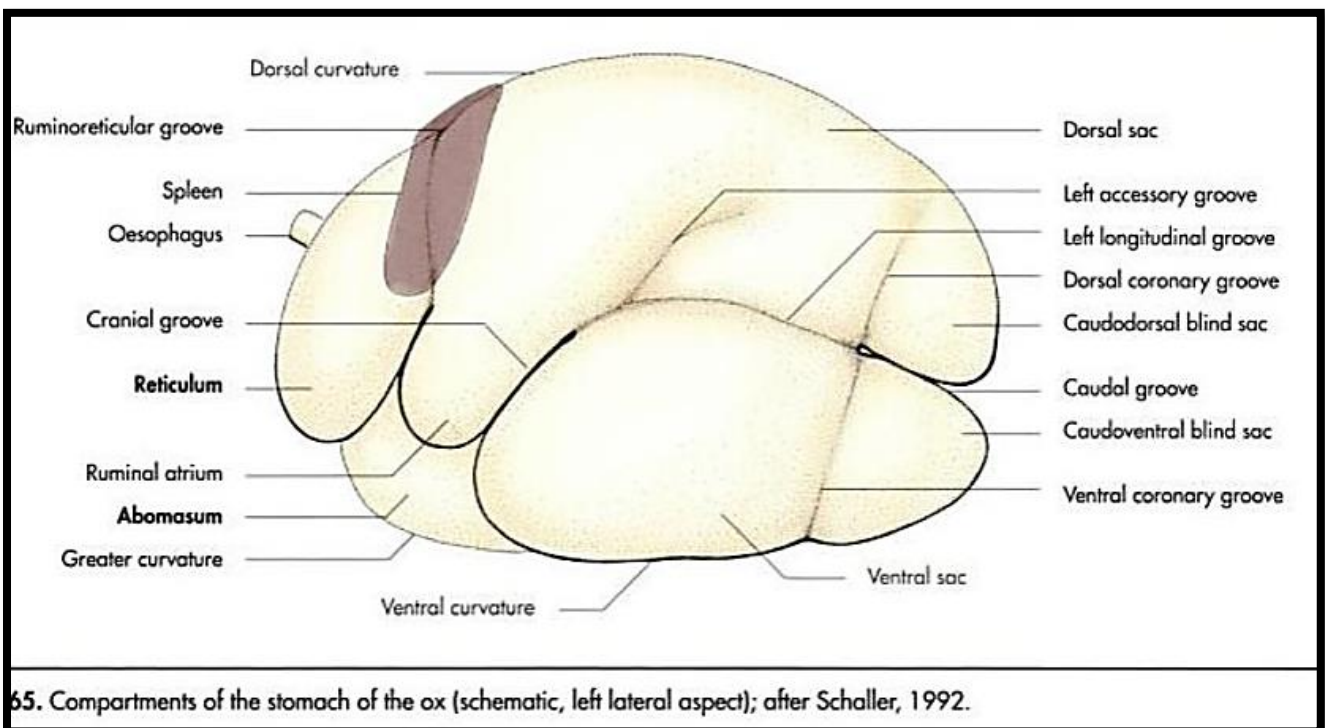
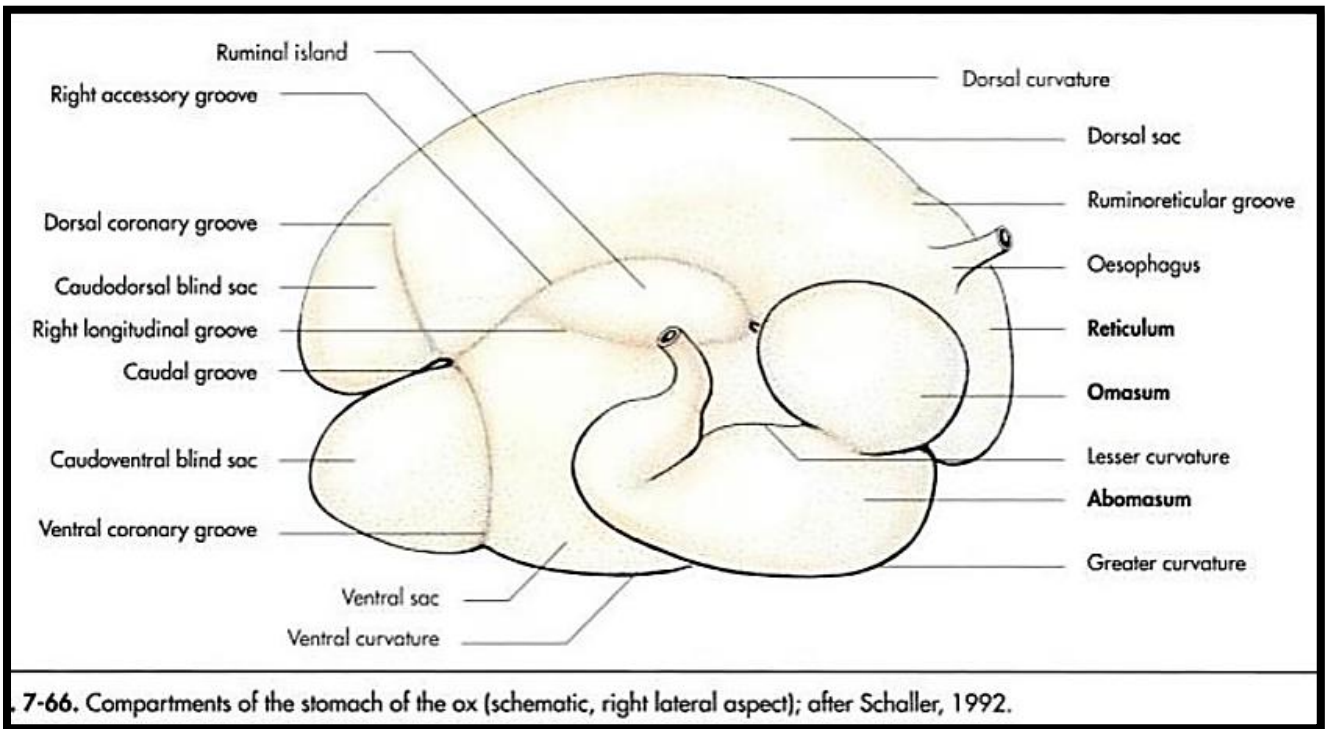
3/**Dorsal & ventral coronary grooves**: act with the longitudinal and transverse grooves to demarcate the blind sacs.

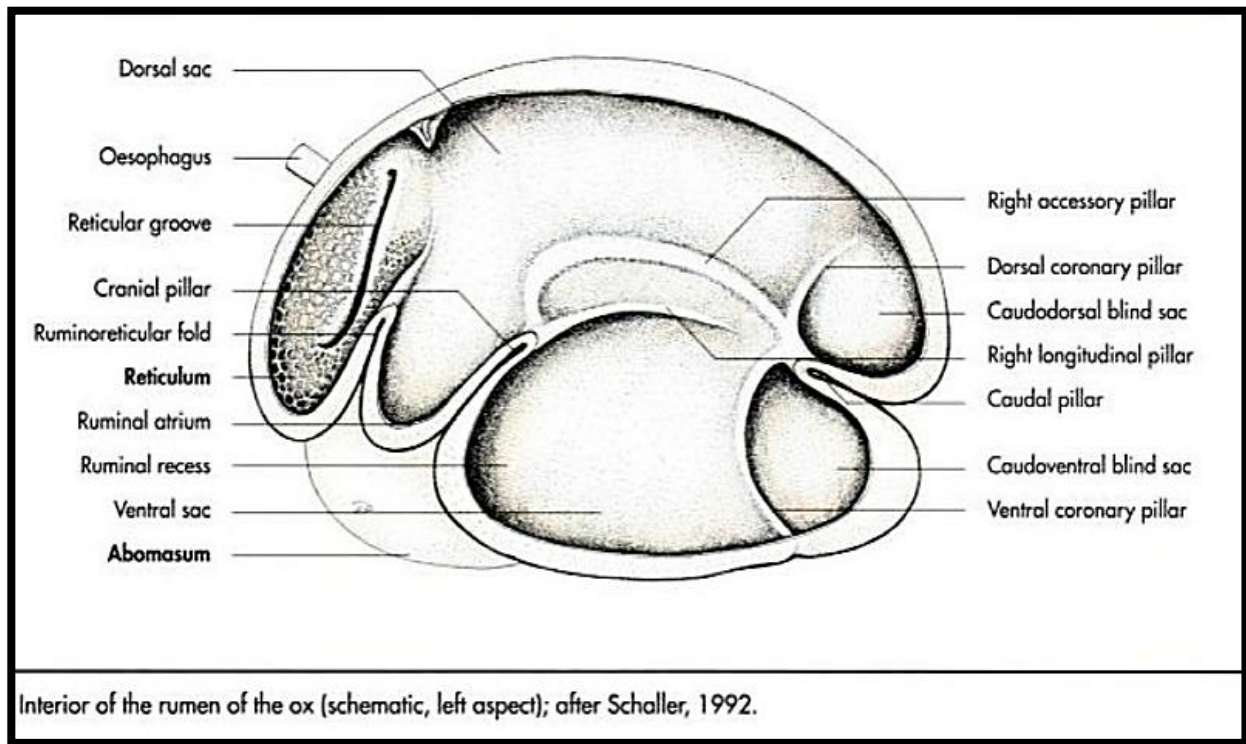
4/**Right & left accessory ruminal grooves**: the right accessory groove form with the right longitudinal groove the **ruminal island** also called (**insulla rumini**).

The esophageal opening is opposite to rumino-reticular opening **because esophagus join the stomach at the junction of rumen with the reticulum**.



The **ruminal mucosa** covered by keratinized stratified squamous epithelium and form large conical or tongue-shape papillae up to (1 cm) length. Papillae are well developed in ventral ruminal sac but absent at pillars and ruminal island and roof of dorsal ruminal sac. **Papillae** increase the surface area of ruminal mucosa.



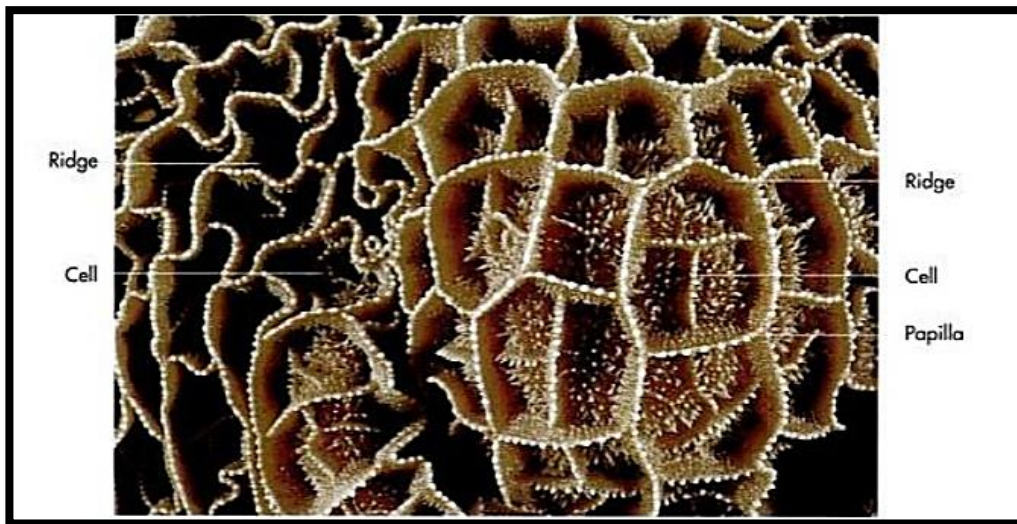


The reticulum: lies cranially in the intra-thoracic part of abdominal cavity between the diaphragm and the rumen, at the level of the 6th-9th intercostal space. It has compressed spherical shape.

Non glandular mucosa of reticulum forms permanent crest (folds) (**8-12 mm**), which intersect to form **honey comb-like cells** which in turn subdivided by lower secondary crests. Both primary and secondary and the floor of honey comb-like cells are studded with small papillae.

The reticulum has clinical importance due to its position near the diaphragm and the heart, which can penetrate by infected metallic foreign bodies lead to clinical case called **TRP=Traumatic Reticulo-Pericarditis**.





The omasum: last compartment of the fore stomach. It has compressed **spherical shape** larger than reticulum in cattle and **oval shape** smaller than reticulum in sheep.

The omasum lies above abomasum at the right side of abdominal cavity. It joins with the reticulum through reticulo-omasal opening and with the abomasum through omaso-abomasal opening that characterized by presence of **vela abomasica**, which is double mucous fold flanked the omaso-abomasal opening and control its closure.

Omasum internally approximately filled with different sizes of omasal laminae, separated by inter laminar recesses. **The number of the omasal laminae** vary from (70-80) in sheep, (90-120) in cow. The omasal laminae covered with papillae.



Bovine omasum

