

Disturbances of mineral metabolism

Assist. Prof. Enas Sheet

Lecturer Dr. Sanaria Hana

Lecturer Aseel Mohammed

Assist. Prof. Entisar Khazal

Assist. Lecturer Atheer Nabeel

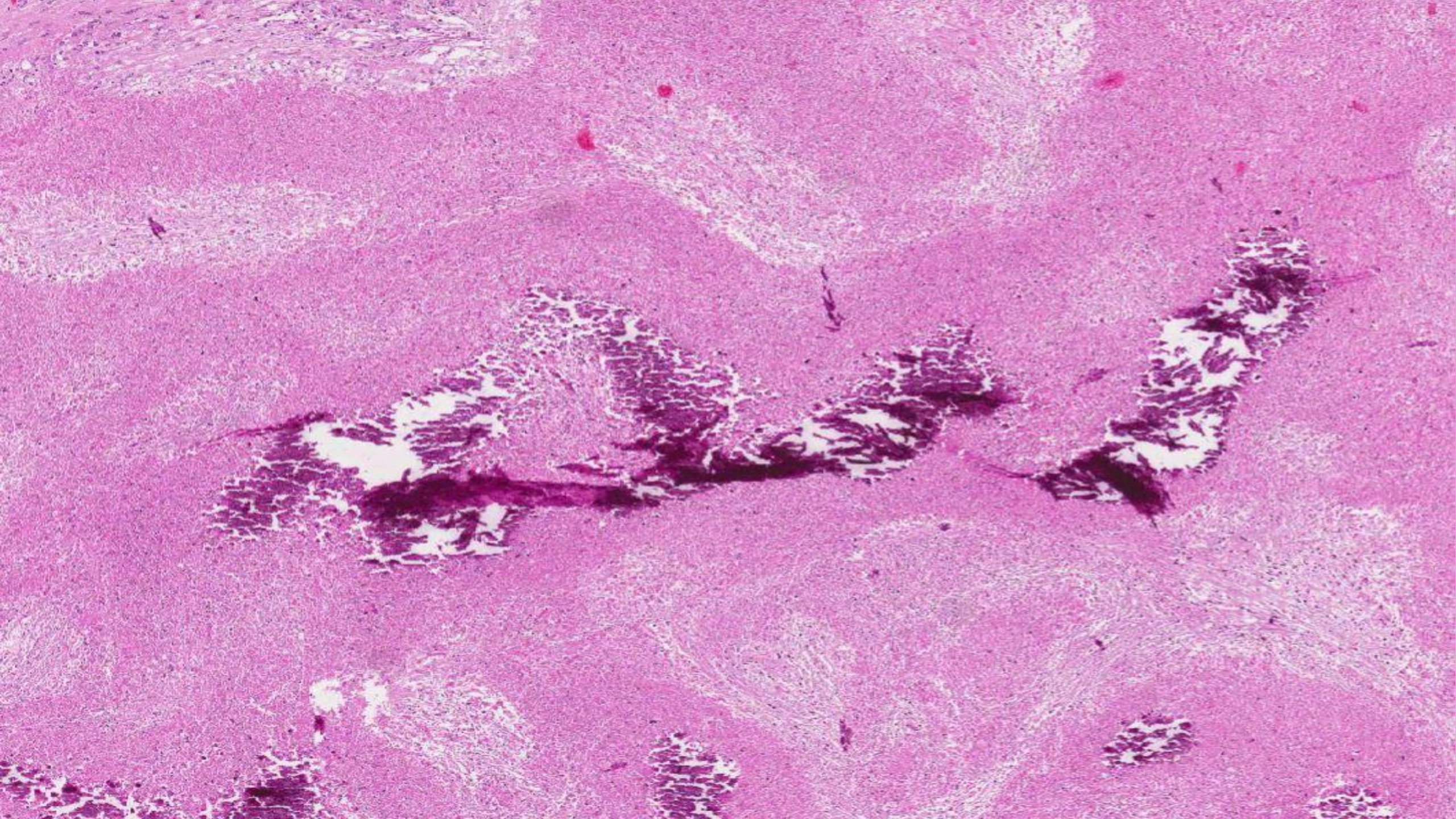
Diagnosis: Dystrophic calcification.

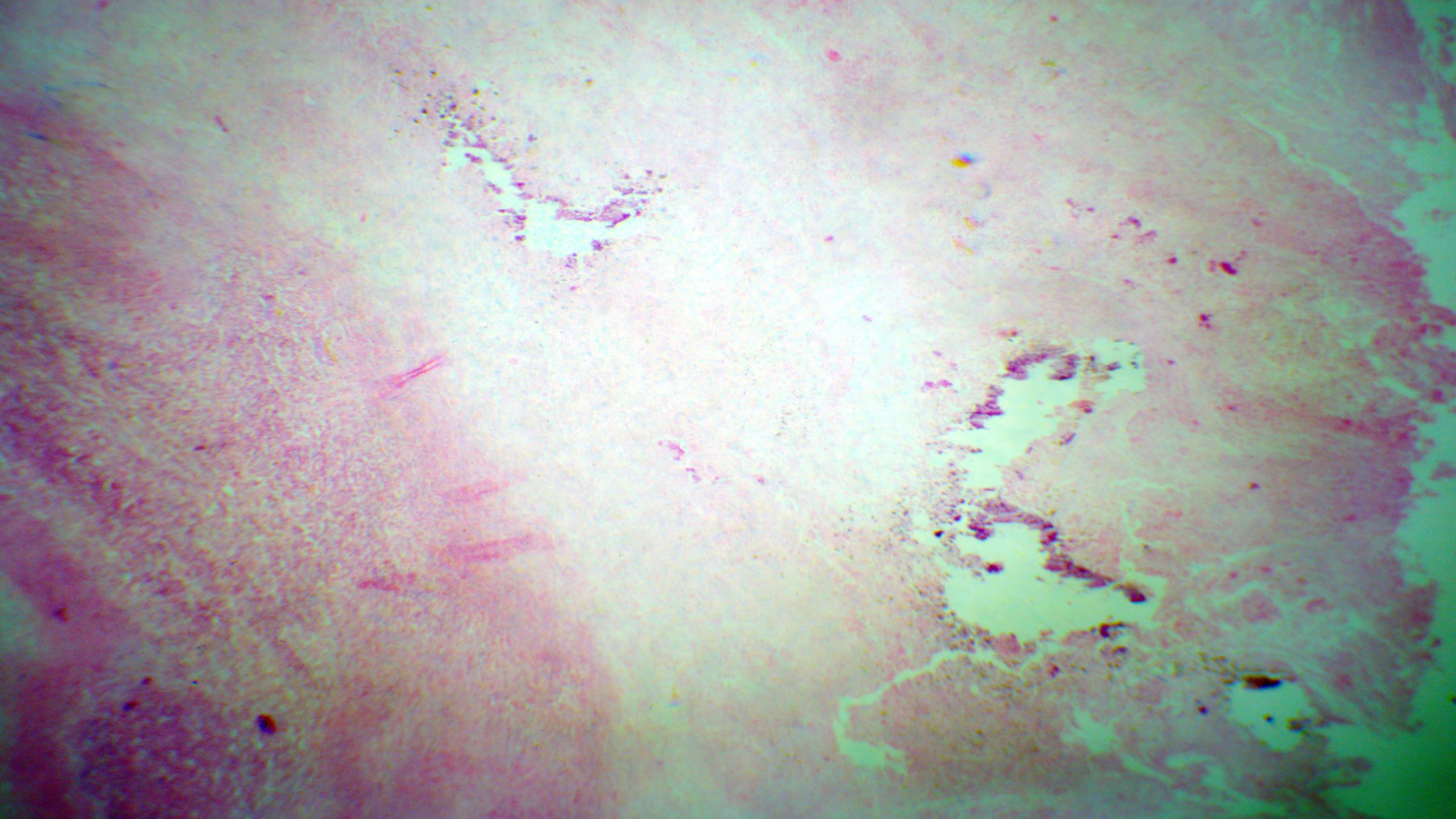
Organ: Liver.

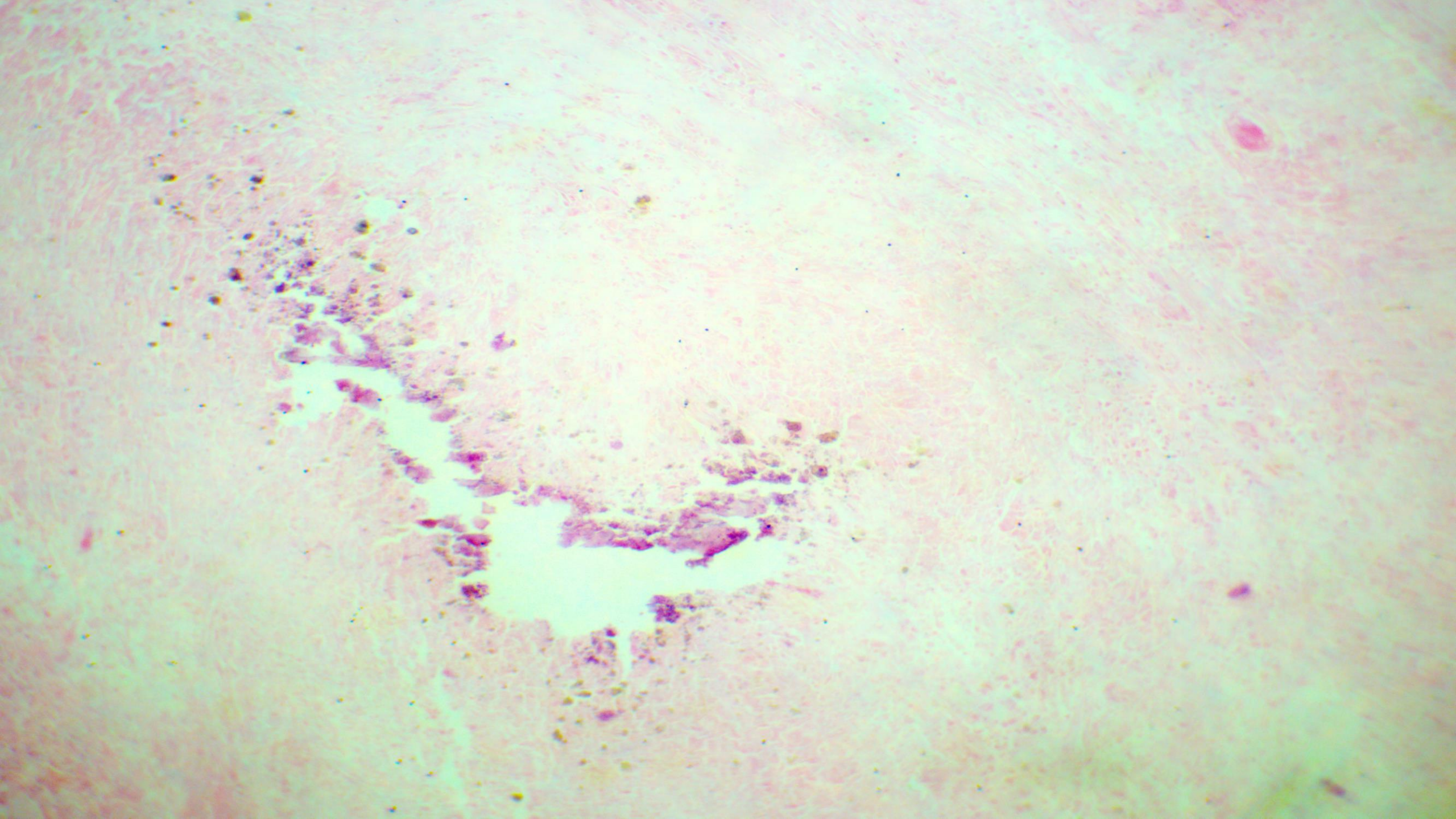
Stain: H&E

Lesion:

Blue patches in the necrotized tissue's center represent Ca salts' precipitation.







Diagnosis: Gout

Organ: Kidney

Stain: H&E

Lesion:

1. Presence of urate crystals as needle shape in the lumen of renal tubules.
2. Infiltration of inflammatory neutrophils, macrophages, and foreign body giant cells.

