

Lumpy skin disease

Assist. Prof. Entisar Khazal

Lecturer Aseel Mohammed

Assist. Lecturer Atheer Nabeel

Assist. Lecturer Thanon Younes

Synonyms

Pseudourticaria

Neethling Virus Disease

Exanthema Nodularis Bovis.

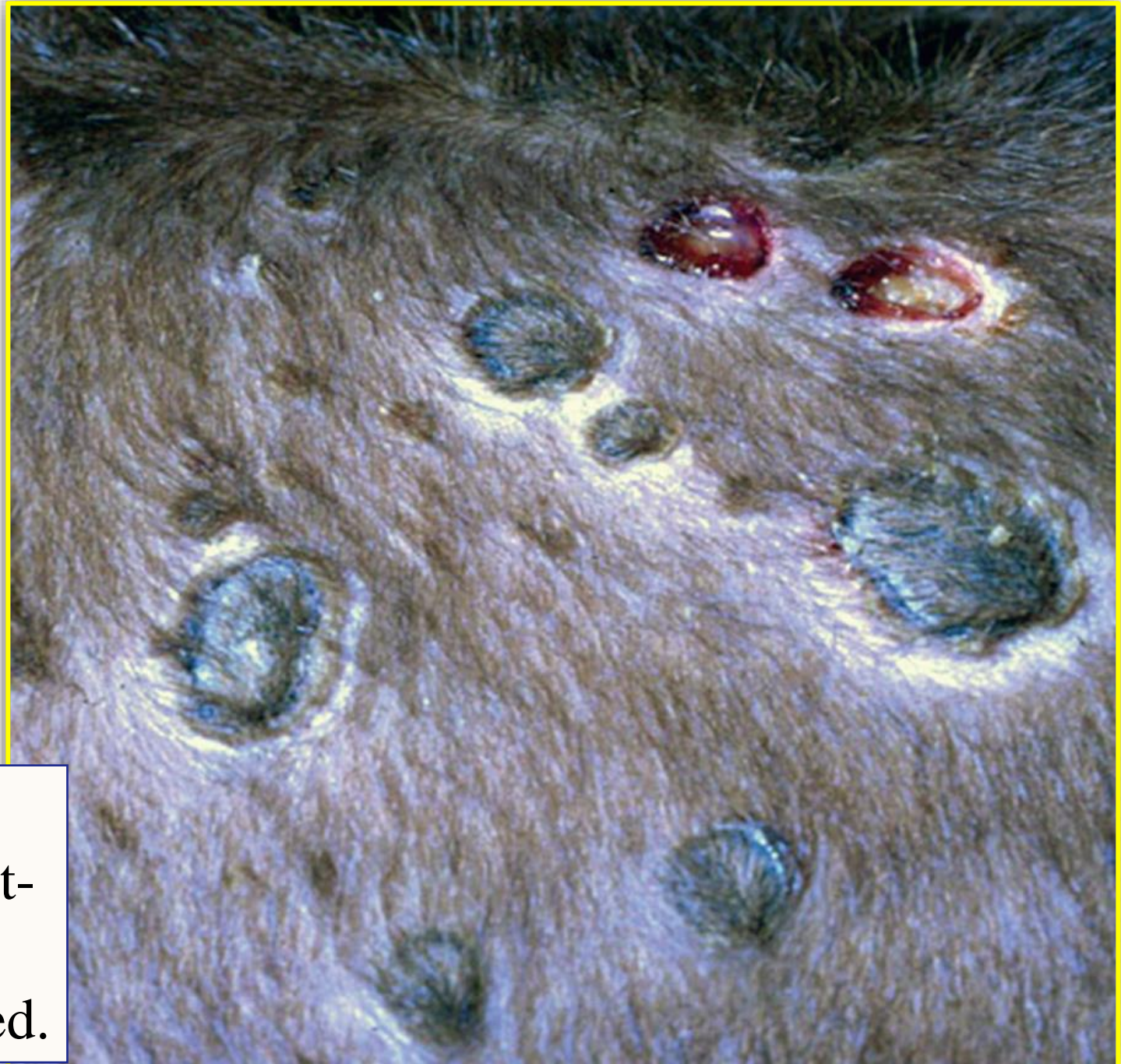- Lumpy skin disease, caused by species Lumpy skin disease virus of the genus **Capripoxvirus**, is a disease of cattle, buffalo, and occasionally other wild species of hoofstock.
- The disease is characterized by the **eruption of multiple, well circumscribed skin nodules**, accompanied by **fever, ventral edema**, and **generalized lymphadenopathy**.
- The morbidity is extremely variable, and inapparent infection is common. Mortality is usually low; around 1% but may be >50%.

- Economic losses are due to **debilitation, loss of milk and meat production, damage to hides**, and reproductive wastage resulting from fever-associated **abortions** and **temporary sterility** in bulls.
- The natural incubation period of lumpy skin disease is **2-4 weeks**.
- Transmission of the LSD virus is primarily by **biting insects**, particularly **mosquitoes** (e.g. *Culex mirificens* and *Aedes natrionus*).

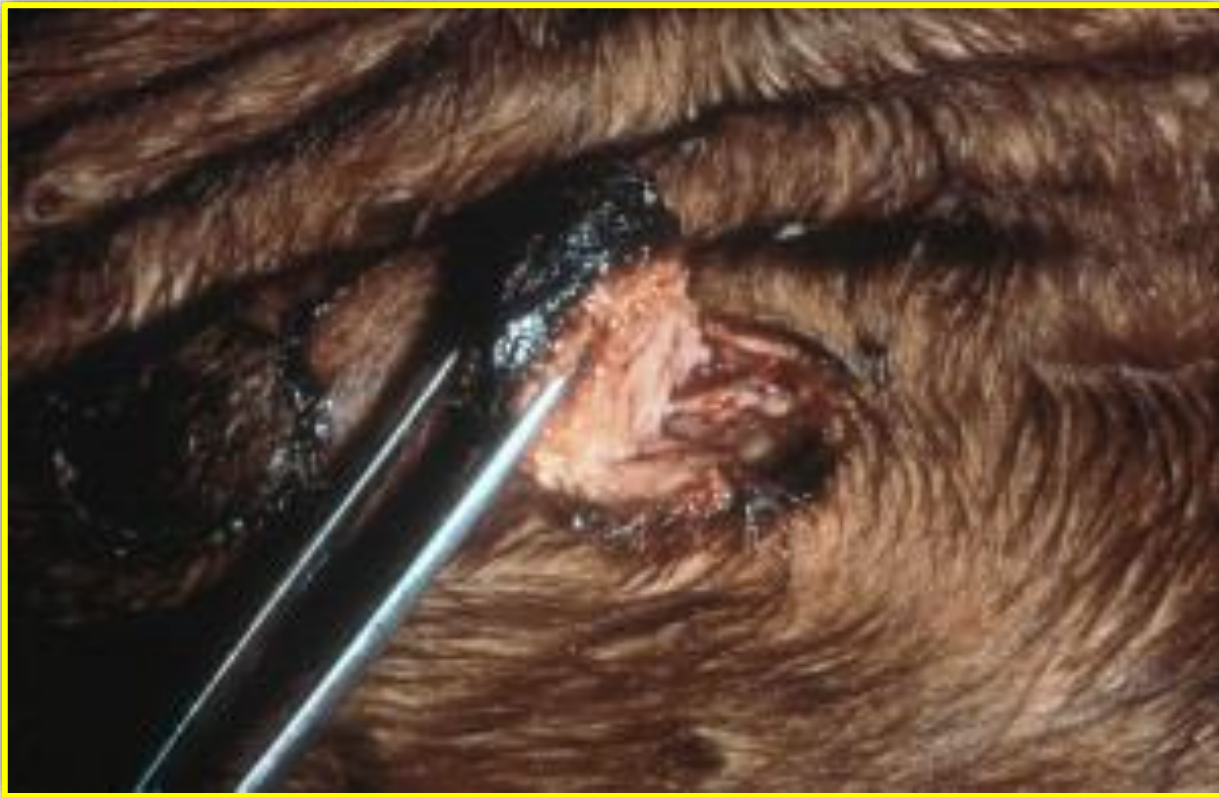- Epidemics tend to follow periods of prolonged rainfall, which favor population increases in vector species.
- Direct contact is also a minor source of infections.
- Virus can be present in **cutaneous lesions, saliva, nasal discharge, milk, and semen**. The virus can survive in desiccated crusts **for up to 35 days**.
- Clinical signs can range from inapparent to severe. Host susceptibility, dose, and route of virus inoculation affect the severity of disease. **Young calves often have more severe disease.**

- Skin nodules may be few in number to many hundreds, **and may coalesce to form plaques.**
- **Nodules** may **occur** on any part of the body, but they are particularly common on the **head, neck, udder, genitalia, perineum, and legs.** Swollen skin nodules may separate from the healthy skin and dry and harden to form a “sit-fast”.

The cutaneous lesions are firm, circumscribed, flat-topped papules and nodules, 0.5-5.0 cm in diameter and **penetrate the full thickness of the skin.**



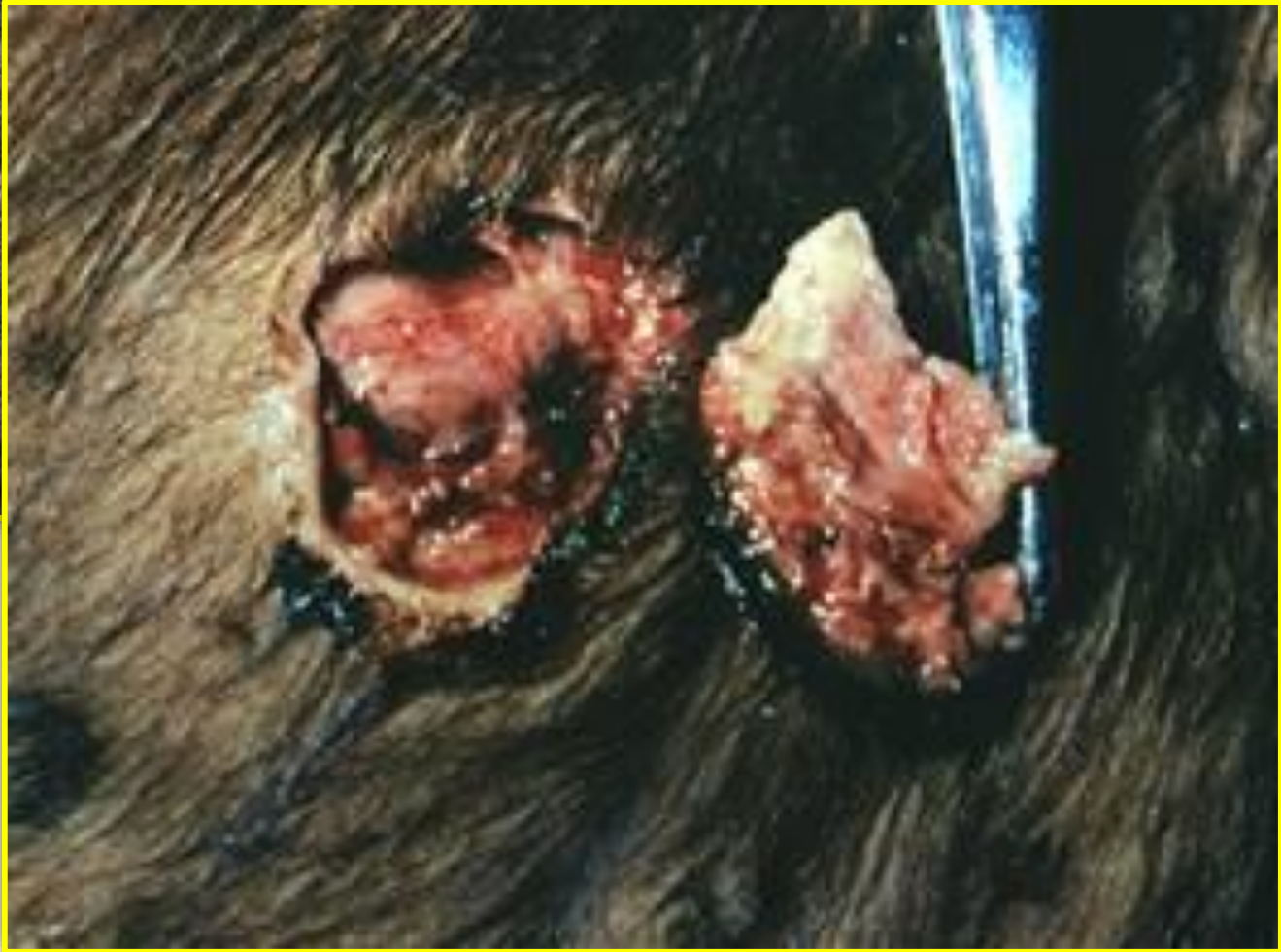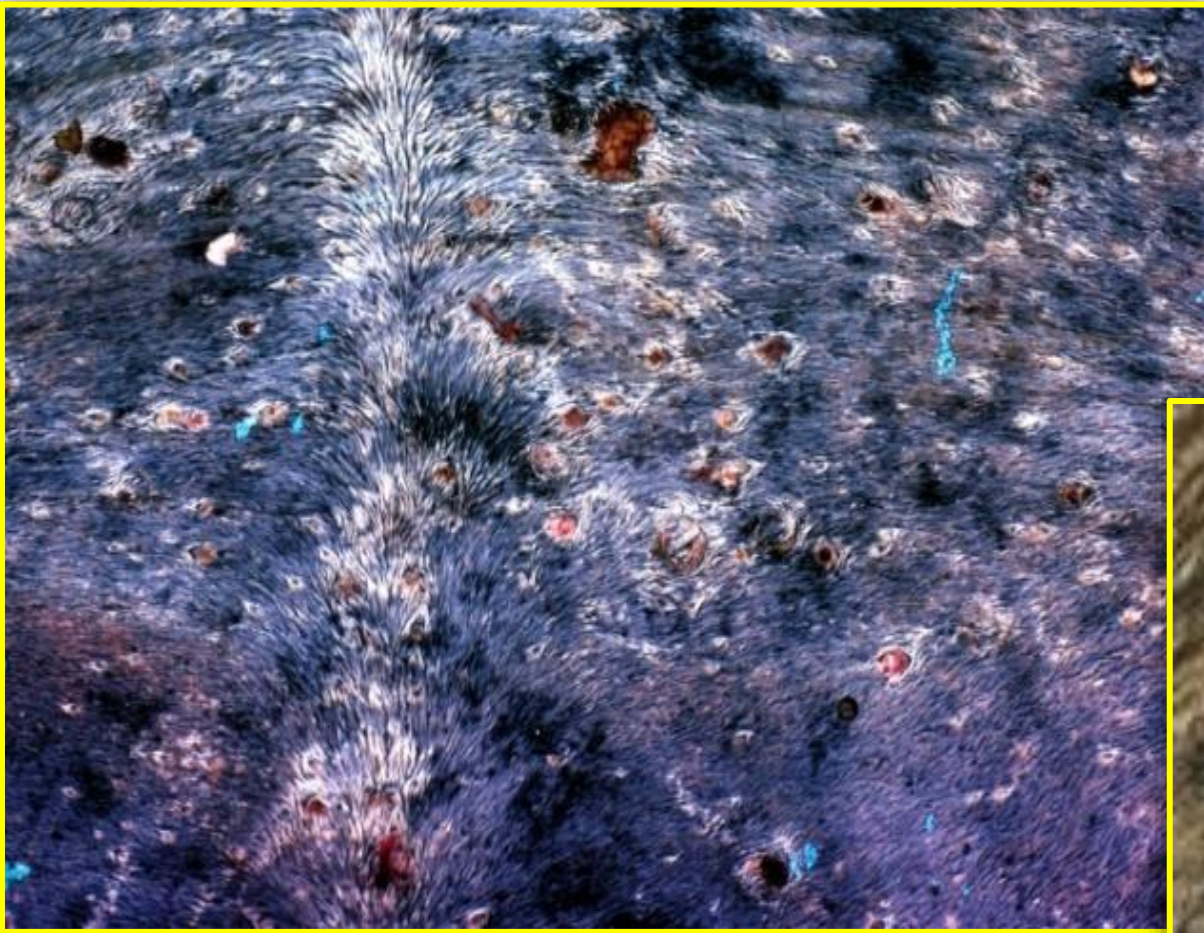Lumpy skin disease in a calf.
Circumscribed necrotic tissue (“sit-fasts”) and deep ulcers.
Two of these papules have sloughed.

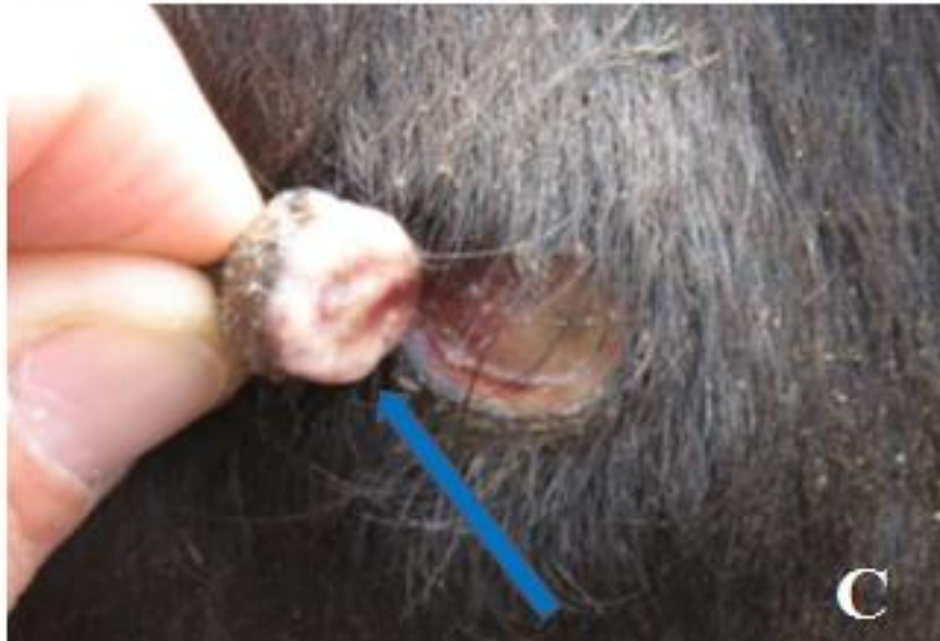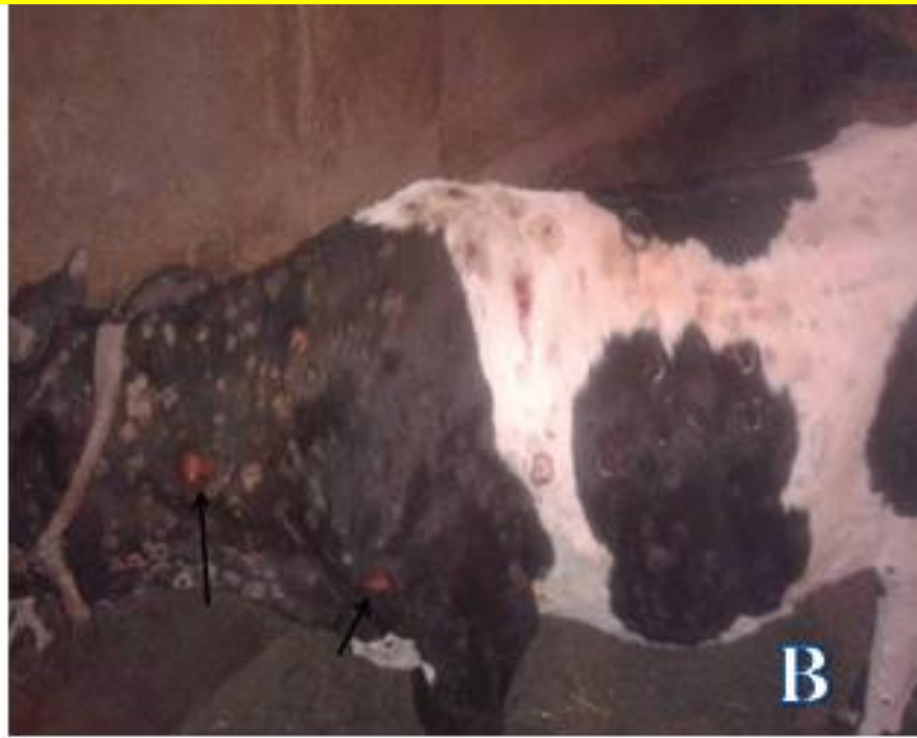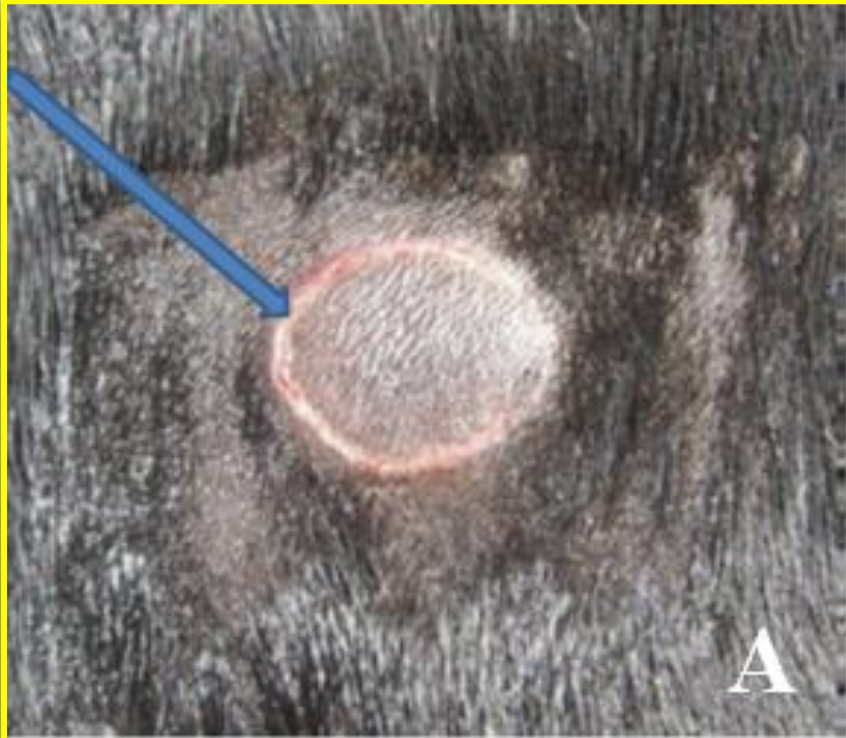


Organ: skin

Lesion: Cattle showing nodules usually undergo necrosis and separated from the surrounding skin forming a cone of necrotic tissue

Diagnosis: lumpy skin disease.





Distinguishing
lesions of LSD:

(A) Raised and
separated narrow
ring of haemorrhage

(B) skin lesions
leaving ulcer

(C) “sit fast” like
“inverted conical
zone” of necrosis


Clinical picture of lumpy skin disease in cattle.



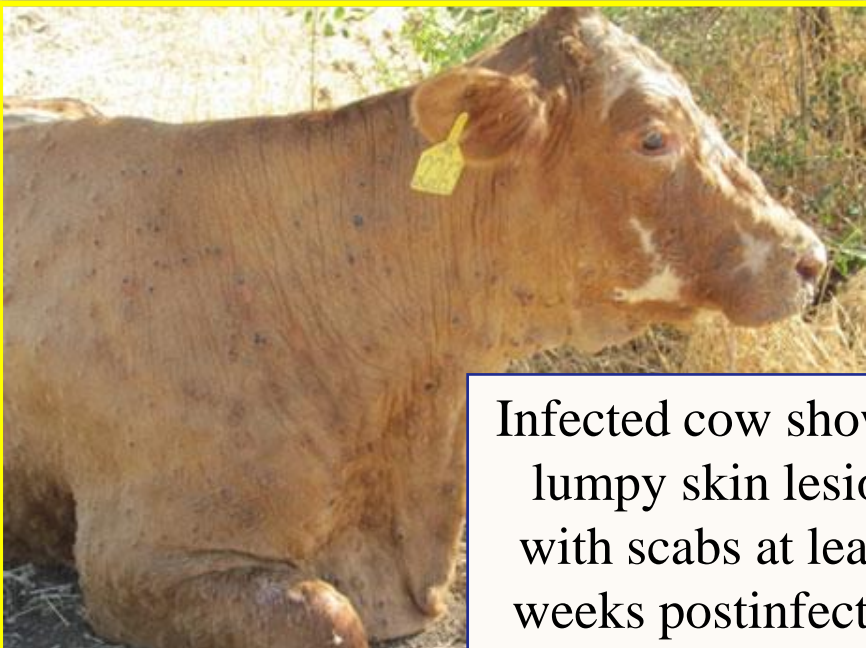Cow with multiple skin nodules approximately 2 weeks postinfection.

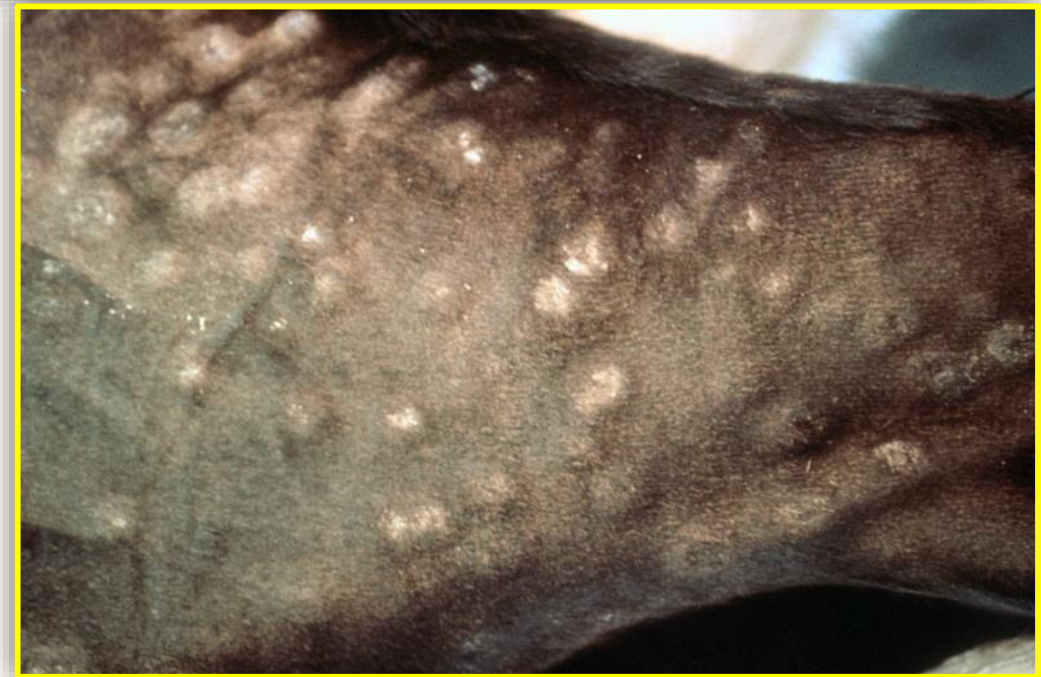

Lumpy skin disease infected cow, showing a loss of body weight and skin lesions.

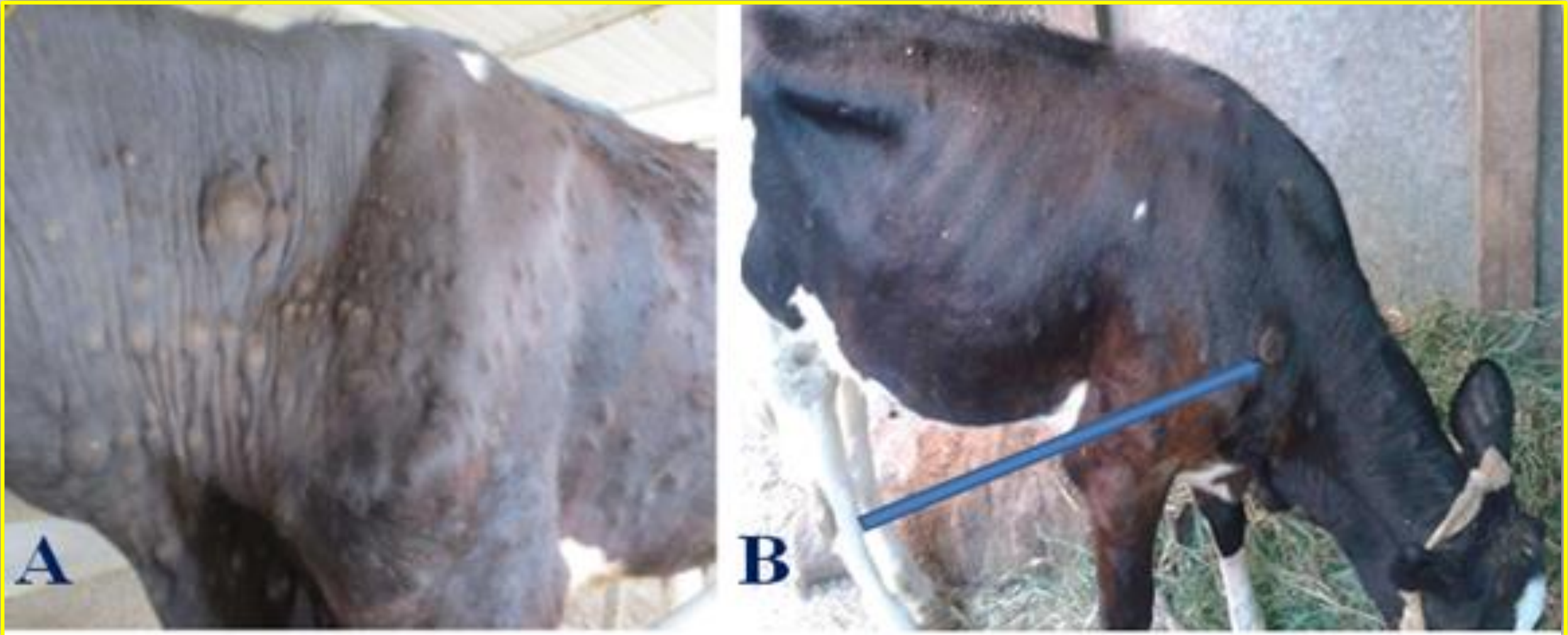


Infected cow showing lumpy skin lesions with scabs at least 3 weeks postinfection.



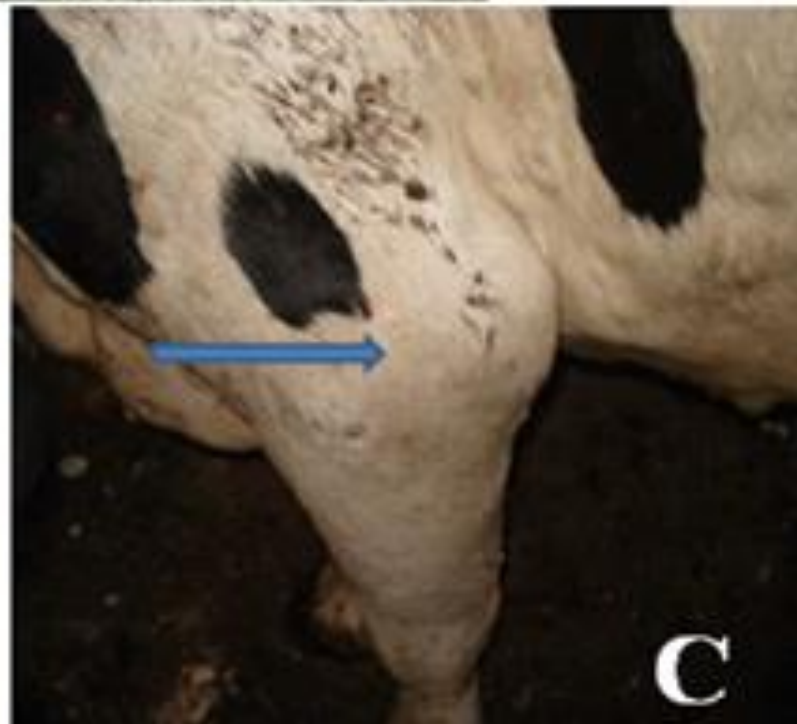

Cattle showing numerous nodules due to lumpy skin disease



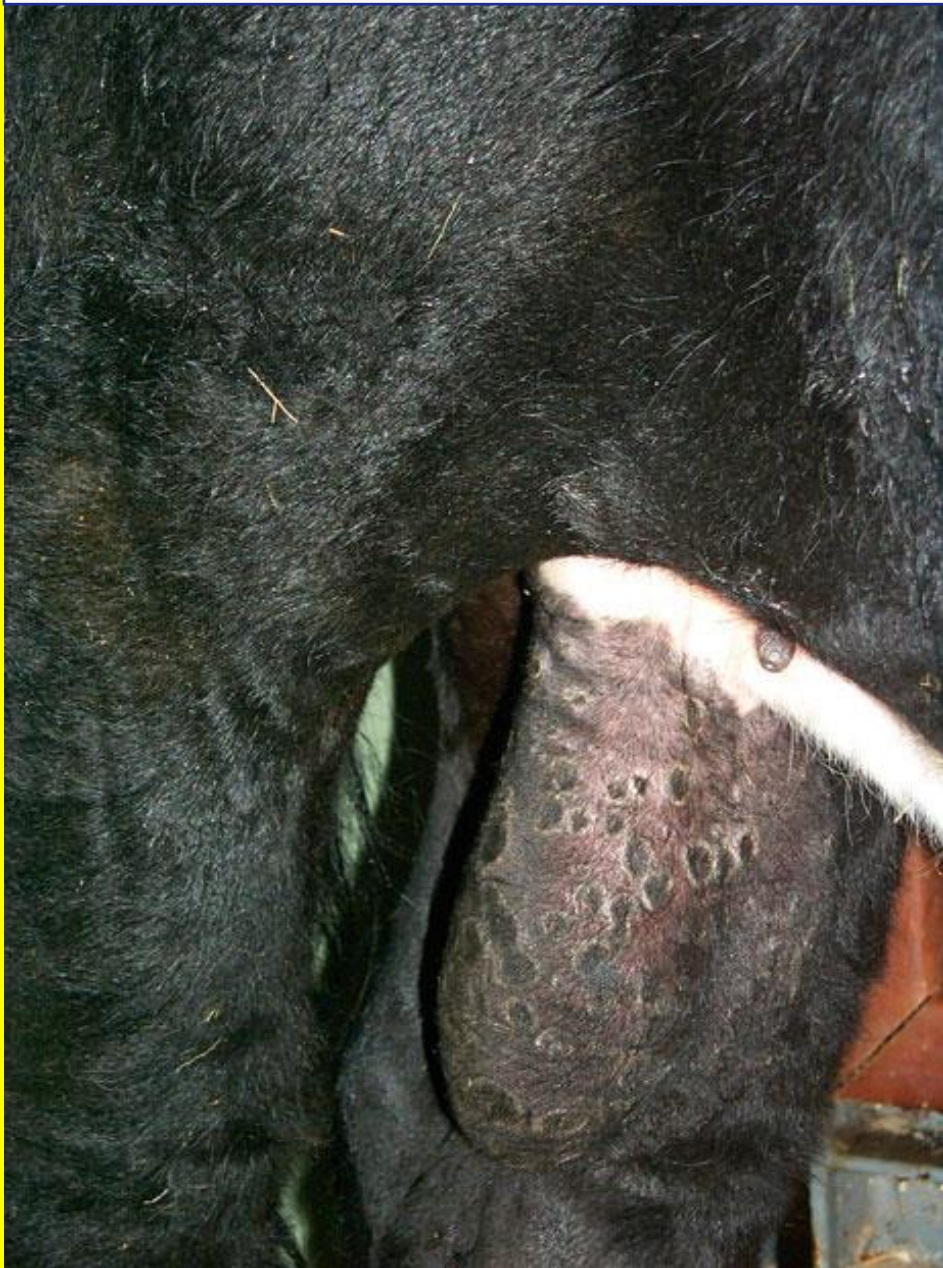Characteristic LSD nodular lesion indicating severity: Lesion covering the whole body in severe form (A) and LSD with few skin nodules in mild form (B).

- **Secondary bacterial infections** may occur.
- **Rhinitis and conjunctivitis can also be seen.**
- **Lameness** may result from inflammation and edema of the legs, and abortion and sterility may occur in both bulls and COWS.

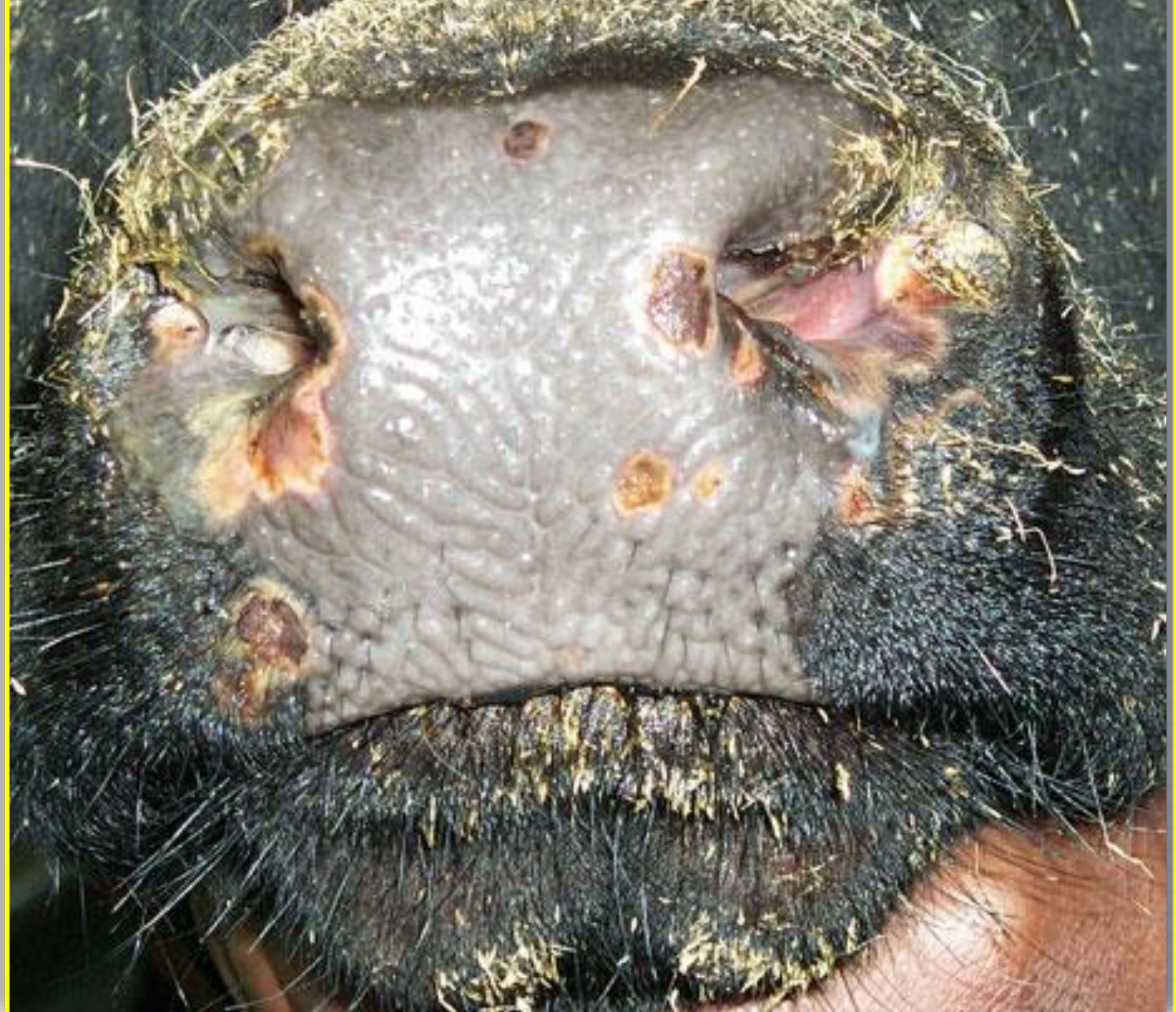

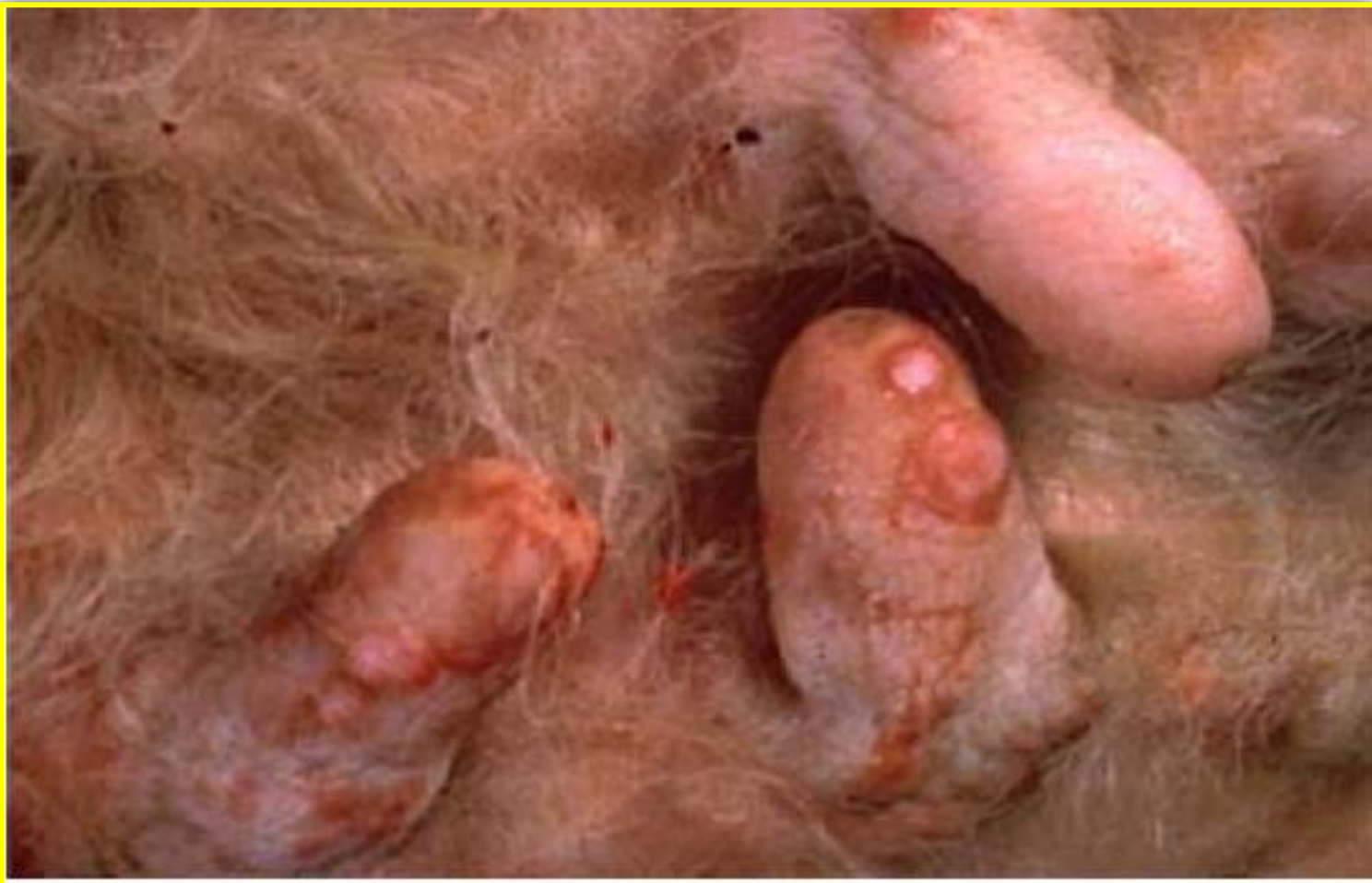Edematous and inflammatory swelling on different parts of the body; (A) on the face brisket (B) and limb (C) of affected cattle.

Lumpy skin disease infected bull showing skin lesions in the scrotum.



Lumpy skin disease infected bull showing pox lesions in the muzzle.





.Organ:mamary gland

- Diagnosis:lumpy skin disease

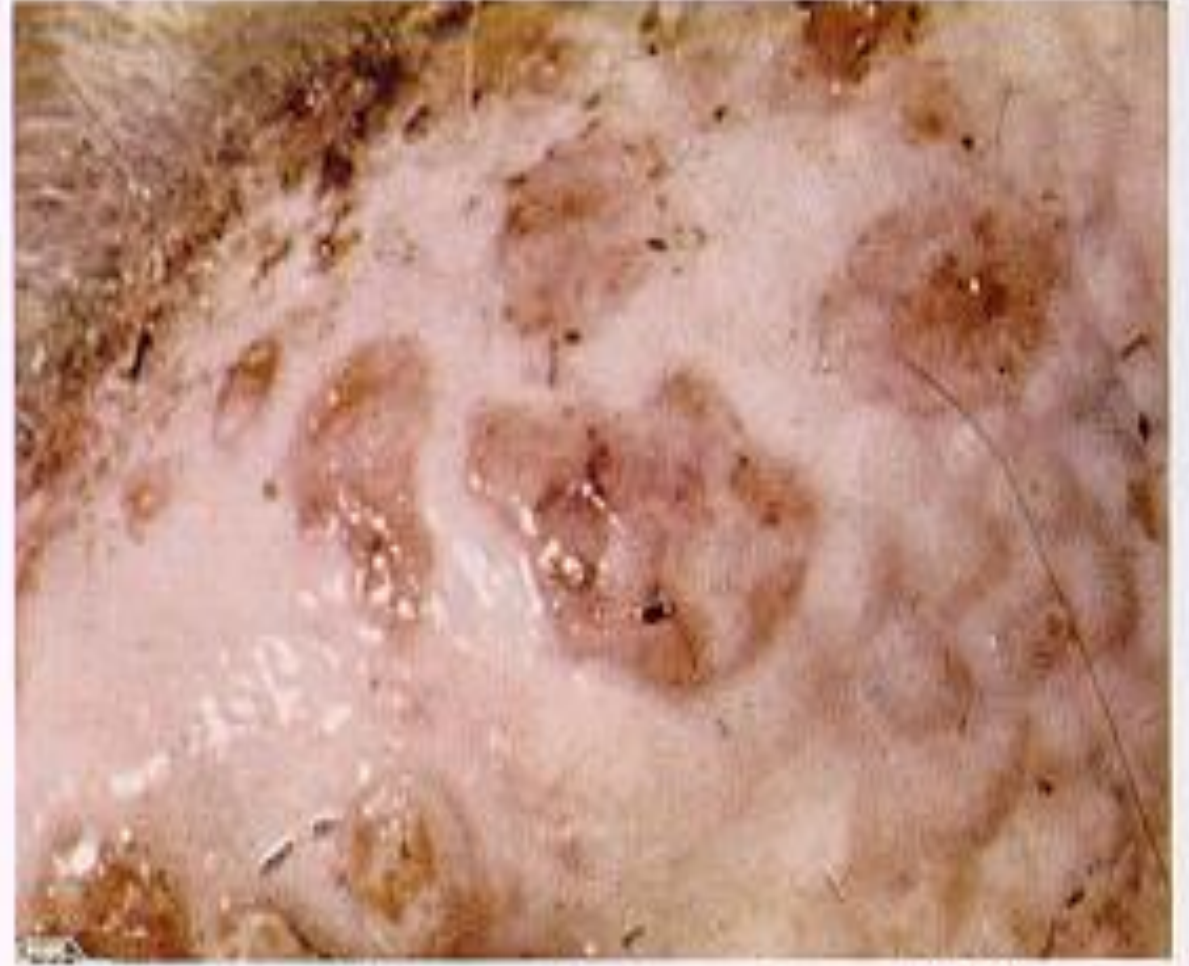
- cattle showing lumpy nodule in teat

- Post mortem lesions can be extensive. Characteristic deep nodules are found in the skin which **penetrate into the subcutaneous tissues and muscle with congestion, hemorrhage, and edema.**
- Lesions may also be found in the **mucous membranes of the oral and nasal cavities as well as the gastrointestinal tract, lungs, testicles, and urinary bladder.**

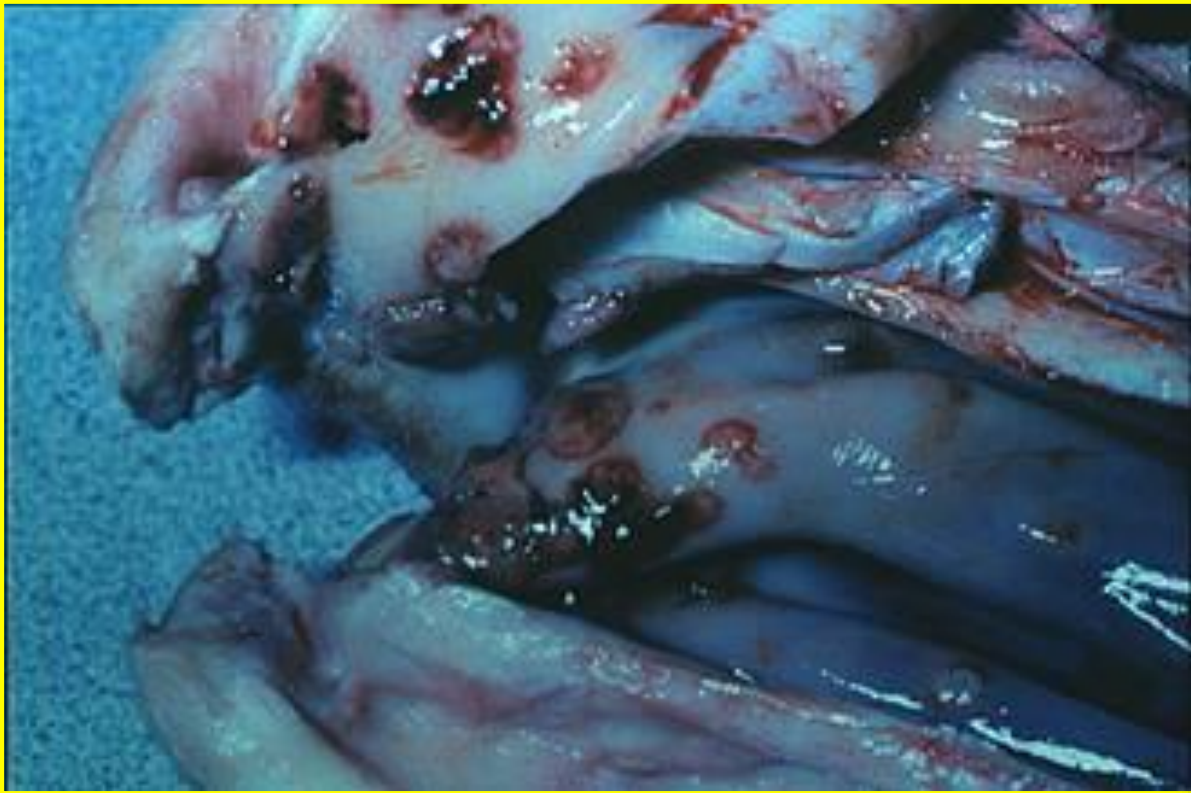Lesion of the skin: outer and inner surfaces



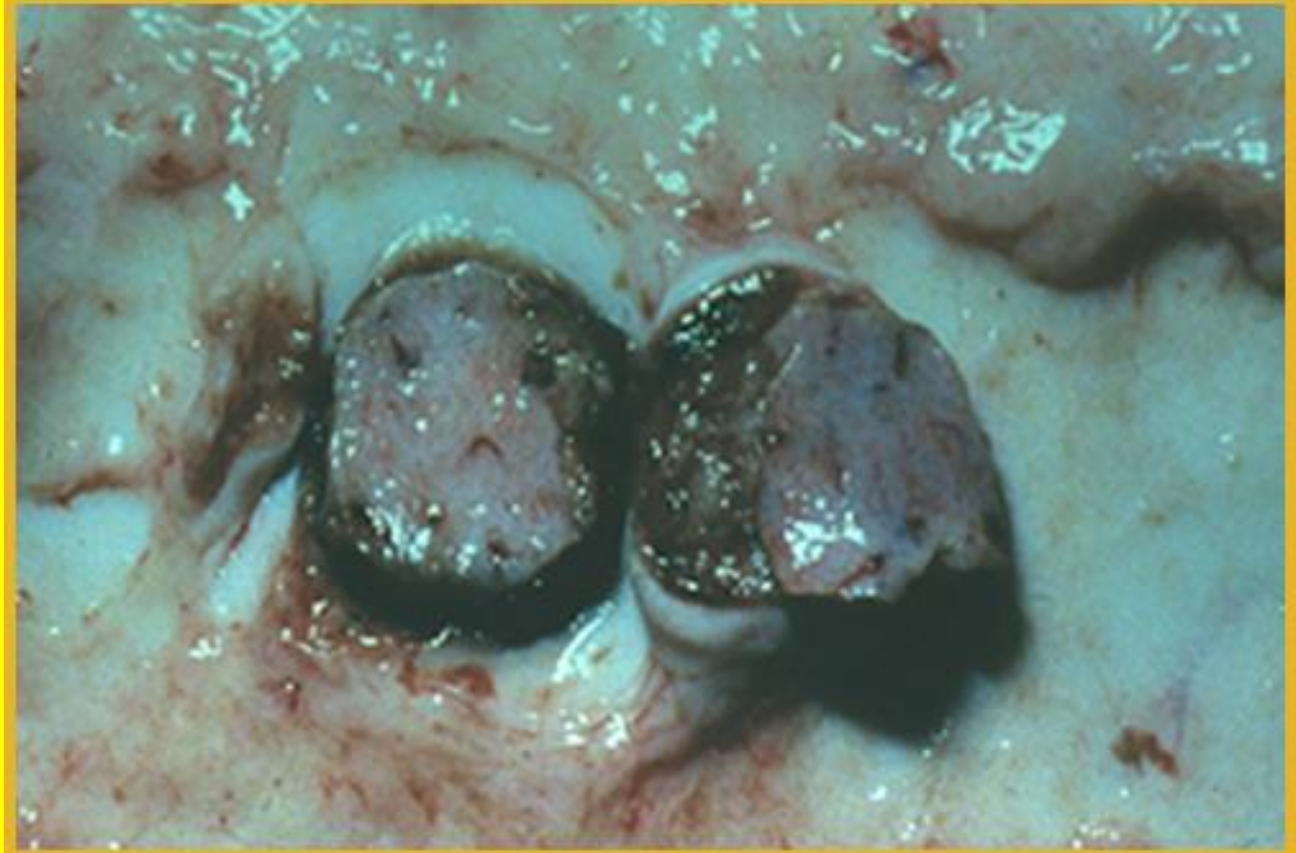3 Close-up view of early nodular lesions (LSD).



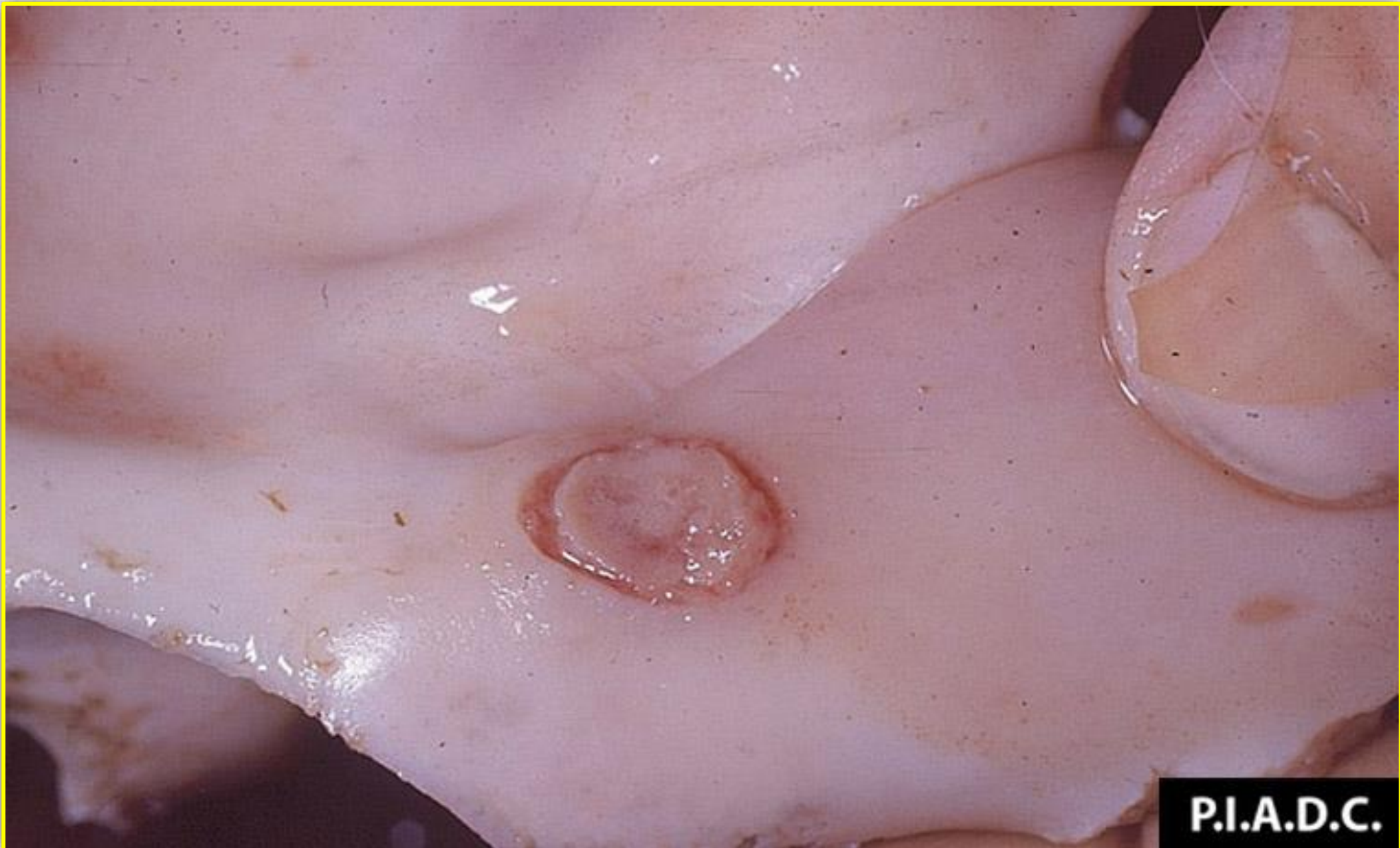6 Close-up view of lesions on the nares and muzzle (LSD).



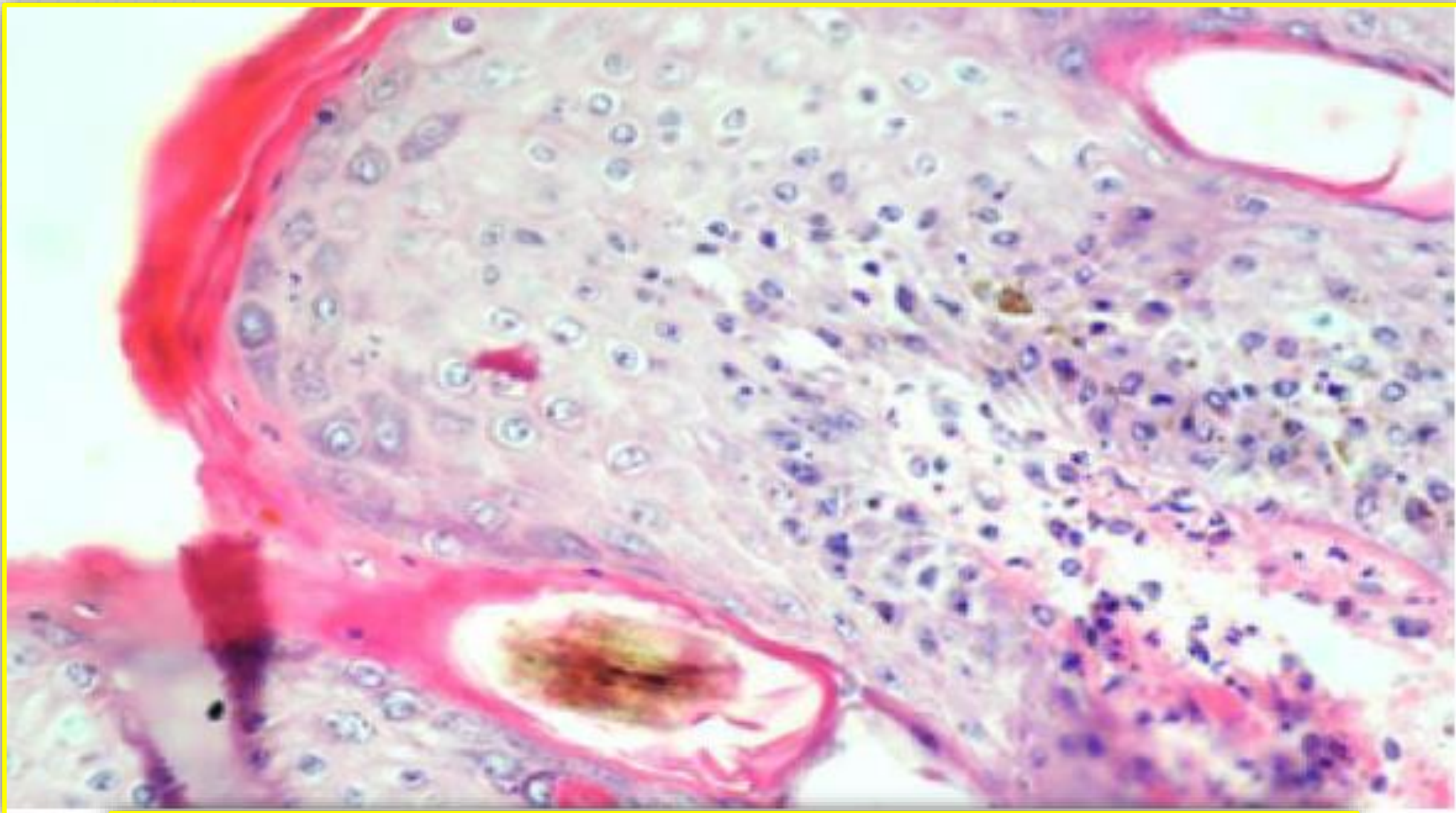
Lesions in the oral cavity



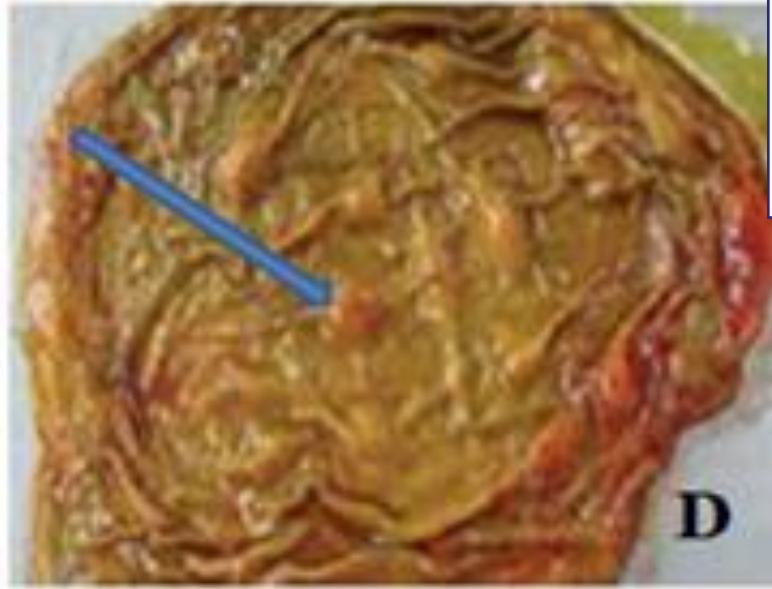
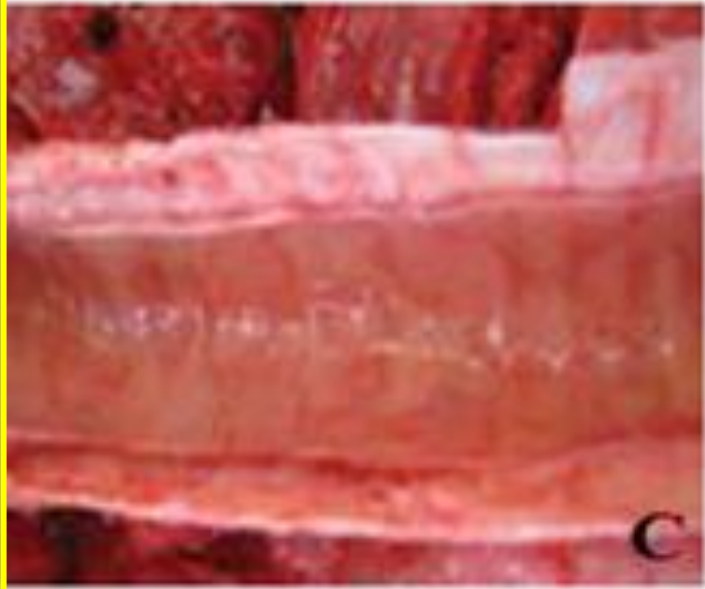
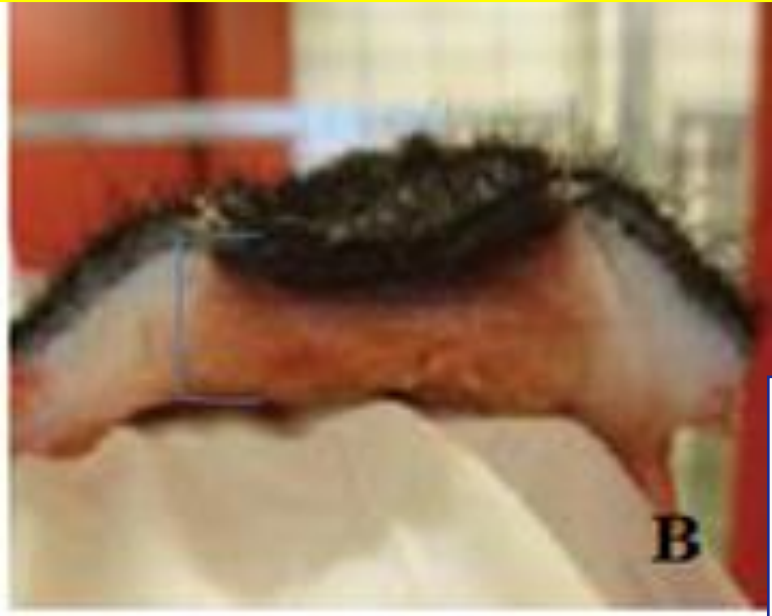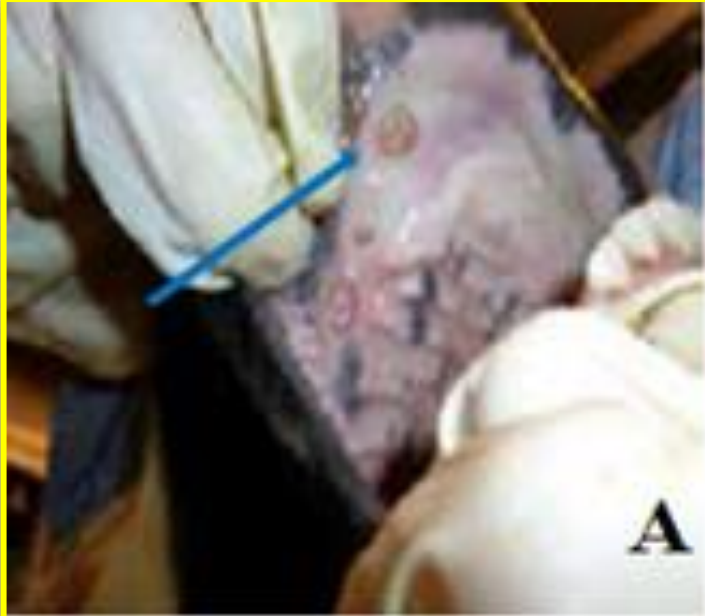Cores of necrotic material called
“sit-fasts”



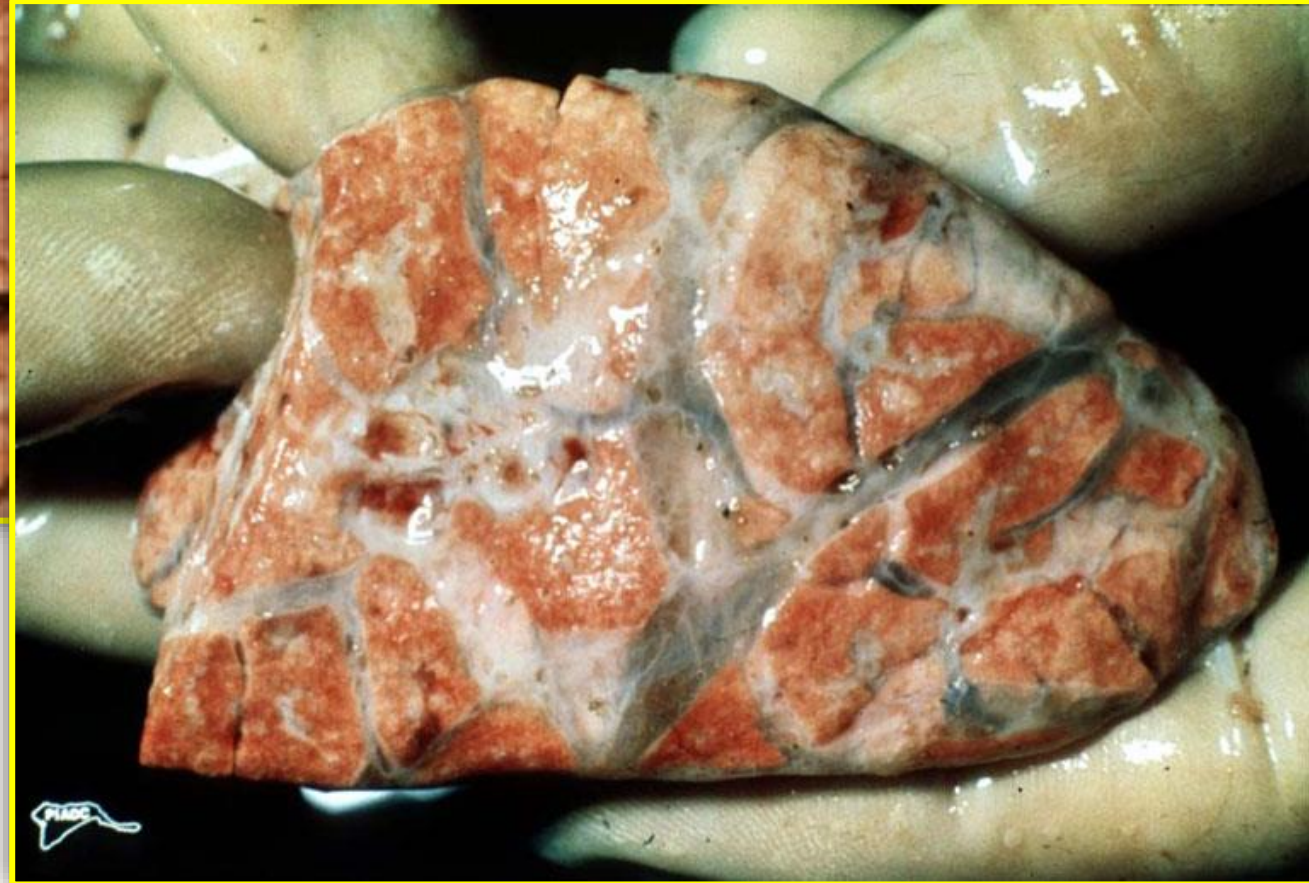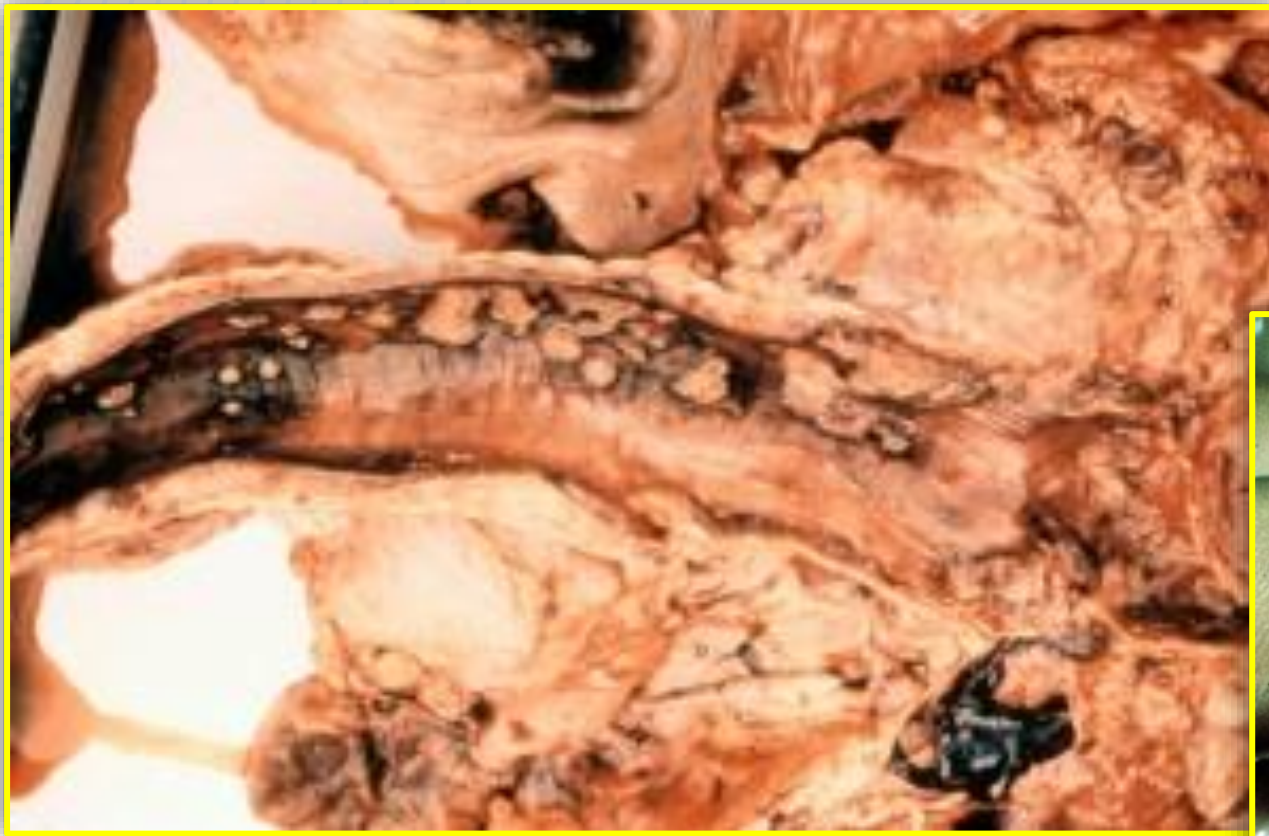lumpy skin disease: bovine nasal turbinate and the centers is well developed.



- Microscopic picture of cattle skin infected with lumpy skin disease showing hyperplastic epithelium containing intracytoplasmic inclusion bodies. H&E



Internal lumpy skin lesions:
Ulcerative lesions in the oral cavity (A) and cross-section of skin lesion (B); lesions in the trachea (C) and gall bladder (D).



lumpy skin disease. lesions extends into the trachea and Lungs.
there is markedly generalized interlobular edema and

The chief differential diagnosis is pseudo–lumpy skin disease caused by a **herpesvirus identical to the bovine herpes mammillitis virus but originally known as the **Allerton virus**.**

Pseudo–lumpy skin disease is a milder condition clinically, and the nodules are superficial, resembling only the early stage of lumpy skin disease.