

# **Reproductive system**

Assist. Prof. Enas Sheet

Lecturer Dr. Sanaria Hanna

Lecturer Aseel Mohammed

Lecturer Entisar Khazal

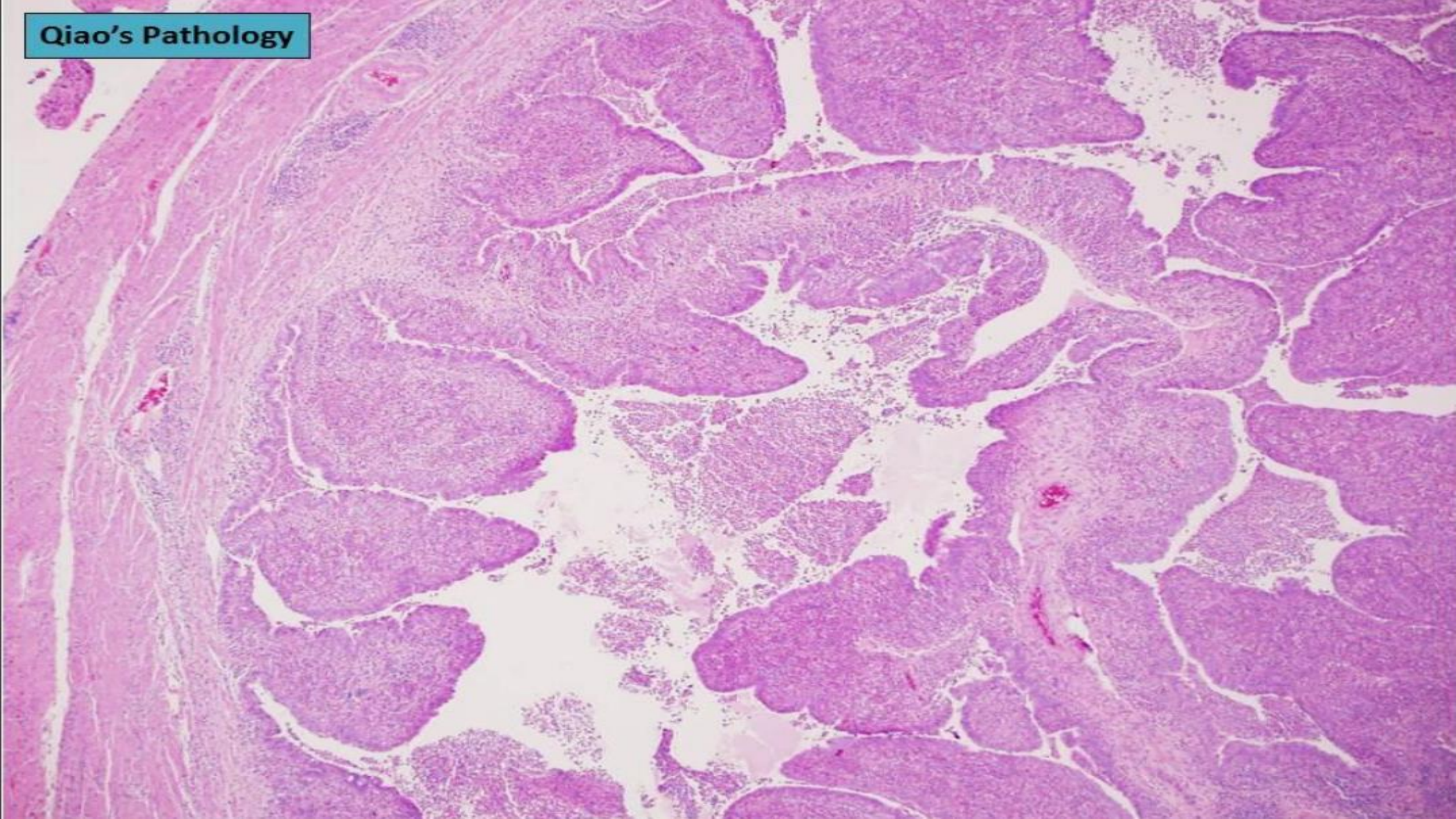
Assist. Lecturer Atheer Nabeel

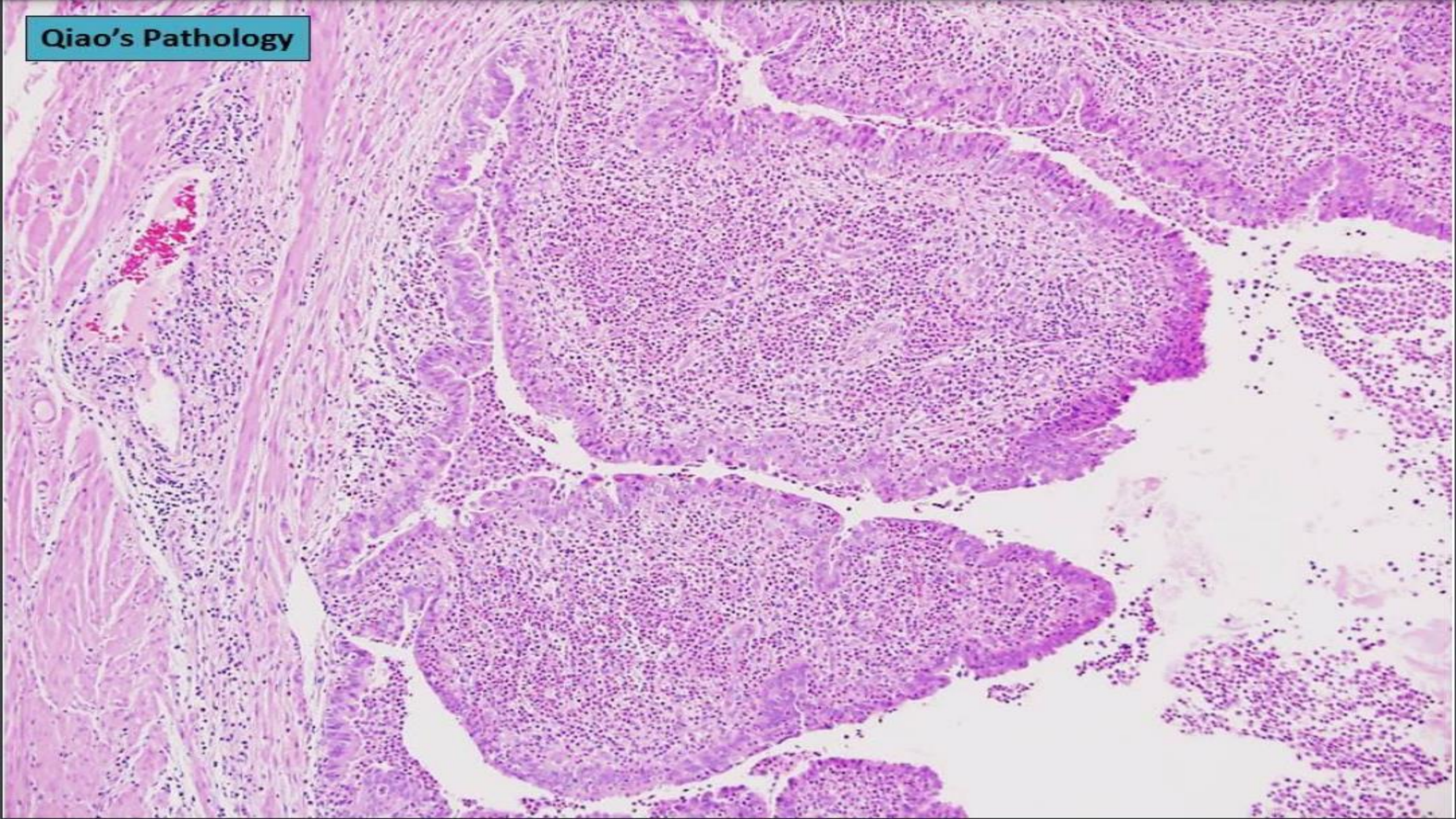
**Diagnosis: Acute salpingitis**

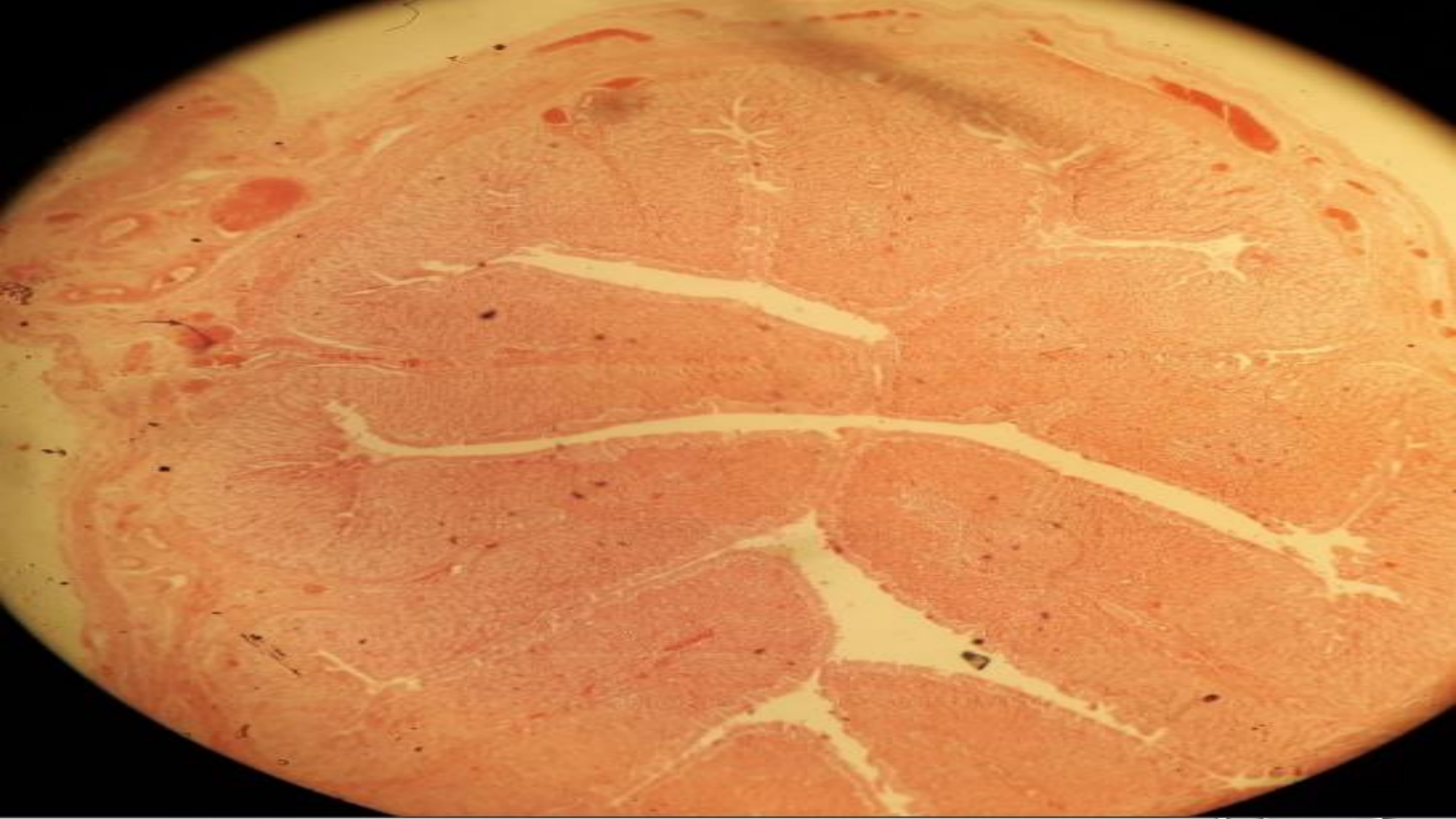**Organ: Salpinx**

**Lesion:**

- 1. Stenosis in the lumen of the oviduct due to thickening in the wall as result of infiltration of polymorphonuclear inflammatory cells.**
- 2. Congestion of blood vessels in the wall of oviduct.**







**Diagnosis: Chronic orchitis**

**Organ: Testis**

**Lesion:**

- 1. Degeneration and necrosis of epithelial cells lining the seminiferous tubules surrounded by mononuclear inflammatory cells and surrounded by capsule of fibrous tissue.**
- 2. Disappearance of some seminiferous tubules which replaced by fibrous tissue.**

