

Urinary System

Assist. Prof. Enas Sheet

Lecturer Dr. Sanaria Hanna

Lecturer Aseel Mohammed

Lecturer Entisar Khazal

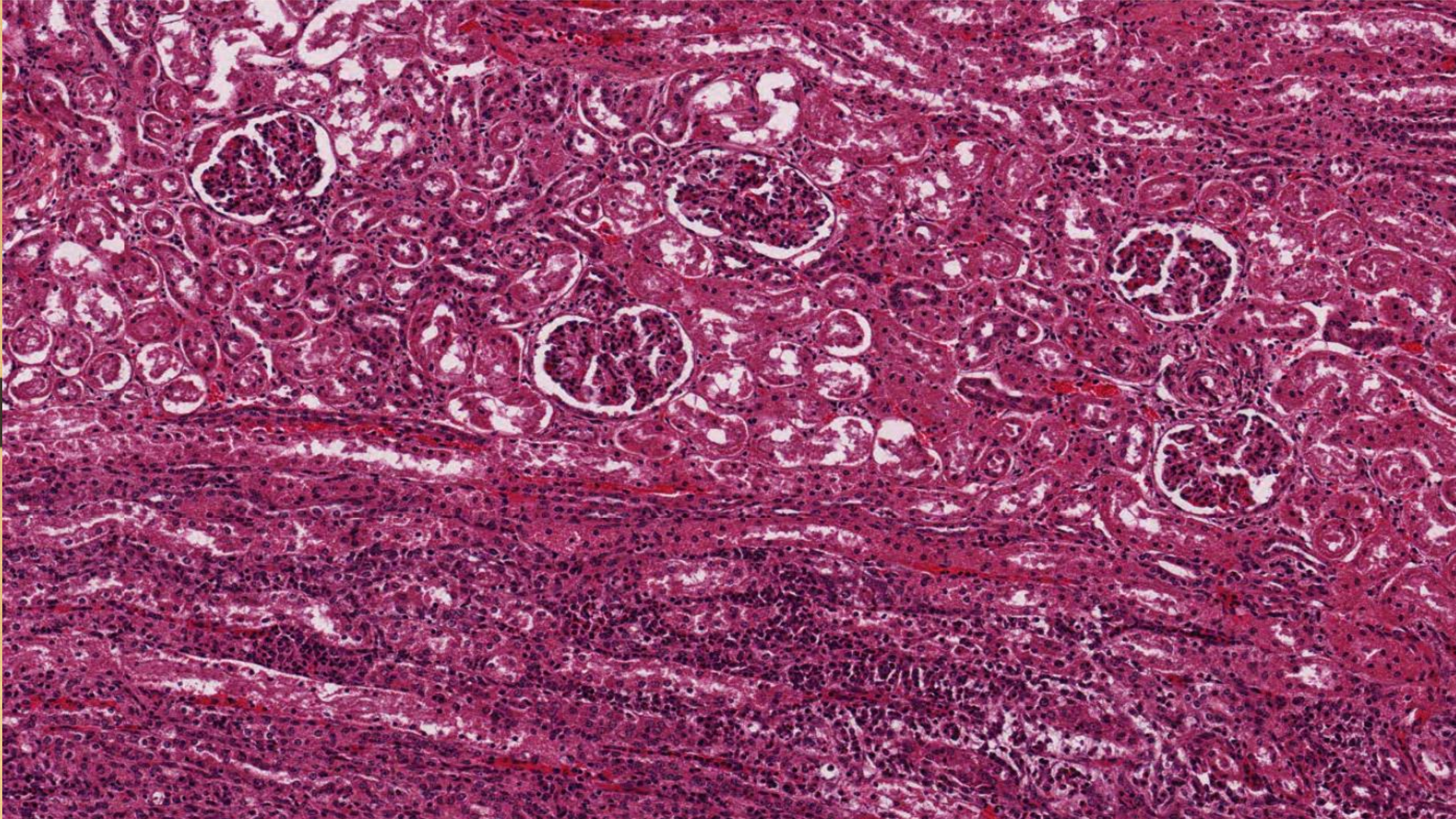
Assist. Lecturer Atheer Nabeel

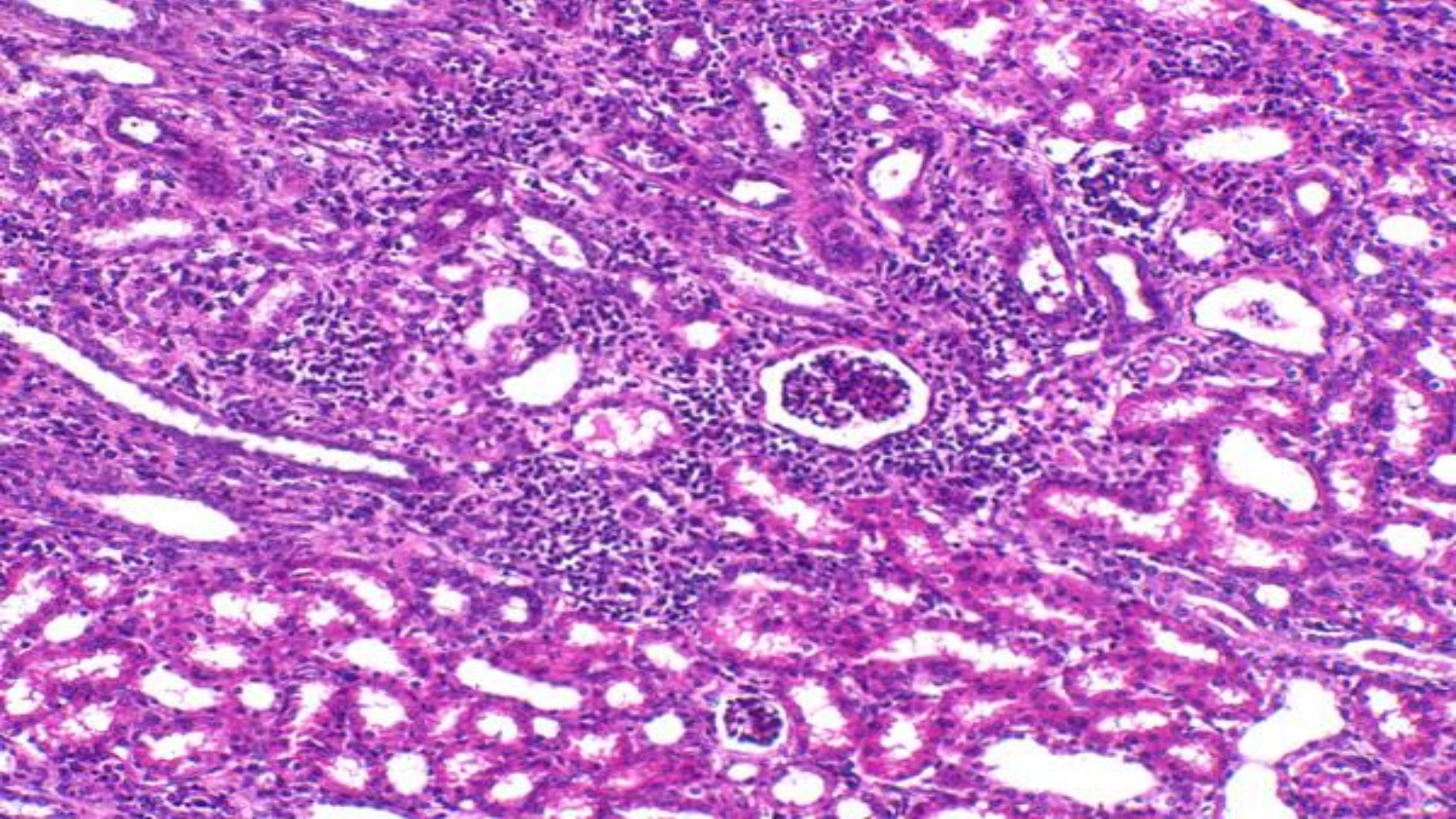
Diagnosis: Focal interstitial nephritis

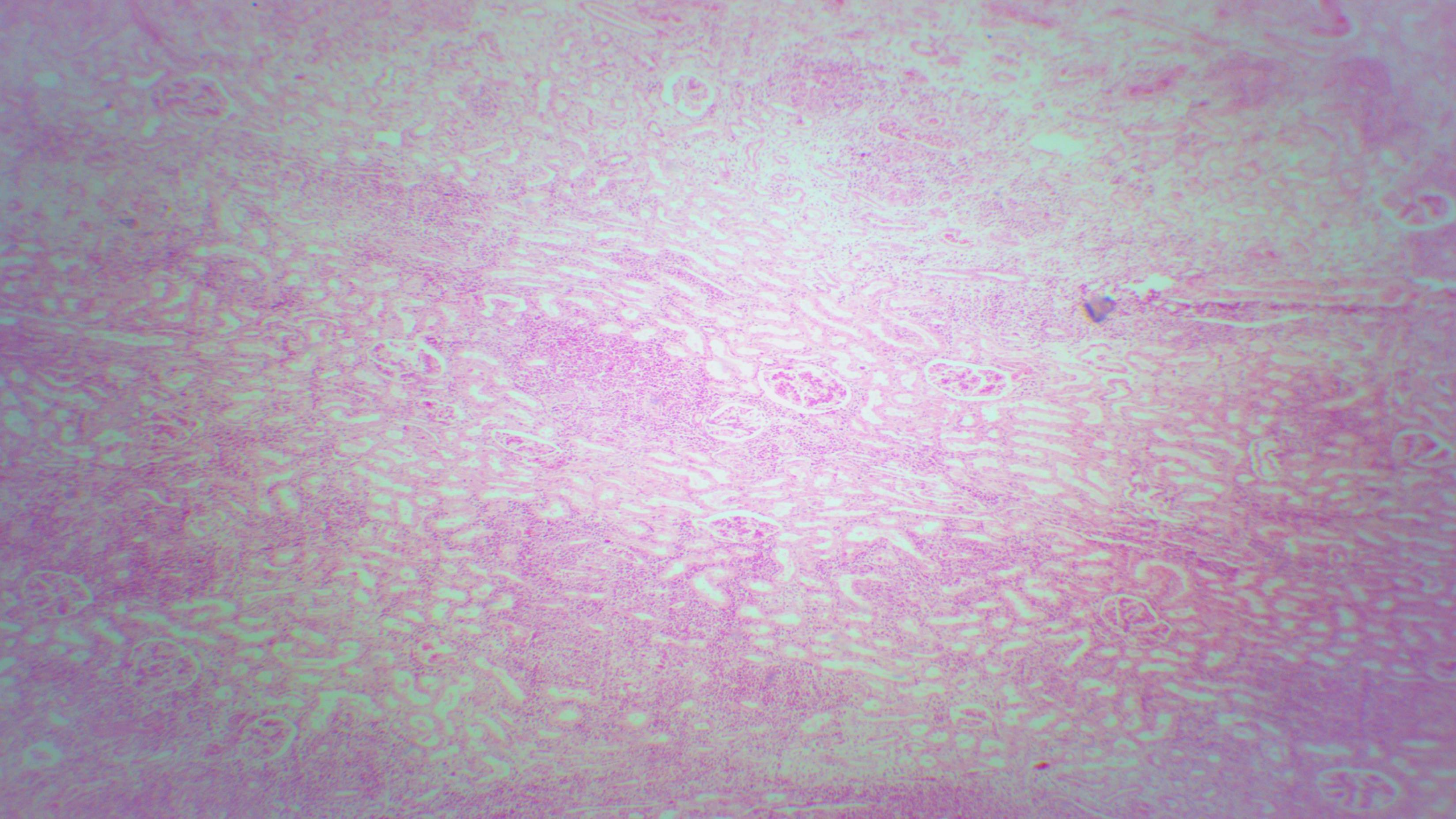
Organ: Kidney

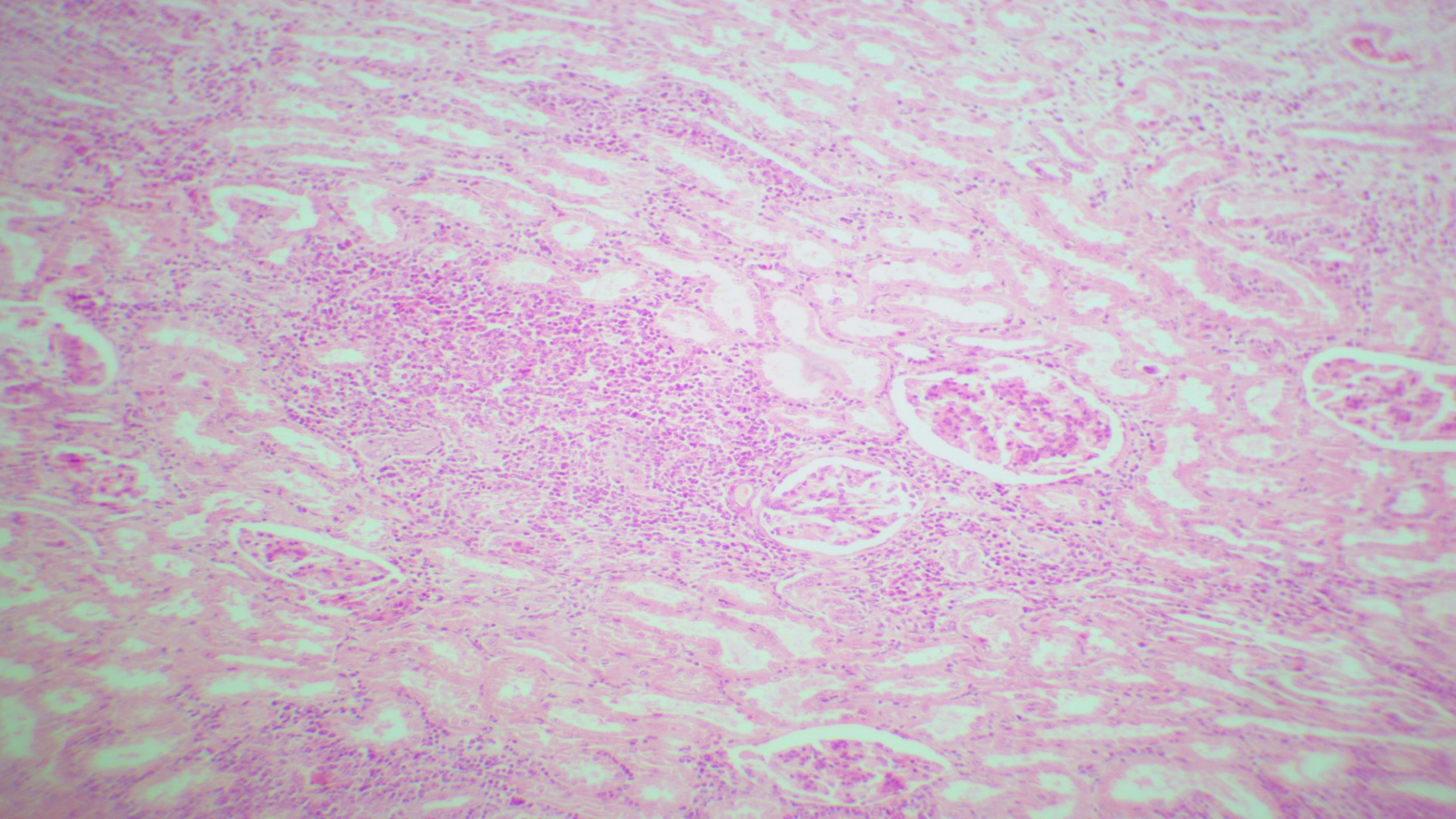
Lesion:

1. Presence of inflammatory foci represent the aggregation of lymphocytes in the cortex in addition to the dilation of renal tubules .
2. These aggregations are under the cortex and it is known as white spotted kidney attributed to its grossly appearance .







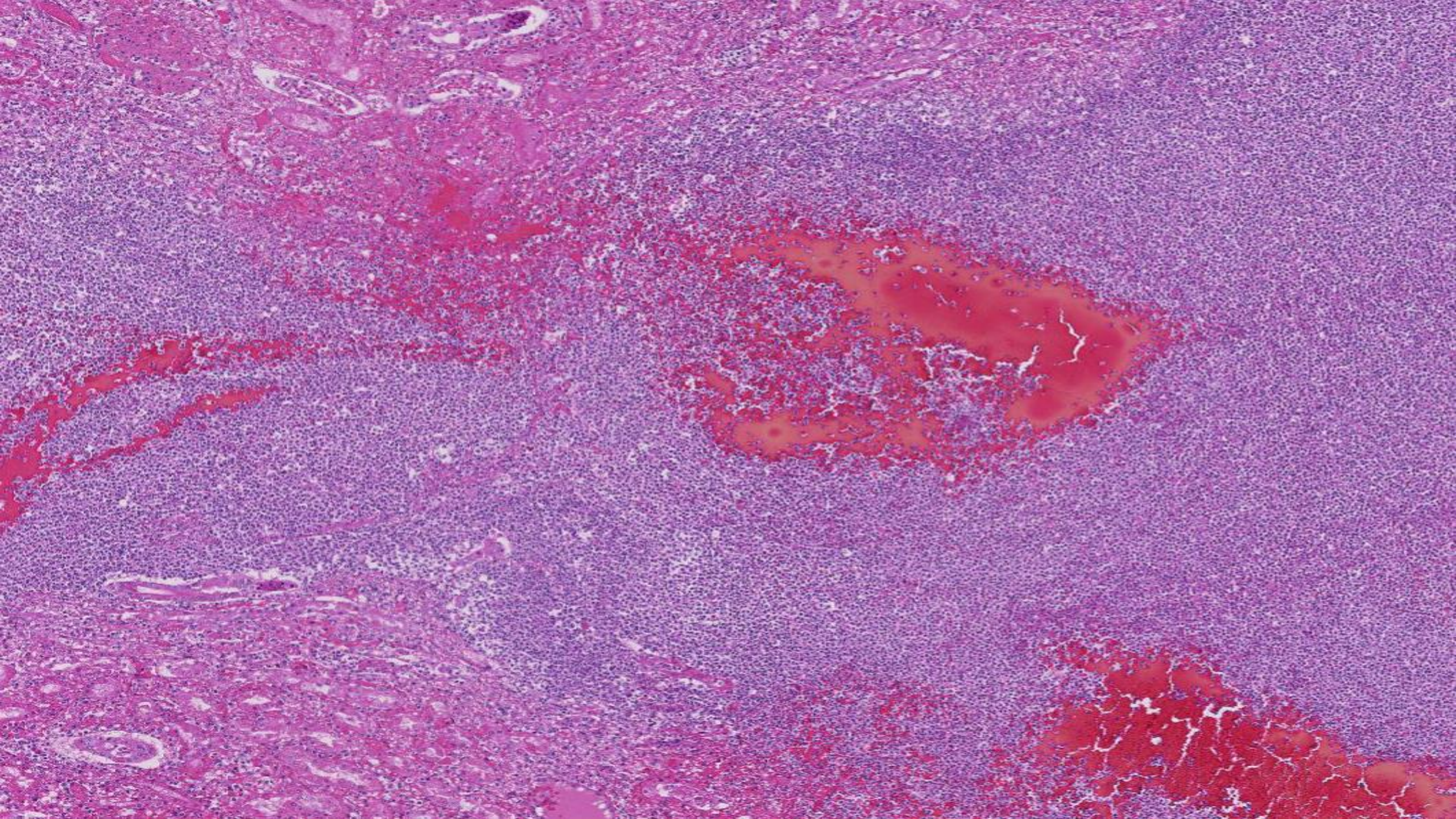


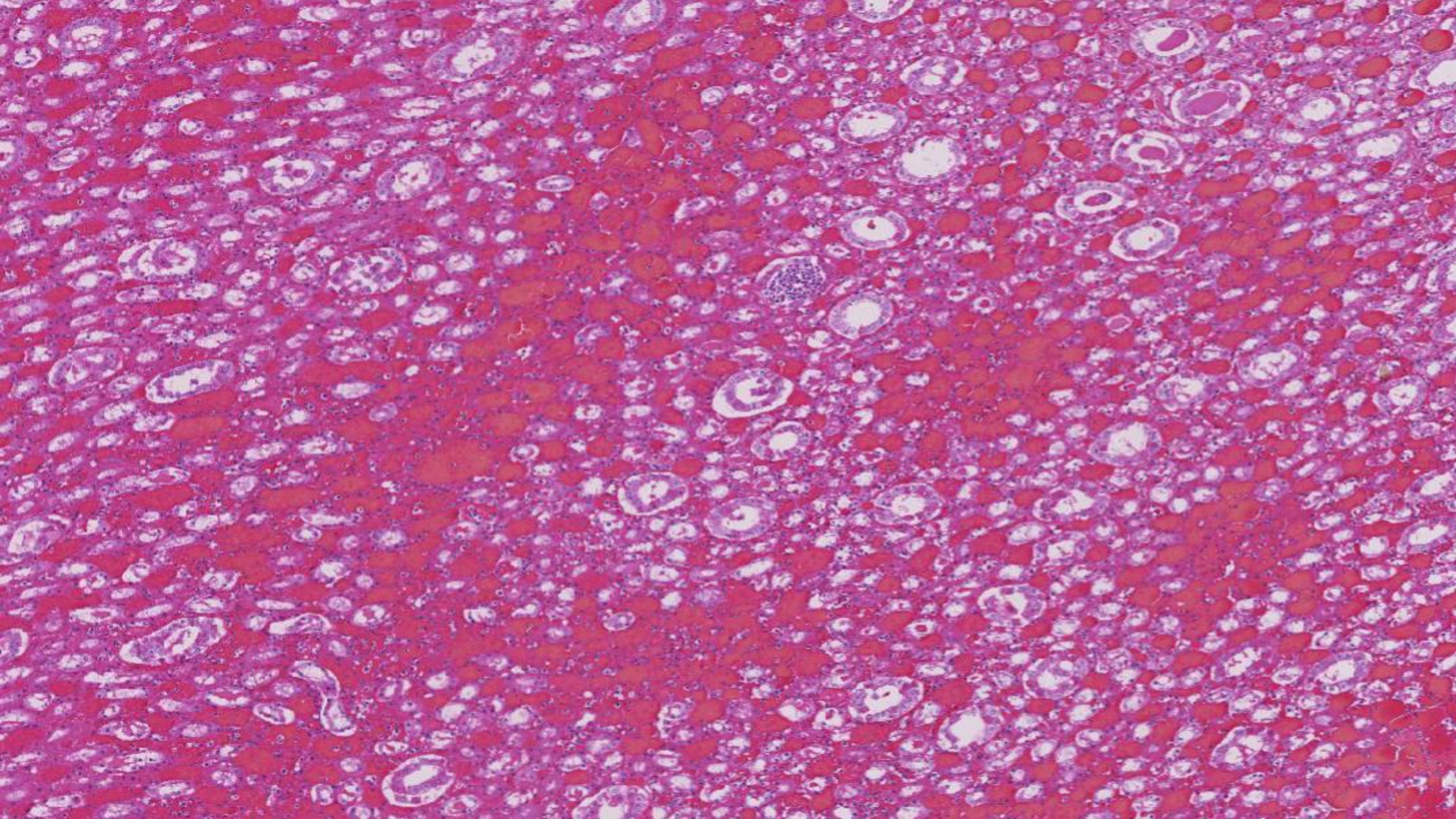
Diagnosis: Embolic Suppurative Nephritis

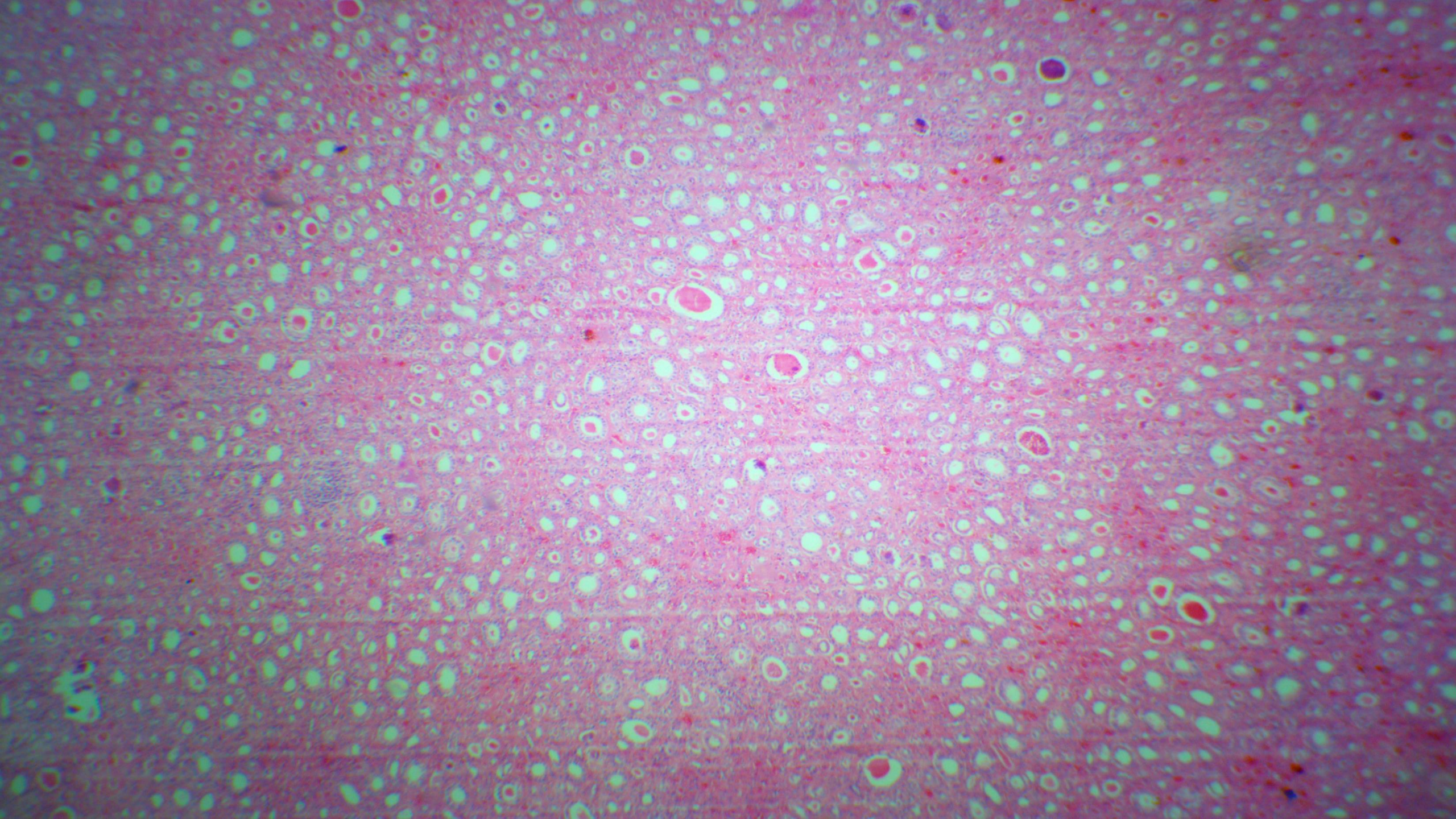
Organ: Kidney

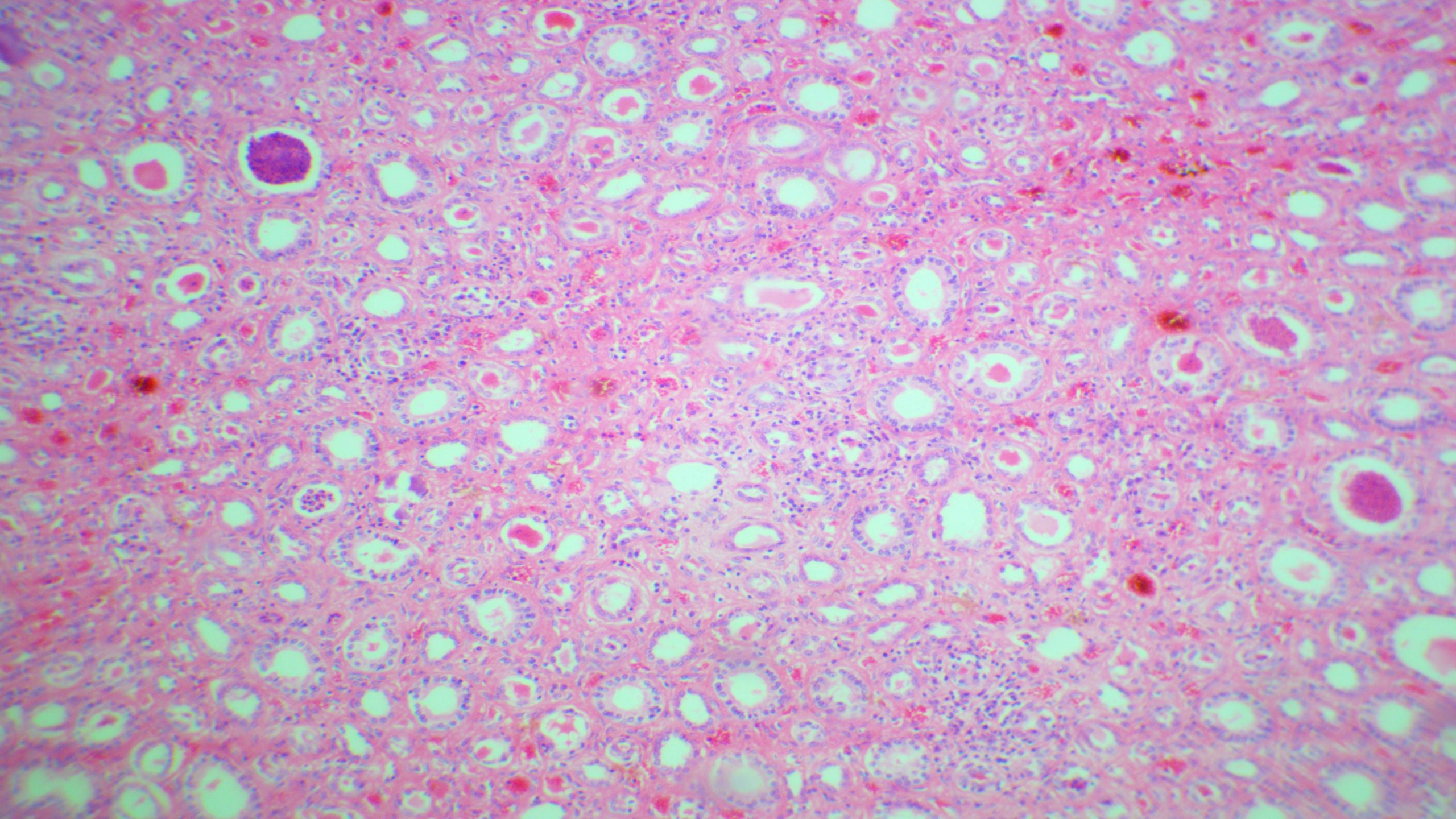
Lesion:

- 1. Suppurative inflammation in renal tubules especially near the renal glomeruli**
- 2. Large numbers of inflammatory cells around the pus in the interstitial tissue forming the line of demarcation**









Diagnosis: Cystic kidney

Organ: Kidney

Lesion:

1. Presence of cysts in the renal tissue (polycystic kidney).
2. The wall of cyst is lined by flattened epithelium.
3. Presence of hyaline casts in the form of pink masses in the lumen of tubules.
4. Infiltration of inflammatory cells in the wall of cysts in the renal tissue.

