



Lecture title: Reproductive system

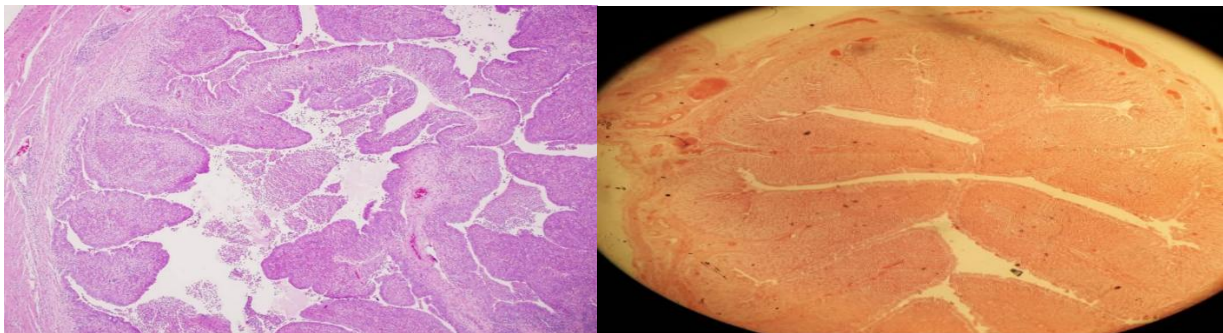
**Lecturer Affiliation: University of Mosul / College of Veterinary Medicine /
Department of Pathology and Poultry Diseases/
Assistant lecturer Atheer Nabeel Taha**

Diagnosis: Acute salpingitis

Organ: Salpinx

Lesion:

1. Stenosis in the lumen of the oviduct due to thickening in the wall as result of infiltration of polymorphonuclear inflammatory cells.
2. Congestion of blood vessels in the wall of oviduct.





Diagnosis: Chronic orchitis

Organ: Testis

Lesion:

- 1. Degeneration and necrosis of epithelial cells lining the seminiferous tubules surrounded by mononuclear inflammatory cells and surrounded by capsule of fibrous tissue.**
- 2. Disappearance of some seminiferous tubules which replaced by fibrous tissue.**

